

## **MANAGEMENT OF SCROTAL HERNIA IN 6 AND 9 MONTHS OLD OUDAH RAMS**

### **A CASE REPORT**

#### **ABSTRACT**

**Aims:** To describe the scrotal hernia in 6 and 9 months old rams and their management. **Case presentation:** A 6 and 9 months old oudah rams were presented to the large animal unit of the Veterinary Teaching Hospital (VTH), Usmanu Danfodiyo University Sokoto, with the complaint of testicular swelling. The cause of swelling was not certain but one of the rams (9 months old) was initially taken to “non-veterinarian”. Attempt to correct the hernia by the non-veterinarian failed. The animal was then presented to the hospital. Scrotal hernia was diagnosed on examination and herniorrhaphy was carried out to correct the defect. The animals were hospitalized for postsurgical care management and daily assessment revealed progressive healing of the surgical site until sutures were removed. Animals were discharged 10 days after the surgery and no evidence of recurrence.

**Conclusion:** This article presents the successful surgical management of scrotal hernia in 6 and 9 months old oudah rams

**KEY WORDS:** oudah rams, inguinal hernia, Herniorrhaphy.

#### **1. INTRODUCTION**

Scrotal hernia forms as an extension of inguinal hernia, when the abdominal organs protrude through an enlarged inguinal ring into the scrotum [1]. It is a rare disorder in small ruminants [2].

Scrotal hernia can be acquired, by a trauma such as a horn injury. It can also be congenital; two congenital scrotal hernias in lambs were reported at necropsy [3]. Most experts agree that an enlarged inguinal ring in early age is a hereditary in nature [4]. The heritability of scrotal hernia is however not yet fully understood [5]. But inbreeding may genetically predispose the animal to the development of scrotal hernia [6]. Affected rams should not be used for breeding [4].

Surgical repair of scrotal hernia can provide desired result, with good and uncomplicated healing [1]. In order to preserve the reproductive function of the unaffected testicle, [7, 1], as well as for the prevention of reherniation or seroma formation unilateral orchiectomy of an affected testicle is recommended. However, an affected testicle was successfully restored after the surgical repair of a scrotal hernia without orchiectomy in one male lamb [5].

#### **CASE PRESENTATION AND MANAGEMENT**

##### **2.**

In the present report, 2 rams, a 6 months-old and 9 months-old oudah ram were presented to the veterinary teaching hospital clinic Sokoto with the complaint of testicular swelling which was observed few months after purchase (Fig. 1A and 1B). An attempt to reduce the hernia one of the patients was made by “a non-veterinarian” few weeks prior to presenting the patient to the hospital. After thorough physical examination, scrotal hernia was diagnosed on both animals and surgery was scheduled the following day.

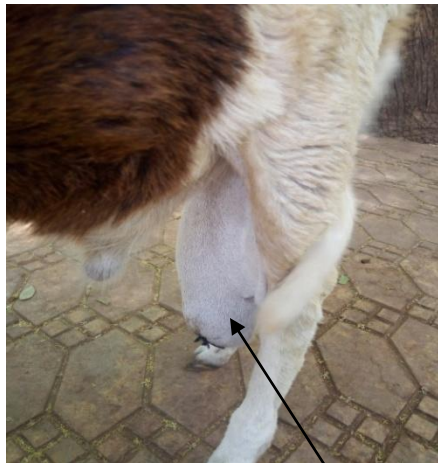


Figure 1a. swollen right testicle ( animal A)

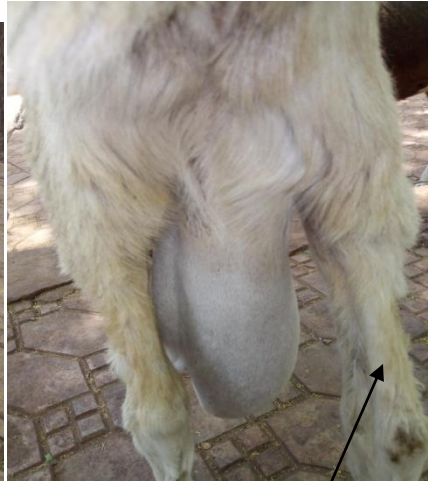

Figure 2a Swollen right testicle ( animal B)

The animal was assessed, evaluated and feed was withdrawn for 6 hours. The patient was prepared aseptically for the surgery. The hair was clipped, scrubbing of the surgical site was done using 4% Chlorhexidine gluconate (Savlon®, Vervaadingdeur, Johnson and Johnson (pty) Ltd, London), followed by spirit (Rico Pharmaceutical IND. (Nig.) LTD. 26 Newfia street Omagba phase II layout Onitsha Nigeria) and then povidon iodine (APACCO Pharmaceutical Nig. LTD Ogun state Nigeria). The anesthesia was achieved with 2% ligocaine (Debocaine® ALDebeiky pharmaceutical industries Co.) using ring block technique and aseptically prepared (fig. 2A, 2B, 3A and 3B).

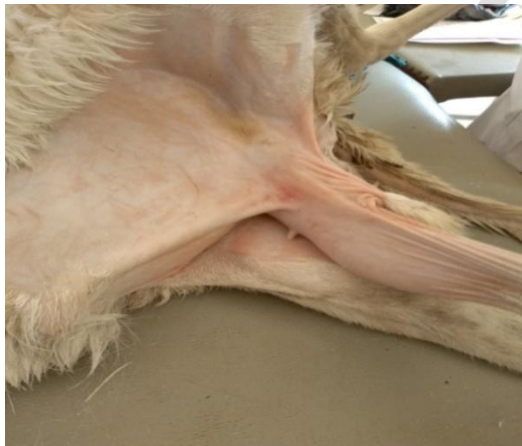

Figure 2A Surgical site preparation (animal A)

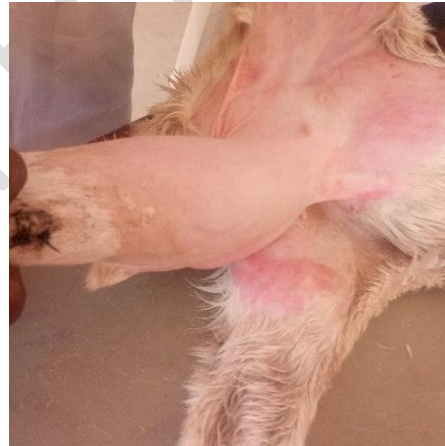

Figure 2B Surgical site preparation (animal B)

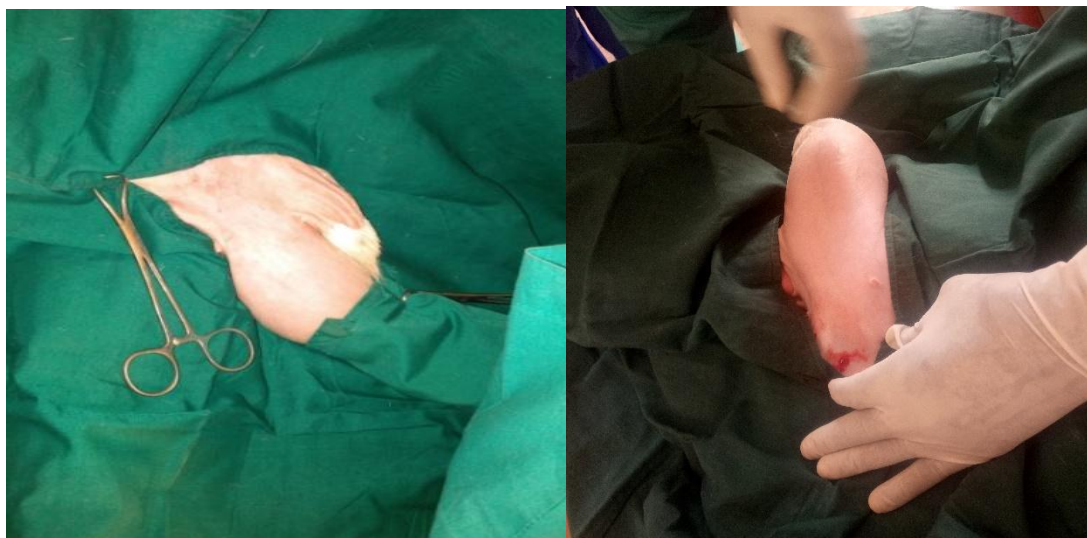

Figure 3A Draped surgical site, animal A Figure 3B Draped surgical site, animal B

The surgical technique as described by Gilbert and Fubini (2004) was used for the surgical repair of the scrotal hernia in the ram. Skin incision was made on the hernia mass, contents (intestines) were exposed, and adhesion was detached and eventually reduced into the abdominal cavity through the inguinal canal. Unilateral orchidectomy was performed and the ring was closed with nylon suture using simple continuous suture pattern. (Fig. 4 and 5).

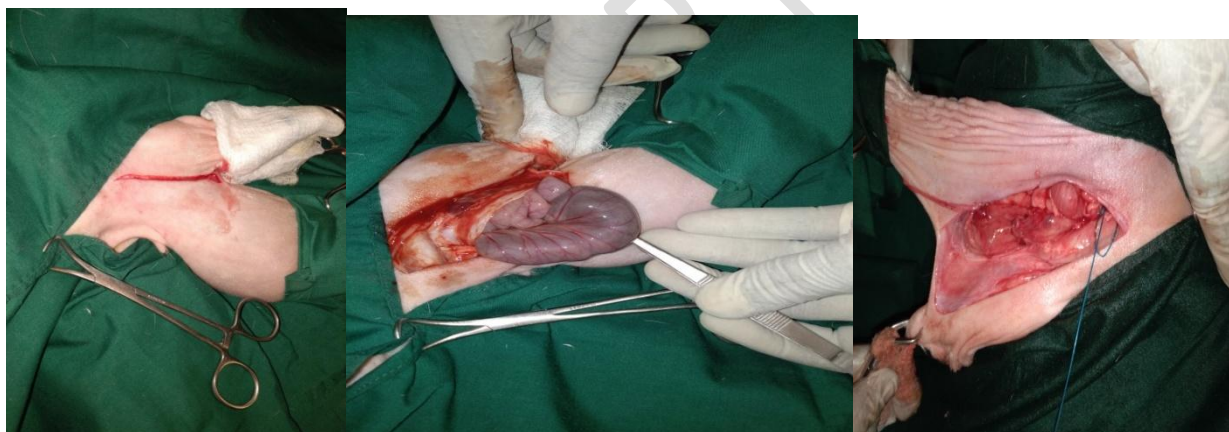


Fig. 4A. Skin incision (animal A). Fig. 4B. Hernial content (animal A)

Fig. 4C. Closure of the hernial ring

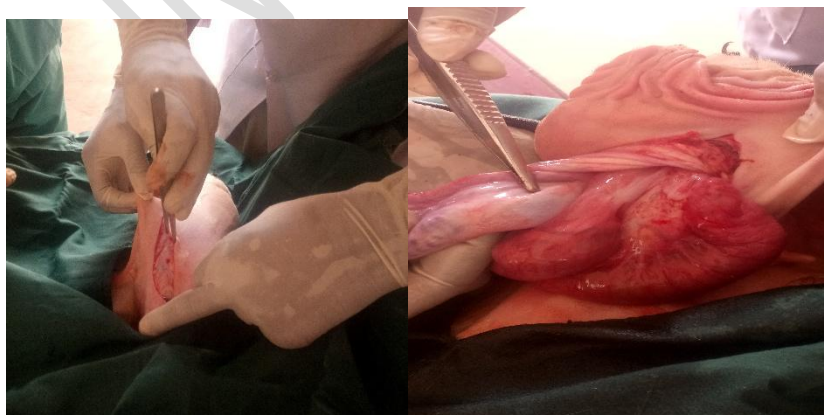



Fig. 5A. Skin incision (animal B)

Fig. 5B. Skin incision (animal B)

For cosmetic purposes and to avoid hernia recurrence and seroma formation, scrotal ablation was performed. Muscle and subcutaneous layers were sutured with simple continuous sutures using chromic catgut (Huaiyin Medical Instrument Co. Ltd, Jiangsu Province, China) size 0. The skin was closed with ford interlocking suture pattern using non-absorbable suture material as recommended by other authors[8].

)  
, monofilament nylon (Suzhou Acmed Import & Export Co., Ld, 436 Changjiang Road, Suzhou China) size 1. The patient was hospitalized and monitored for 12 days post surgery and was assessed to be in good condition.(Fig. 6).

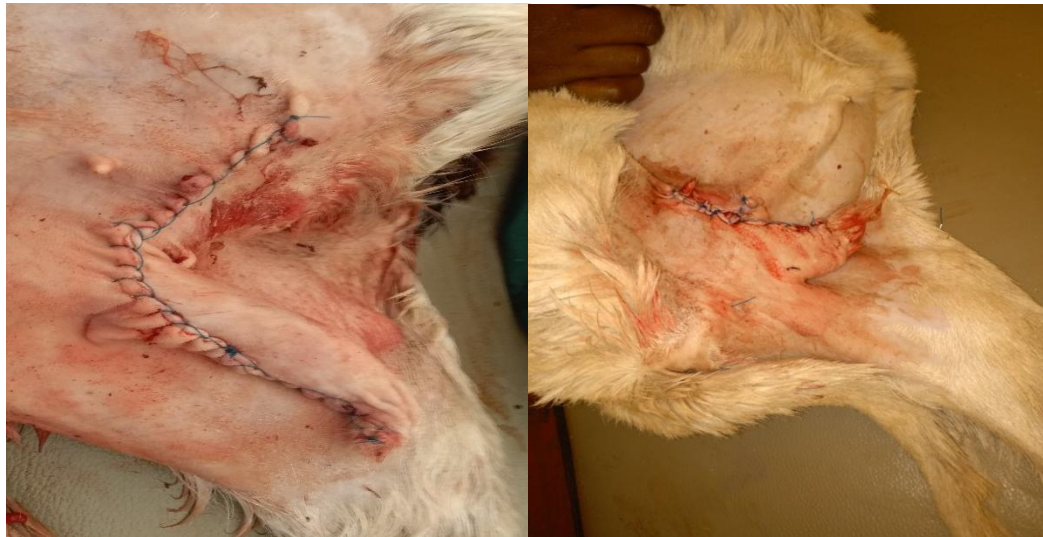

Fig. 6A. Skin closure (animal A) Fig. 6B Skin closure (animal B)

During postoperative follow up, penstrep® (De Santos pharm CO. LTD. Anambara state Nigeria) was administered intramuscularly for five days against the possible secondary bacterial infection.

Analgesia was achieved using diclofenac sodium (North China pharm. CO. LTD. Shijiazhuang China) at the dose rate of 10mg/kg for three days. Multivitamins (Jubaili Agrotec, Saida-Lebanon) at 1ml/kg was administered intramuscularly for five days to enhance healing and boost appetite. The sutures were removed on the 11<sup>th</sup> day (Fig. 2) and animals were discharged (fig. 7) .

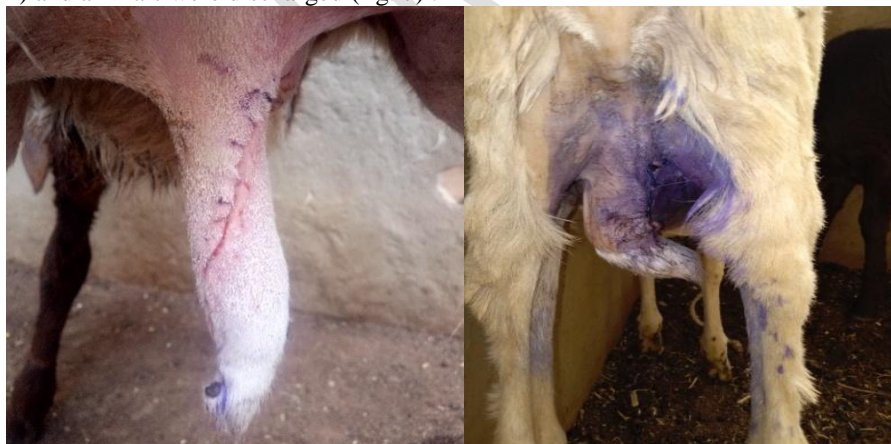

Fig. 9A. Patients after full recovery (animal A)

Fig. 7. Patients after full recovery (animal)

### 3. DISCUSSION

Surgical correction of the case at hand has provided desired result without any complication. **The scrotal hernia can be repaired surgically by herniotomy and herniorrhaphy [9].**In order to prevent recurrence of the hernia, preserve

the reproductive function of the unaffected testicles as well as preventing seroma formation, a unilateral orchidectomy and herniotomy as recommended by other authors was recommended [1,7,9]). There was reported case of complications of inflammation after managing scrotal hernia without castration in lambs which necessitated castration two weeks postsurgery where as some cases had good healing without complications [1]

#### 4. CONCLUSION

In the present case, we reduced the hernia using herniorrhaphy technique. We also performed unilateral orchidectomy as well as scrotal ablation to prevent recurrence of hernia, seroma formation and to preserve the unaffected testicle. Postoperative medication was given using penstrep®, Diclofenac sodium, multivitamins and daily dressing of the wound was given for 5 days.

#### Ethical Approval:

As per international standard or university standard ethical approval has been collected and preserved by the authors.

#### REFERENCES

1. AL-SOBAYIL, F. A., A. F. AHMED. Surgical treatment for different forms of hernias in sheep and goats. J. Vet. Sci. 2007; (8) 185-191.
2. ROBERTS, S. J. Scrotal hernia in rams. A case report. Cornell Vet. (1988); (78) 351-352.
3. Dennis, S. M., H. W. Leipold. Congenital hernias in sheep. J. Am. Vet. Med. Ass. (1968); (152) 999-1003.
4. Smith, M. C. Scrotal hernia. <http://drostproject.vetmed.ufl.edu/ovine/11-2/itemtop6.html>. (2006)
5. Braun, W. F., W. J. Cole. Unilateral scrotal hernia in a ram lamb. J. Am. Vet. Med. Ass. (1985); 187, 500.
6. Carr, P. M. An apparently inherited inguinal hernia in a Merino ram. Aust. Vet. J. (1972); 48, 126-127.
7. Gilbert, R.O., S.L. Fubini. Surgical management of specific condition. In: Farm Animal Surgery. (Fubini, S. L., N. Ducharme, eds.). Saunders. St. Louis. (2004); 355-361.
8. Abdin-Bay, M. R., R. O. Ramadan. Retrospective study of hernia in goats, Scientific journal of King Faisal University, Basic and applied sciences, 2001; (8), 77-88.
9. Berislav Radisic, Darko Capac, Draken Maticic, Ivica Harapin, Josip Kos, Tomislav Babic and Gordana Nedeljkovic. Surgical treatment of a unilateral scrotal hernia in a ram, Vet. Archive, 2010; 80 (1) 145-154