

Orbital abscess drainage using intravenous cannula : technique and advantages

Rachid ZERROUK^{1,&}; Adil ELKHOYAALI¹; Wafae AKIOUD¹; Mehdi KHMAMOUCHE¹;

Fouad ELASRI¹; Karim REDA¹; Abdelbarre OUBAAZ¹

¹: Hospital militaire Mohamed V rabat; faculté de médecine et de pharmacie de rabat

&: corresponding author

ABSRTACT

The orbital infections are known to be the most frequent primitive orbital pathology. Rhinosinusitis (RS) is the most common cause of orbital inflammation and infection, especially in the pediatric range. So far, the main orbital complication of RS is the preseptal cellulitis. The dissemination of the infection in the orbital retroseptal area may occur and is considered to be a serious complication requiring urgent diagnosis and treatment. It is usually seen as an orbital (OSPA) subperiosteal abscess adjacent to the infected sinus. The diagnosis of an OSPA is based on clinical evaluation as well as X-ray imaging. The CT scan is the preferred imaging modality for orbital abscess diagnosis. In most cases of OSPA, the surgery is often indicated and can be conducted by an external method, transnasal endoscopy or a combined method. In this article, we describe the technique of external drainage using an intravenous cannula (case report of 10 patients) as well as the results obtained.

Introduction:

Orbital abscess and cellulitis are the main frequent complications of the paranasal sinus infections. In presence of an ethoimiditis, the infection disseminates throughout the thin bone wall separating the sinus and the orbit. (1)

Other, less common, causes are the dacryocystitis, orbital foreign objects, peri-ocular trauma, surgical medical history, a dental infection, endophtalmitis or the orbital tumors (2; 3; 4)

In most cases of OSPA, the surgery is often indicated and can be conducted by an external method, transnasal endoscopy or a combined method.

In this article, we describe the technique of external drainage using an intravenous cannula (case report of 10 patients) as well as the clinical and paraclinical features, and the prognosis of this method.

MATERIALS and METHODS :

In our article we report ten cases of orbital abscess patients who underwent a surgery at the ophthalmology department of The Mohammed V Military Medical Training Hospital in Rabat, between June 2017 and December 2018 (Fig 1) with the informed consent of the participants to our study .

The patients had a general, ophthalmological and an ear, nose and throat (ENT) examination.

All of our patients conducted a brain CT scan viewing in all three projections: axial, coronal, and sagittal.

They have also had an intravenous antibiotic therapy (amoxicillin-clavulinic acid, la gentamicin, associated to metronidazole if doubt on the presence of anaerobic germs, especially in well grown children) . This medical treatment was completed, when there has been no improvement, with an external drainage and suction of the collection using an intravenous cannula without leaving any drain.

the technique consists on :

- The detection of the abscess center using the CT scan and measurement of the distance separating the abscess from the orbital margin. (Arrow on Fig. 2).
- A general anesthesia giving the procedure is highly painful.
- Asepsis using the povidone iodine and putting in a sterile field.
- Inserting the cannula facing the abscess zone and being very close to the orbital margin. And thus without exceeding the measured distance on the CT scan (Fig. 3).
- Removing the metallic mandrel and leaving the plastic drain.
- Attaching the drain to a syringe.
- Suction of the orbital abscess. Sending a sample for bacteriology analysis.
- Removing the cannula.
- Compressive bandage.

The follow up was based on clinical criteria: orbital tumefaction, visual acuity, ocular motility and signs of neurological location.

Results

During the study we identified 10 cases of orbital abscess. The medium age was of 11 years old with a range of 5 to 40 y.o. We noted a male dominance with a gender ratio of 3.

As for medical history, three of our patients had history of allergies, four of rhinitis and two of sinusitis. We found an inflammatory exophthalmia with a huge palpebral edema , in the right side for 3 cases and left side for the remaining 7(Fig. 1) .As well as sinusitis as a main cause in all our patients.

The homolateral ophthalmoplegia as well as a diplopia was reported in 5 cases. The decreased visual acuity concerned 4 cases while the blindness was noted among 2 of them.

Shivers and fever was identified in two patients.

The CT scan confirmed the abscess and its location: medial (4 cases), supero-medial (2 cases), and inferior (1 case). The CT scan showed as well a sinus lift in all patients as well as a frontal osteitis in 1 case. An MRI was conducted for 3 patients specifying the limits of the infection.

The drainage was conducted for all 10 patients reducing the size of the exophthalmia for all our cases (Fig 4).

A second CT was performed 24 hours after the drainage showing a good evolution (Fig. 4)

The bacteriology analysis identified as germs: Streptococcus pneumoniae (2 cases), Staphylococcus aureus (2cases), Haemophilus influenzae (5 cases) and the anaerobics(1 case).

According to the antibiogram, an intravenous antibiotic therapy was conducted followed up by oral antibiotics after one week.

Discussion:

Orbital abscess and cellulitis are mainly seen among male patients especially children and teenagers of ages between 6 and 15 years old, as well as elders of ages between 60 and 70 y.o. [1; 2; 3; 4].

The seasonal variation is ascribable to the increase of the respiratory infection incidence during a certain period of the year, especially among kids [5].

Immunodepression states such as diabetes represent a classic factor boosting the infection [6]. Diabetes was spotted in one case among our patients.

The germs frequently cultivated among adults are Streptococcus pneumonia, and Staphylococcus aureus. For children, only anaerobic were isolated up until today, mainly Haemophilus influenzae; however, due to vaccination this rate was considerably decreased. As for elders the anaerobics ere also found.

The range of 9 to 14 y.o is known to be the transition phase where the microbe species modify. The multi-microbial infections were also frequently spotted, especially among elders [7 ; 8 ; 9 ; 10 ; 11 ; 12]. The same germs were also found in our series.

The clinical exam and the fast treatment are highly important in an orbital infection, because the slightest delay may be responsible for serious complications as the infection would spread along the optic canal, the optic nerve and the ophthalmic vein. This may cause the partial or total loss of vision; secondary to high intra orbital pressure caused by the collection of the pus, leading to an infraction of the optic nerve, a retinal ischemia due to the central artery occlusion, or a thrombophlebitis along the orbital veins.

The vision loss may also occur due to the optic neuritis as the infection spreads. Other cerebral complications may arise such as cavernous sinus thrombosis, meningitides, cerebral abscess, osteomyelitis, superior orbital fissure syndrome, orbital apex syndrome, peridural empyoma, encephalitis or even death [13].

Despite the severity of the illness, none of our patients had a visual deficiency.

The CT scan is a very important mean to decide on the surgical drainage of the orbital collection. On the CT scan the abscess appears as a homogenous or heterogeneous image surrounded by an enhanced hyperdense shell , while the presence of a sinusal liquid-air level

indicate the sinus origins of this . The medial displacement of the interne rectus muscle as well as the displacement of the periosteum away from the papyraceous slide is other characteristics of the abscess, this helps making a precise evaluation of the intra orbital lesions as well as exploring the bone and sinus lesions, and searching for possible cerebral complications. [13; 14; 15; 16].

The main indication of MRI is when an intracranial infection is suspected. The MRI helps then identify the location and the size of the infection with a higher precision than the CT scan [17]

Most of the orbital infections are treated with a conservative therapy, especially for children less than 9 years old, while the surgical drainage is usually needed for elders [8 ; 17].

For retroseptal orbital cellulitis: the treatment requires a hospitalization and the administration of an intravenous bi-antibiotherapy. Broad spectrum antibiotics covering the aerobic and anaerobic are recommended. Combining a 3rd generation cephalosporin and a fosfomycin (100 à 200 mg/kg/day) is an interesting example. For adults allergic to B-lactamin, the use of fluoroquinolone is more appropriate. When the presence of anaerobic germs is suspected, the metronidazol or the clindamicin should always be added to the treatment especially for children and adults. [18]

Subperiostal abscess could be treated with mere antibiotics especially for children [12,19], if the infection's thickness is below 10 mm without any mass effect on the intern rectus muscle and in absence of any air bubbles suggesting the presence of anaerobics [12 ;20]

The success rate is estimated at 93 % [21; 22; 19]

Some suggest the use of intravenous steroids for few days after an efficient antibiotic administration. [23].

In all cases especially in presence of seriousness criteria, an urgent surgical drainage is required when: [8, 24, 25]

- There is a visual risk with the optic nerve or retinal damage, at any age.
- There is a collected or extensive subperiostal
- There is an intracranial complication especially in frontal.
- There are multiple sites with anaerobic germs infection such as dental infections or chronic sinusitis in which it is important to maintain a good ventilation of the sinus.

Before the age of 9 and in absence of these criteria, a close monitoring is required, with a differed surgical intervention in case of an afferent papillary defect, the non clinical amelioration or deterioration after 48 to 72 hours of biotherapy.

The surgical drainage, guided by the clinical and imaging data should concern the orbital abscess, by orbitotomy or an endonasal intervention as well as all infected sinusitis.

It consists usually of an anterior orbitotomy, then eventually after the abscess puncture, of an open-draining of the collection. In case of an intern or inferior medial subperiostal abscess the endonasal intervention may be conducted.

A blade of Silastic® or Florence drain may be left in place locally for about 24 to 48 hours.

The abscess evacuation can also be performed by an endonasal method after collapsing the papyraceous slide. [26; 27]

In our series, the surgical indications are sometimes difficult to determine. Our surgeons have chosen to follow the classical criteria such as the loss of vision, diplopia with a motility defect, absence of improvement of visual signs after 48h intravenous therapy.

The advantages of our technique are: the fast abscess drainage, the short procedure (15min), not leaving a drain after the surgery, absence of scars, making a bacteriology sampling that can guide the biotherapy.

The limits of this technique are the limited number of patients and the absence of a simultaneous surgical treatment of the sinus location when indicated.

Well treated, the orbital abscess prognosis is favorable [28] ; 5 of our patients have recovered without any aftereffects and regained a total visual acuity and a complete ocular motility; **exophthalmia** have disappeared with a progressive melt of the intra orbital. The classic **aftereffect** of this disease is blindness found in **two** of our patients. Blindness is related to a delay in take over explained by our patient's social context. [28]

Conclusion:

A fast treatment is required to avoid the visual loss as well as the intracranial complications. As a first step, intravenous antibiotics may be given, however in case of non amelioration ,within 48hours, a surgical drainage of the affected sinus is required ; thus, this technique of drainage using a cannula is fast , practical and gives new therapeutic perspectives

Disclaimer regarding Consent/Ethical Approval:

As per international standard guideline participant consent and ethical approval has been collected and preserved by the authors.

References

(1) E.vairaktaris, M. moschos, S.vassilou, S. baltazis, E.kalimeras, D.avgoustidis, Z. pappas, M N. moschos *Orbital cellulitis, orbital subperiosteal and intraorbital abscess. Report of three cases and review of the literature Journal of Cranio-Maxillofacial Surgery (2009) 37, 132e136*

(2) Hershey BL, Roth TC. *Orbital infections. Semin Ultrasound CT MR 1997;18:448-59.*

(3) Rumelt S, Rubin PA. *Potential sources for orbital cellulitis. Int Ophthalmol Clin 1996;36:207-21.*

(4) Palamar M, Uretmen O, Kose S. *Orbital cellulitis after strabismus surgery. J AAPOS 2005;9:602-3.*

(5) *Infections orbitaires F. Mouriaux, B. Rysanek, V. Cattoir, E. Babin EMC 21-650-A-15*

- (6) [Mandava P, Chaljub G, Patterson K, Hollingsworth JW. MR imaging of cavernous sinus invasion by mucormycosis: a case Study. *Clin Neurol Neurosurg* 2001;103:101—4.
- (7) Ferguson MP, McNab AA: Current treatment and outcome in orbital cellulitis. *Aust N Z J Ophthalmol* 27: 375e379, 1999
- (8) Harris GJ: Subperiosteal abscess of the orbit: older children and adults require aggressive treatment. *Ophthal Plast Reconstr Surg* 17: 395e397, 2001
- (9) Ikeda K, Oshima T, Suzuki H, Kikuchi T, Suzuki M, Kobayashi T: Surgical treatment of subperiosteal abscess of the orbit: Sendai's ten-year experience. *Auris Nasus Larynx* 30: 259e262, 2003
- (10) McKinley SH, Yen MT, Miller AM, Yen KG: Microbiology of pediatric orbital cellulitis. *Am J Ophthalmol* 144: 497e501, 2007
- (11) Nageswaran S, Woods CR, Benjamin DK, Givner LB, Shetty AK: Orbital cellulitis in children. *Pediatr Infect Dis J* 25: 695e699, 2006
- (12) Oxford LE, McClay J: Medical and surgical management of subperiosteal orbital abscess secondary to acute sinusitis in children. *Int J Pediatr Otorhinolaryngol* 70: 1853e1861, 2006
- (13) Chaudhry IA, Shamsi FA, Elzaridi E, Al-Rashed W, Al-Amri A, Al- Anezi F, Arat YO: Outcome of treated orbital cellulitis in a tertiary eye care center in the middle East. *Ophthalmology* 114: 345e354, 2007
- (14) Herrmann WB, Forsen Jr WJ. Simultaneous intracranial and orbital complications of acute rhino sinusitis in children. *Intern J of Ped Otorhinolaryngology*. 2004 May;68(5):619-25. *PubMed | Google Scholar*
- (15) Starkey CR, Steele W R. Medical management of orbital cellulitis. *The pediatric infectious disease Journal*. 2001; 20(10):1002-1005. *PubMed | Google Scholar*
- (16) Watkins ML, Pasternack SM, Banks M, Kousoubris P, Rubin ADP. Bilateral cavernous sinus thromboses and intraorbital abscesses secondary to *Streptococcus milleri*. *Ophthalmology* .2003; 110 (3): 569-574. *PubMed | Google Scholar*
- (17) Younis RT, Anand VK, Davidson B: The role of computed tomography and magnetic resonance imaging in patients with sinusitis with complications. *Laryngoscope* 112: 224e229, 2002 .
- (18) Schwartz G. Etiology, diagnosis, and treatment of orbital infections. *Curr Infect Dis Rep* 2002;4:201-5.
- (19) Rubin SE, Rubin LG, Zito J, Goldstein MN, Eng C. Medical management of orbital subperiosteal abscess in children. *J Pediatr Ophthalmol Strabismus* 1989;26:21—7.
- (20) Ryan JT, Preciado DA, Bauman N, Pena M, Bose S, Zalzal GH, et al. Management of pediatric

orbital cellulitis in patients with radiographic findings of subperiosteal abscess. Otolaryngol Head Neck Surg 2009; 140:907-11.

(21) Catalano RA, Smoot CN. Subperiosteal orbital masses in children with orbital cellulitis: time for a reevaluation? J Pediatr Ophthalmol Strabismus 1990;27:141-2.

[22] Garcia GH, Harris GJ. Criteria for nonsurgical management of subperiosteal abscess of the orbit: analysis of outcomes 1988-1998. Ophthalmology 2000;107:1454-6 (discussion 7-8).

(23) Triglia JN. Les sinusites et leurs complications. Paris: Flammarion; 2006.

(24) Harris GJ. Subperiosteal abscess of the orbit. Age as a factor in the bacteriology and response to treatment. Ophthalmology 1994;101:585—95.

(25) Greenberg MF, Pollard ZF. Medical treatment of pediatric subperiosteal orbital abscess secondary to sinusitis. J AAPOS 1998;2:351—5.

(26) Froehlich P, Pransky SM, Fontaine P, Stearns G, Morgon A. Minimal endoscopic approach to subperiosteal orbital abscess. Arch Otolaryngol Head Neck Surg 1997;123:280-2.

(27) Bhargava D, Sankhla D, Ganesan A, Chand P. Endoscopic sinus surgery for orbital subperiosteal abscess secondary to sinusitis. Rhinology 2001;39:151-5.

(28) Kabré Abel , Diallo Ousseini, Cissé Rabiou. Abscès intra orbitaires : à propos de deux cas. African Journal of Neurological Sciences AJNS . 2008. Vol 27: No 1.

Figures :

FIG1 : Subperiosteal abscess of the right eye

Fig 2 : Orbital CT scan : subperiosteal abscess. (Arrow measuring the distance between the skin and the center of the abscess)

Fig 3 : Drainage of the abscess.

Fig 4 : Post drainage Aspect :

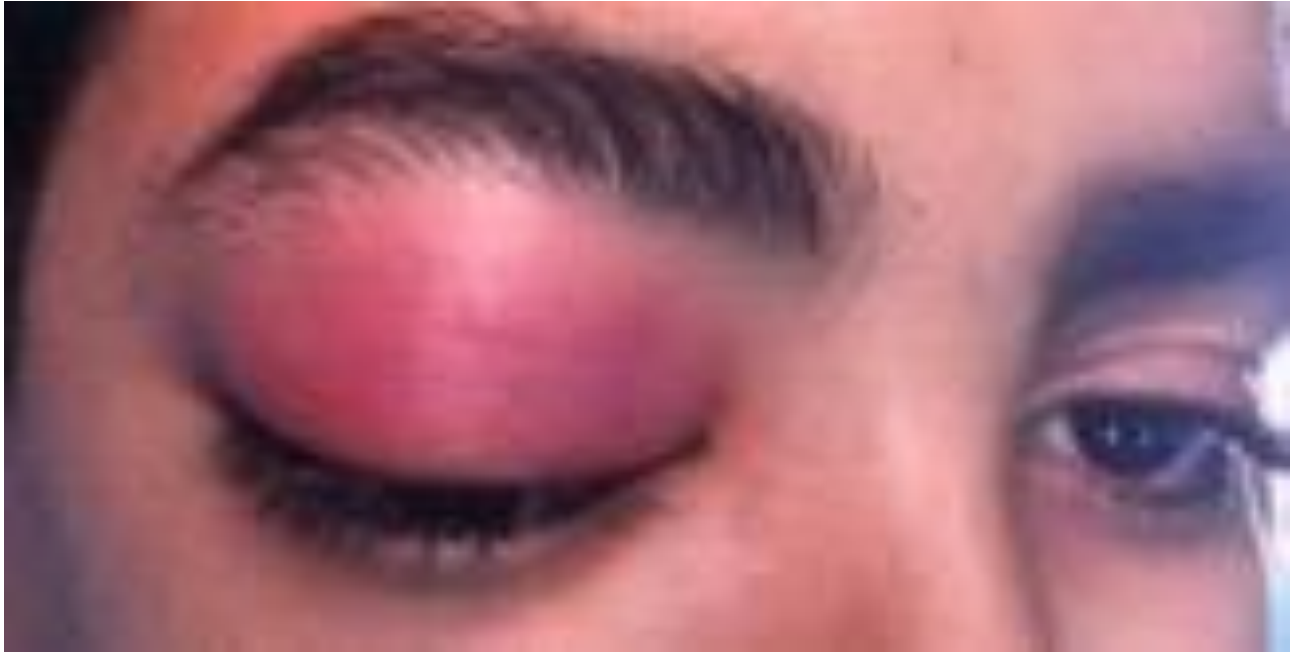

Figure: 1

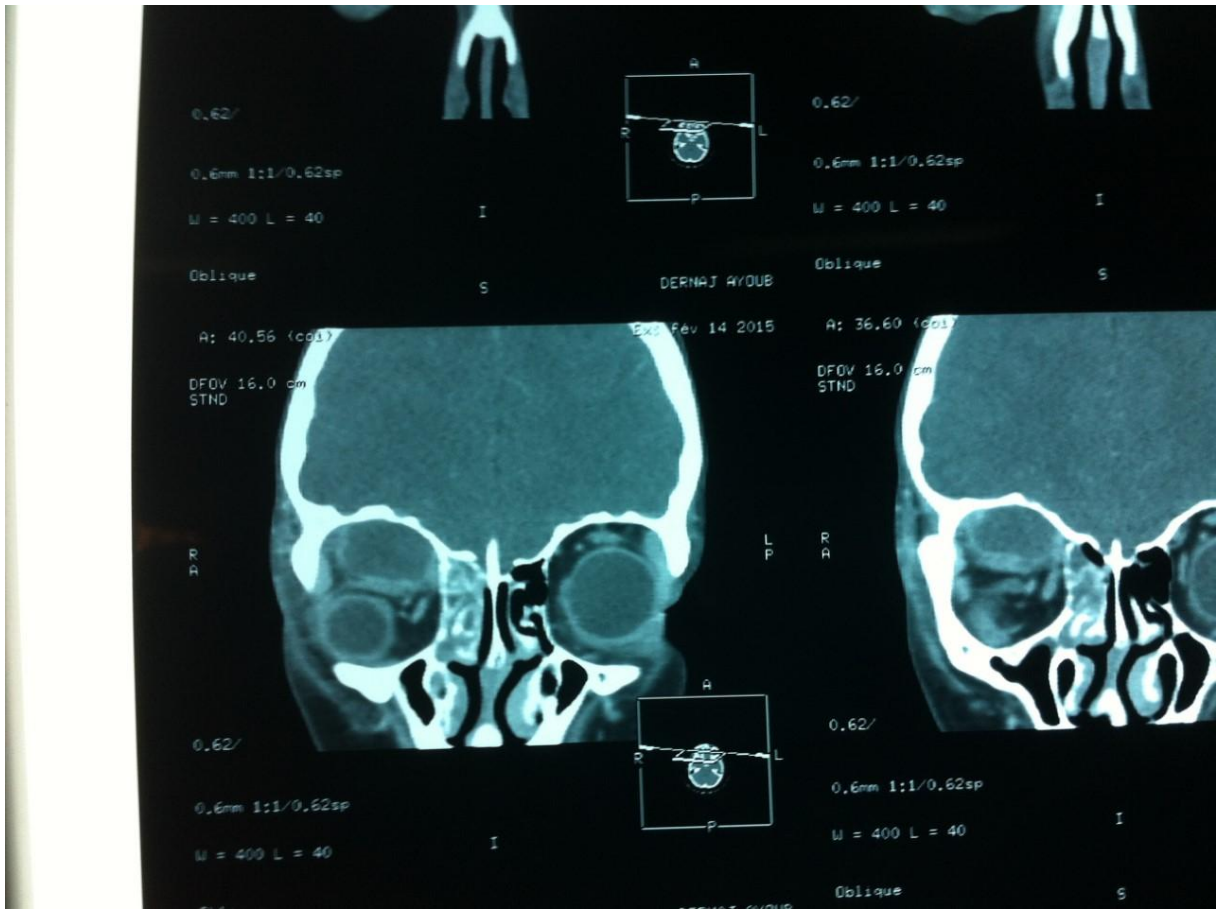


Figure : 2

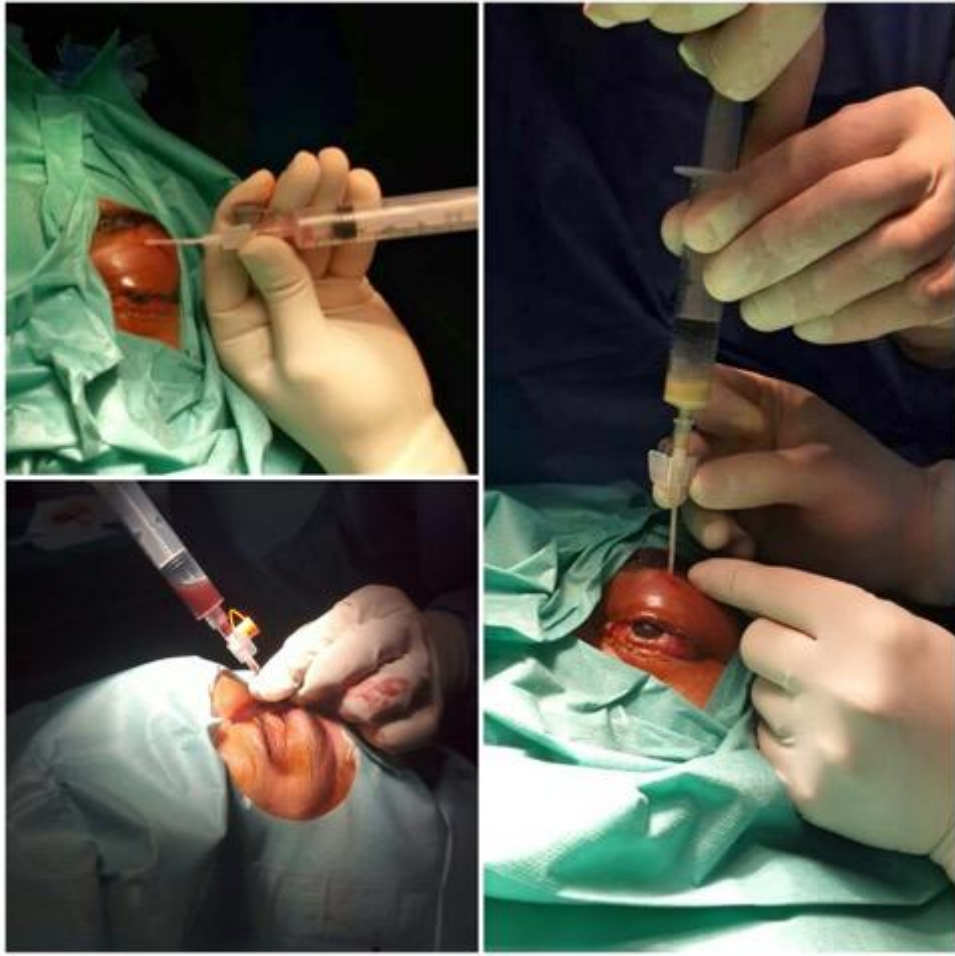

Figure : 3

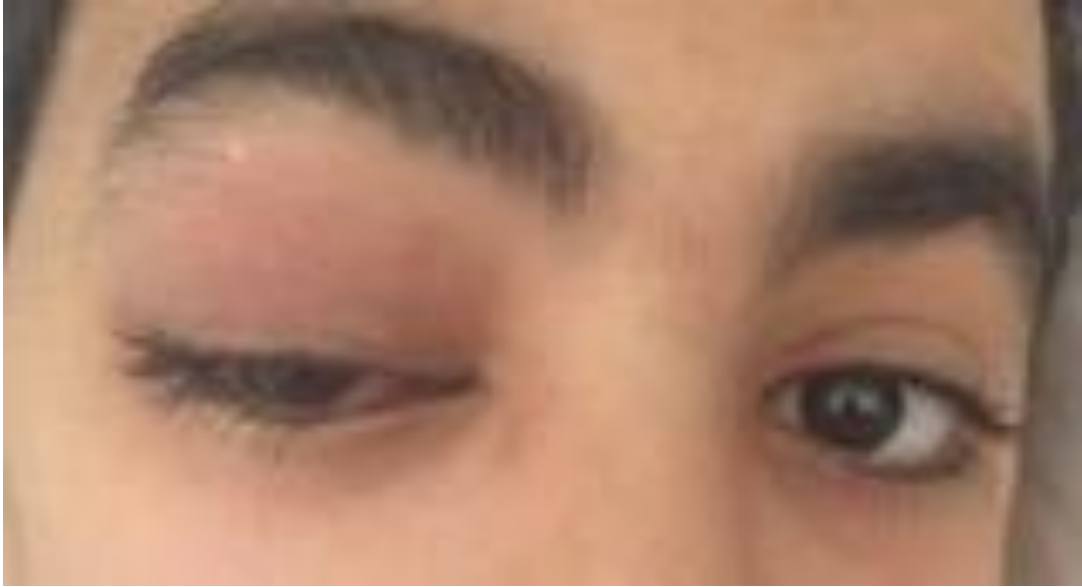

Figure : 4