

**Endophthalmitis : 5 years Experience in a tertiary eye care center Mohammed V Military Medical Training Hospital**

**Abstract :**

**Aims:** To describe endophthalmitis profile in a tertiary eye care center.

**Study design:** Retrospective study.

**Place and duration of study:** the ophthalmology department of The Mohammed V Military Medical Training Hospital in Rabat, and covering all patients hospitalized for endogenous and exogenous endophthalmitis between January the 1st 2014, and 31 of December 2018.

**Methodology:** We included 41 eyes from 41 patients with endophthalmitis.

**Results:** On a total of 41 eyes, mean age was 53,8 years, with a sex ratio of 1,7. mean time from onset of symptoms to presentation was 8 +/- 4 days (3 to 32) for postoperative endophthalmitis, and 13 +/- 9 days (2 – 30) for other causes. 98 % of patients presented decreased vision, and 88 % showed ocular pain. 94 % of patients had a visual acuity less than hand motion. Gram positive bacteria were isolated in 76 % of the patients.

**Conclusion:** Our epidemiological, clinical and microbial findings are similar to some occidental and other oriental series.

**Keywords :** Endophthalmitis, endogenous, exogenous, risk factors, microbial profile.

**Introduction :**

Endophthalmitis can be defined as an intraocular inflammation secondary to deep intraocular infection(1).

Endophthalmitis can be classified either by endogenous or exogenous(2). Endogenous endophthalmitis occurs when micro-organisms spread from an initial infected site through the blood-ocular barrier while exogenous endophthalmitis are secondary to micro-organism inoculation during penetrating trauma, corneal ulceration, following intraocular surgery or by contiguity(2).

In 1995, the Endophthalmitis vitrectomy study (EVS)(3) established the rules for the curative treatment of endophthalmitis.

10 years later, the European Society of Cataract and Refractive Surgeons (ESCRS)(4) study developed an innovative approach in term of antibiotic prophylaxis.

Since then, major progress has been made to isolate microorganisms responsible for endophthalmitis, especially in molecular biology(5), helping prescribing an adapted antibiotic therapy.

Given the severity of the condition, a quick diagnosis with an imminent treatment remain lawful and highly impact visual prognosis.

## **Material and methods :**

This is a retrospective study, conducted within the ophthalmology department of The Mohammed V Military Medical Training Hospital in Rabat, and covering all patients hospitalized for endophthalmitis between January the 1st 2014, and 31 of December 2018.

Inclusion criteria were the presence of anterior or posterior segment inflammation on biomicroscopic examination, vitritis, associated with clinical and historical elements strongly suggestive of endophthalmitis.

Data were collected from written folders, and included **demographics, risk factors**, clinical examination, paraclinical investigations, microbial profile, treatment modalities and evolution with final Best corrected visual acuity (BCVA).

Microbial analysis was based on systematic conjunctival and vitreous samples, with initial Gram-Staining microscopy and culture positivity.

Management of the cases were standardized and every patient has benefited of ocular samples followed by intravitreal and systemic broad-spectrum antibiotics.

Because of the patients that presented beyond Snellen visual acuities, visual results were categorized into Count fingers, Hand motion, Perception of light or No perception of light.

All analyses were performed using Microsoft Office Excel 2007.

## **Results :**

A total of 41 eyes from 41 patients were identified over the 5 years study period.

The mean age was 53,8 years, with a sex ratio of 1,7.

The mean time from onset of symptoms to presentation was 8 +/- 4 days (3 to 32) for postoperative endophthalmitis, and 13 +/- 9 days (**2 - 30**) for other causes.

The majority of endophthalmitis were exogenous (88%), especially post cataract surgery (29%), then come the other causes (Table 1).

Clinical findings are summarized in (Table 2)

Paraclinical investigations consisted in B-Scan ocular ultrasound, realized for 36 patients (Table 3) and microbiological findings of the 41 samples taken, 63 % were culture positive. Gram positive bacteria were isolated in 20 Samples, Gram negative bacteria in 4, and fungal in 2 (Table 4).

Treatment consisted in a first intravitreal antibiotic injection in all of 41 patients.

A second injection was made for 24 patients. The injected antibiotics were Vancomycin 10mg/1ml and Ceftazidime 20mg/1 ml.

Probabilistic systemic antibiotics consisted in a bi-therapy of levofloxacin (500 mg/12h) and imipenem/cilastatin (1g/8 hours) in all of our patients.

Antibiotics were adapted to microbial susceptibilities.

Adjunctive Fortified eyedrops (Ceftazidime 20 mg/ml, vancomycin 50 mg/ml) were given in 10 patients who presented a corneal abscess. All the patients benefited from local steroids (Prednisolone sodium phosphate 0,5 % every 3 hours), and 30 of them (73%) had subconjunctival dexamethasone injections. Failure of treatment occurred in 5 patients who unfortunately needed an eye evisceration. None therapeutic vitrectomy was made. Final BCVA improved in 49% of patients. The table 5 summarize the final visual outcomes.

## **Discussion :**

This retrospective study revealed the characteristics of 41 endophthalmitis in a tertiary Moroccan eye care center.

The mean age was 53,8 years old, which concords with results of other studies as shown by Ouhdad(6) . When it comes to etiologies, postoperative endophthalmitis, and more precisely post cataract surgery came first with a total of 12 cases (29%). This is legit as the cataract surgery is one of the most common surgical procedures performed in the world(7). Unfortunately, we do not have incidence data to compare it to literature, but it seems that post-cataract endophthalmitis occur in 0,1 % of cases(4,8). However other types of endophthalmitis as post-traumatic seem to be less frequent with rates of 25 %(9) , nor POST Intravitreal injection (IVI) with incidence of 0,05 %(10). Yet, we should always remember that epidemiology differs from country to another, a Chinese study from a tertiary center including 1593 patients shows us a totally different pattern : Post-traumatic endophthalmitis counts for 82.6%, followed by endogenous endophthalmitis in 7.8%, post ophthalmic surgery in 6.9%, and finally post corneal ulcer with perforation in 2.7% of cases(11).

Risk factors depends on type of endophthalmitis. In post-cataract surgery endophthalmitis, main risk factors isolated are male gender, older individuals > 85 years, no intracameral antibio-prophylaxis, posterior capsular rupture, clear corneal incision, silicone based IOL (12). Regrettably, our study did not intend to isolate risk factors with significant association, but none of our patients was older than 77 years. However, 63% of our patients had diabetes, which is described as a risk factor for endogenous endophthalmitis, same as intravenous drugs users, with an incidence up to 0,4% of endogenous endophthalmitis (EE)(13).

Mean time from symptoms occurrence to admission was 9.7 days in a Chinese study including all types of endophthalmitis, which corroborates our results. When it comes to clinical findings, the table 6 compare our results to other studies.

As far as the microbial profile depends on the type of endophthalmitis, our comparison should take into account the different subgroups.

The most common organisms in culture-positive post-cataract endophthalmitis remain the Gram positive organisms, accounting for 92 to 95% of culture-positive isolates depending on country(3,14). Our study isolated 75 % of Gram-positive bacteria in post cataract surgery, which is not that representative due to small number of isolated strains (total of 8). When it comes to Gram-negative post-cataract surgery strains, they account for 6% to 8% of cultures and include Pseudomonas, Proteus and Hemophilus Influenzae. Our microbial findings corroborate again our non-representative microbial profile, with about 25 % of Gram-negative strains. Endogenous endophthalmitis have a different microbial findings, with 25 to 65% of fungal isolates(3,11), an interval that includes our results, 50 % of our EE microbial findings were candida.

When it comes to post-traumatic endophthalmitis, Gram positive bacteria remain preponderant with 52 % to 66 %(11,15), then come in order of frequency, Gram negative bacteria and finally fungal.

Finally, it is also important to note that in literature, approximately 70% of collected cultures are positive for organisms which is parallel to our findings (63 %)(3).

Prognosis remain dark when it comes to functional outcomes of endophthalmitis, but still depends on its type. Postsurgical endophthalmitis have globally a better outcome than endogenous endophthalmitis, with 40 % the the final BCVA >4/10 (3,16). However, the visual outcome of endogenous endophthalmitis remain poor due to early and extensive retinal involvement, and depends on causative agent(17), as bacterial EE had only 29% of BCVA improvement when the fungal EE had likely 52% of improvement. In our study, none of our EE had final VA improvement.

Limits of our study:

The limits of our study reside intrinsically foremost in its retrospective and descriptive type, resulting in incorporating selection biases. In addition, sometimes incomplete records and extraction of data represent a major bias in order to draw the most representative profile of our endophthalmitis. Moreover, conjunctival samples do not represent microbial specimen responsible of endophthalmitis and may represent a large bias in identifying our microbial profile. Finally, it would be wise to further analyze our series of cases to identify different risk factors or prognostic factors in different subgroups of endophthalmitis to impact our future management of endophthalmitis.

## **Conclusion:**

Endophthalmitis remains one of the most difficult pathologies to manage in ophthalmology with the poorest prognosis. Yet, no solid scientific data has been published since the old big EVS and ESCRS studies. Future remain full of research perspectives either in preventing or treating endophthalmitis.

UNDER PEER REVIEW

Table 1 Etiologies (n=41)	
	N (%)
Endogenous endophthalmitis :	5 (12%)
Exogenous endophthalmitis:	36 (88%)
- Post cataract surgery	12 (29 %)
- Ocular Trauma	10( 24 %)
- By contiguity	10 (24%)
- Post Intravitreal injection	4 (9,7%)

Fig :1 :

### Endophthalmitis etiologies

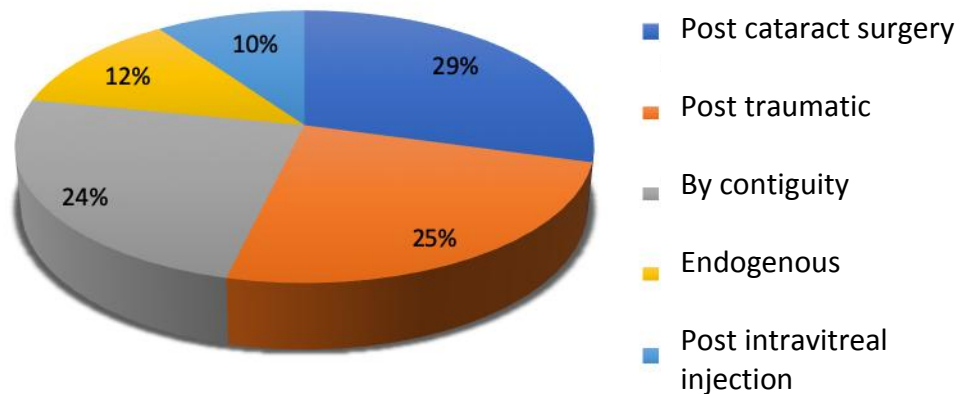


Table 2 Clinical characteristics of patients (n=41)	
	N (%)
Risk factors :	
Diabetes	26 (63%)
Cardiovascular disease	2 (5%)
Symptoms :	
- Visual acuity decrease	40 (98 %)
- Ocular pain	36 ( 88 %)
Initial Visual acuity :	
Count Fingers	3 (6 %)
Hand motion	22 (53 %)
Perception Of light	16 (39%)
No perception of light	1 (2) %)
Biomicroscopic findings :	
Conjunctival hyperhemia	38 (92,6%)
Corneal edema	
Hypopion	28 (68%)
Flare or Cyclitic membrane in anterior chamber	25 (60,9%)
	8 (19,5)

Table 3 B-Scan ultrasound findings (n=36)	
	N
Multiple Vitreous exudates	36
Posterior vitreous detachment	23
Retinal detachment	1

Table 4

Microbiological findings (n=26)			
	Post operative	Others	Total
Gram positive bacteria :			
Staphylococcus sp	4	10	14(54%)
Streptococcus sp	2	4	6 (22%)
Gram Negative bacteria :			
- Pseudomonas aeruginosa	2	0	2 (8%)
- Haemophilus	0	2	2 (8%)
Fungal :			
- Candida Albicans	0	2	2 (8)

--	--	--	--

Table 5

Etiology	Visual outcomes					Total
	Postoperative	Post IVI	Post Trauma	By contiguity	Endogenous	
Improved BCVA	7	4	6	3	0	20
Stabilized BCVA	3	0	2	3	2	10
Worsen BCVA	2	0	2	4	3	11

TABLE 6

	EVS(3)	Chiquet(18)	CHU Fès(6)	Our study
Conjunctival hyperemia	80,6%	81%	74,6%	92,6 %

Corneal edema		40%		68 %
Hypopion	75 %	75 %	46,5%	60,9 %
Flare or cyclitic membrane in anterior chamber		90%	16,2%	19,5%

## Reference :

1. Chee SP, Jap A. Endogenous endophthalmitis. *Curr Opin Ophthalmol* [Internet]. 2001 Dec [cited 2019 Jul 16];12(6):464–70. Available from: <http://www.ncbi.nlm.nih.gov/pubmed/11734687>
2. Flynn HW, Batra NR, Schwartz SG, Grzybowski A. Endophthalmitis: Classification and Most Frequently Reported Organisms. In Springer, Cham; 2018 [cited 2019 Jul 16]. p. 1–18. Available from: [http://link.springer.com/10.1007/978-3-319-66351-7\\_1](http://link.springer.com/10.1007/978-3-319-66351-7_1)
3. Results of the Endophthalmitis Vitrectomy Study. A randomized trial of immediate vitrectomy and of intravenous antibiotics for the treatment of postoperative bacterial endophthalmitis. Endophthalmitis Vitrectomy Study Group. *Arch Ophthalmol* (Chicago, Ill 1960) [Internet]. 1995 Dec [cited 2019 Jul 16];113(12):1479–96. Available from: <http://www.ncbi.nlm.nih.gov/pubmed/7487614>
4. ESCRS Endophthalmitis Study Group. Prophylaxis of postoperative endophthalmitis following cataract surgery: Results of the ESCRS multicenter study and identification of risk factors. *J Cataract Refract Surg* [Internet]. 2007 Jun [cited 2019 Jul 16];33(6):978–88. Available from:



- <http://www.ncbi.nlm.nih.gov/pubmed/17531690>
5. Mishra D, Satpathy G, Chawla R, Venkatesh P, Ahmed NH, Panda SK. Utility of broad-range 16S rRNA PCR assay versus conventional methods for laboratory diagnosis of bacterial endophthalmitis in a tertiary care hospital. *Br J Ophthalmol* [Internet]. 2019 Jan [cited 2019 Jul 16];103(1):152–6. Available from: <http://www.ncbi.nlm.nih.gov/pubmed/30315133>
  6. OUHDAD Y. LES ENDOPHTALMIES ETUDE RETROSPECTIVE A PROPOS DE 99 CAS [Internet]. Université Sidi Mohammed Ben abdellah Fes; 2011 [cited 2019 Jul 16]. Available from: [http://scolarite.fmp-usmba.ac.ma/cdim/mediatheque/e\\_theses/48-11.pdf](http://scolarite.fmp-usmba.ac.ma/cdim/mediatheque/e_theses/48-11.pdf)
  7. Vision 2020: the cataract challenge. *Community eye Heal* [Internet]. 2000 [cited 2019 Jul 16];13(34):17–9. Available from: <http://www.ncbi.nlm.nih.gov/pubmed/17491949>
  8. Keay L, Gower EW, Cassard SD, Tielsch JM, Schein OD. Post-cataract Surgery Endophthalmitis in the United States: Analysis of the Complete 2003-2004 Medicare Database of Cataract Surgeries. *Ophthalmology* [Internet]. 2012 [cited 2019 Jul 16];119(5):914–22. Available from: <https://www.ncbi.nlm.nih.gov/pmc/articles/PMC3343208/pdf/nihms340631.pdf>
  9. Affeldt JC, Flynn HW, Forster RK, Mandelbaum S, Clarkson JG, Jarus GD. Microbial endophthalmitis resulting from ocular trauma. *Ophthalmology* [Internet]. 1987 Apr [cited 2019 Jul 16];94(4):407–13. Available from: <http://www.ncbi.nlm.nih.gov/pubmed/3495766>
  10. Benoist d’Azy C, Pereira B, Naughton G, Chiambaretta F, Dutheil F. Antibioprophylaxis in Prevention of Endophthalmitis in Intravitreal Injection: A Systematic Review and Meta-Analysis. Mori K, editor. *PLoS One* [Internet]. 2016 Jun 3 [cited 2019 Jul 16];11(6):e0156431. Available from: <http://www.ncbi.nlm.nih.gov/pubmed/27257676>
  11. Yang XB, Liu YY, Huang ZX, Mao Y, Zhao L, Xu ZP. Clinical analysis of 1593 patients with infectious endophthalmitis: A 12-year study at a Tertiary Referral Center in Western China. *Chin Med J (Engl)*. 2018 Jul 20;131(14):1658–65.
  12. Cao H, Zhang L, Li L, Lo S. Risk Factors for Acute Endophthalmitis following Cataract Surgery: A Systematic Review and Meta-Analysis. Vavvas D, editor. *PLoS One* [Internet]. 2013 Aug 26 [cited 2019 Jul 16];8(8):e71731. Available from: <http://www.ncbi.nlm.nih.gov/pubmed/23990980>
  13. Relhan N, Forster RK, Flynn HW, Jr. Endophthalmitis: Then and Now. *Am J Ophthalmol* [Internet]. 2018 [cited 2019 Jul 16];187:xx–xxvii. Available from: <http://www.ncbi.nlm.nih.gov/pubmed/29217351>
  14. Yang X-B, Liu Y-Y, Huang Z-X, Mao Y, Zhao L, Xu Z-P. Clinical Analysis of 1593 Patients with Infectious Endophthalmitis. *Chin Med J (Engl)* [Internet]. 2018 Jul 20 [cited 2019 Jul 16];131(14):1658–65. Available from: <http://www.ncbi.nlm.nih.gov/pubmed/29998884>
  15. Long C, Liu B, Xu C, Jing Y, Yuan Z, Lin X. Causative organisms of post-traumatic endophthalmitis: a 20-year retrospective study. *BMC Ophthalmol* [Internet]. 2014 Dec 25 [cited 2019 Jul 16];14(1):34. Available from: <http://www.ncbi.nlm.nih.gov/pubmed/24661397>
  16. Königsdörffer E, Augsten R, Oehme A, Strobel J. [Prognosis of postoperative endophthalmitis]. *Ophthalmologe* [Internet]. 2000 Feb [cited 2019 Jul 16];97(2):121–5. Available from: <http://www.ncbi.nlm.nih.gov/pubmed/10734738>
  17. Connell PP, O’Neill EC, Fabinyi D, Islam FMA, BATTERY R, McCombe M, et al. Endogenous endophthalmitis: 10-year experience at a tertiary referral centre. *Eye (Lond)* [Internet]. 2011 Jan [cited 2019 Jul 16];25(1):66–72. Available from: <http://www.ncbi.nlm.nih.gov/pubmed/20966972>
  18. Chiquet C, Aptel F, Combey-de Lambert A, Bron AM, Campolmi N, Palombi K, et al. Occurrence and risk factors for retinal detachment after pars plana vitrectomy in acute postcataract bacterial endophthalmitis. *Br J Ophthalmol* [Internet]. 2016 Oct [cited 2019 Jul 16];100(10):1388–92. Available from: <http://www.ncbi.nlm.nih.gov/pubmed/26802175>