

## **NUTRITION AND ORAL HEALTH: A MINI REVIEW**

---

### **ABSTRACT (ARIAL, BOLD, 11 FONT, LEFT ALIGNED, CAPS)**

NUTRITION IS A PART OF SYSTEMIC HEALTH IN MAINTAINING AN EQUILIBRIUM BETWEEN THE HEALTHY AND ILL STATUS. AS A PART OF OUR REGULAR DIET AND INTAKE AS SUPPLEMENTS IT PLAYS A MAJOR ROLE IN MAINTAINING ORAL HEALTH .THIS ARTICLE FOCUSES ON ROLE OF VARIOUS NUTRIENTS THAT PLAY A MAJOR ROLE IN MAINTAIN ORAL HEALTH.

*Keywords: Nutrients, Oral health, Vitamin C, Vitamin D*

### **2. MATERIAL AND METHODS / EXPERIMENTAL DETAILS / METHODOLOGY (ARIAL, BOLD, 11 FONT, LEFT ALIGNED, CAPS)**

WHO states "Nutrition is the science of food and its relationship to health"[1,2].Interdependent relationship between nutritional intake and affects of these nutrients on oral health portrays major factors in improving oral inflammatory and diseased condition[3,4].This continuous synergy makes intake of adequate quantity of particular ratio mandatory for well being[5].A nutritious diet refer's to adequate intake of vitamins,proteins,micronutrients and essential fatty acids[6]Disease progression and imbalanced oral health without any other contributing factors may attribute to the imbalance in nutritional intake[7].WHO defines malnutrition as cellular imbalance between supply of nutrients, energy and body's demand for them to ensure growth ,maintenance and specific function[8]

#### **DIET AND ORAL HEALTH:**

Importance of nutrients and nutritional intake begins from stage of tooth formation. Below mentioned are deficiency and effect of malnutrition in oral health [9].

<b>VITAMIN C</b>	Irregular dentin formation, Dental pulpal alterations Bleeding gums, Delayed wound healing, Defective collagen formation.
<b>VITAMIN D</b>	Lowered plasma calcium, Hypomineralization Compromised tooth integrity, Delayed eruption pattern Absence of lamina dura, Abnormal alveolar bone patterns
<b>VITAMIN B 12</b>	Angular cheilosis, Halitosis Bone loss, Hemorrhagic gingivitis, Detachment of periodontal fibers, Painful ulcers in the mouth.
<b>IRON</b>	Salivary gland dysfunction Very red, painful tongue with a burning sensation, Dysphagia, Angular cheilosis
<b>VITAMIN A</b>	Decreased epithelial tissue development, Impaired tooth formation, Enamel hypoplasia.

PROTEIN ENERGY MALNUTRITION (PEM) occurs when there is deficiency in energy foods, protein and both. Amongst types of PEM severe PEM is deficiency of both energy and proteins. This type of status of the body during growth and development affects the oral structures [5]

I) Insufficient protein can cause:[11,12]

- Atrophy of the lingual papillae,
- Alteration in cementogenesis
- Alteration in dentinogenesis,
- Connective degeneration,
- Altered development of the maxilla,
- Malocclusion
- Linear hypoplasia of the enamel.

II) Insufficient Lipids can cause:

- Degeneration of glandular parenchyma,
- Parotid swelling—hyposalivation,
- Inflammatory and degenerative pathologies
- Altered mucosal trophism.

III) Insufficient Carbohydrates can cause:

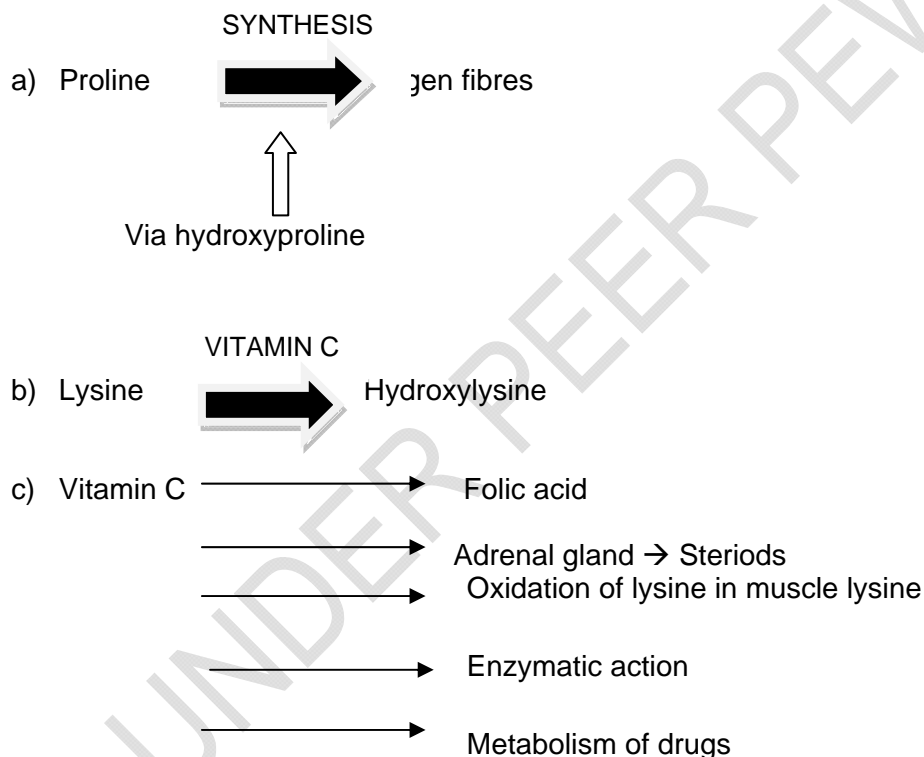
- altered organogenesis,
- influence of the metabolism on the dental plaque,
- caries,
- periodontal disease

## **ROLE OF VITAMINS:**

### **A) VITAMIN C: L-ASCORBIC**

Vitamin C as antioxidant or co-factor performs various function and is critical for oral health. Ascorbic acid is a reduced form of vitamin C; effective anti-oxidant readily converts back to the active reduced form owing to its high electron donating power. Its concentration is maintained between cellular transport systems. Recommended RDA for vitamin C is 46mg/dL and intake of citrus fruits, kiwi fruit, mango, papaya, pineapple with highest source of vitamin C prevents deficiency [13].

Ascorbate donates electrons to few non-enzymatic and enzymatic reactions. Two oxidized form of vitamin C i.e. semidehydroascorbic acid can be reduced in the body by glutathione and NADPH dependent enzymatic mechanism. Therefore glutathione in cells and fluids helps ascorbate to maintain its reduced state [14]. In oral health vitamin C plays a major role in structural and chemical levels [15]



Scurvy results from lack of vitamin C due to which synthesized collagen is unstable and cannot perform normal function. A normal adult with 70 Kg mass should ideally have vitamin C reserve of 1500 mg. Therefore this avitaminosis condition manifestate when the reserve is reduced to 300mg. Clinically scurvy manifestate with swollen bleeding spongy gums and mucous membrane eventually may lead to suppurative wounds, loss of teeth and leading to death [16]. Another important function of vitamin C is its action as anti-oxidant. Exposure to higher level of dietary xenobiotic results in generation of reactive oxygen species. The generation of free radicals increases oxidative stress and leads to various disease state. To neutralize these stress enhancement of cellular defense in the form of anti-oxidants are important. Vitamin C is a non-enzymatic anti-oxidant which works by interrupting the free radical chain reaction. It is a small molecule anti-oxidant that scavenges the free radicals [17].

Heu WC and Smith conducted a series of studies to evaluate the ascorbic acid content in saliva in carious and non-carious individuals. They standardized the level of vitamin C in saliva to be 0.25mg% and these levels varied with age. They concluded that there did not exist any relationship between the variables[18].Hegde MN et al conducted study to evaluate the relationship between salivary Vitamin C levels in dental caries experience showed low salivary vitamin C levels in caries active adults suggesting role of vitamin C has antioxidants[19] which is in accordance with another study conducted by Hegde MN et al[20].An invitro study conducted showed decrease in vitamin C levels in oral precancerous conditions may be attributed to the high lipid peroxidation levels[21].A study conducted by Bhat S at al showed that salivary vitamin C estimation could assist in early diagnosis of potential malignant disease/oral cancer and is a reliable non-invasive tool[22].The intake of vitamin C as a nutrient in diet or supplementation may help in prevention of avitaminosis and therefore if adequate levels maintained may contribute to better and good oral and systemic health.

#### **B)VITAMIN D:**

Vitamin D levels regulate the calcium levels also plays a major role in immune and inflammation system. They stimulate various effector molecules in innate immunity ,also is critical for activation of anti-microbial peptide[23,24]Studies conducted by Yu M et al and Kong YY to explore the link between Vitamin D receptor gene polymorphism and occurrence of dental caries concluded that there is association between caries and polymorphism[25,26]

Vitamin D is a fat soluble vitamin can be procured by dietary supplement and from sunlight that trigger's vitamin D synthesis .RDA for vitamin D is 400- 800 mcg and highest source for vitamin D would be fatty fishes ,egg yolk and cheese. According to National health and Nutrition examination survey(NHANES) from 204 to 288 IU/day in males and 144-276 IU/day in females. Dietary supplements for vitamin are available in D2 and D3 forms. Inspite of the understanding of severity of low vitamin D levels most of the population is vitamin D deficient which may lead to poor bone health and enhancement of inflammation[27]

#### **B)OMEGA 3:**

Three major omega 3 are alpha linolenic acid, eicosapentanoic acid and docosahexaenoic acid .They form important component of membrane that surround each cell in our body. The potential decrease in the risk of dental diseases are associated with omega 3 and has been linked with potential anti-inflammatory effects of DHA[28] Omega 3 are naturally found in seafood -salmon ,mackrel,tuna,nuts,chia seeds, plants oils ,soya beans etc. PUFA intake can influence the hormone, metabolism of lipids and lipoproteins which affect the inflammation process. They ensure correct membrane protein function, signalling pathways [29].

A study conducted among US adults in which the association between omega 3 fatty acids and periodontitis was learnt and found that n-3 intake as an additional dietary supplementation during mechanical cleaning and local antibiotics application would be an added benefit in decreasing the chronic disease condition[30] A pilot study was conducted to evaluate the treatment outcome in individuals with aggressive periodontitis with dietary fatty acid supplementation showed beneficial effects. Thus a trend towards treatment of condition with nutritional supplementation enhances the treatment outcome [31].

#### C)VITAMIN B12:

Vitamin B 12 is not produced from animals/plants, deficiency of vitamin B 12 leads to intraoral symptoms like pale mucosa, apthous ulcer, stomatitis, candidiasis, chelitis, glossitis, the presence of above symptoms suggest anemia. RDA for vitamin B 12 is 1-2µg. It acts as co-factor/co-enzyme and synthesis of methionine [32] A study conducted by Hugar SM et al showed increased dental caries and prevalent gingivitis in individuals with vitamin B 12 deficiency [33]. Risk factors for vitamin B complex include old age, medication, alcohol abuse and malabsorption [34]

#### 4. CONCLUSION

In spite of tremendous improvement in oral health care measure and awareness among people there are factors unconsidered which inversely affect the oral health. Nutrient and dietary supplements when added along with clinical or mechanical treatment for various oral diseases yield better results. Clinicians and health care personnel should recommend change in diet plans for additional benefits through the process of treatment.

#### REFERENCES

1. Psoter WJ, Reid BC, Katz RV. Malnutrition and Dental Caries: A Review of the Literature. *Caries Res.* 2005 ; 39(6): 441–47.
2. Russell SL, Psoter WJ, Charles GJ, Prophte S, Gebrian B. Protein-energy malnutrition during early childhood and periodontal disease in the permanent dentition of Haitian adolescents aged 12–19 years: a retrospective cohort study. *Int J Paediatr Dent.* 2010 ;20(3): 222–29.
3. Ritchie CS, Joshipura K, Hung HC, Douglass CW. Nutrition as a mediator in the relation between oral and systemic disease: Associations between specific measures of adult oral health and nutrition outcomes. *Crit Rev Oral Biol Med* 2002;13(3):291-300.
4. Mangan DF. Nutrition and oral infectious diseases: Connections and future research. *Compend Cont Educ, Dent* 2002; 23(5):416-422.
5. Sheetal A, Hiremath VK, Patil AG, Sajjansetty S, and Kumar SR. Malnutrition and its Oral Outcome – A Review. *Journal of Clinical Diagnostic Research* 2013;7(1):178–180.
6. Enwonwu CO, Phillips RS, Falkler WA, Jr. Nutrition and oral infectious diseases: State of the science. *Compend Cont Educ Dent* 2002; 23(5):431-434, 436, 438.
7. Mandel ID. Oral infections: Impact on human health, wellbeing, and health-care costs. *Compend Cont Educ Dent*, 2002; 23(5):403-413.
8. WHO. Malnutrition. The Global Picture. World Health Organization. <http://www.who.int/home>
9. Alvarez JO, Navia JM. Nutritional status, tooth eruption, and dental caries: a review. *Am J Clin Nutr.* 1989;49:417-26.
10. Chicago Dental Society, "Good oral health starts with exercise, eating right," *CDS Review*, vol. 104, no. 2, p. 34, 2011.
11. Dye BA, Barker LK, Li X, Lewis BG, Beltr ED, "Overview and quality assurance for the oral health component of the National Health and Nutrition Examination Survey (NHANES), 2005–08," *Journal of Public Health Dentistry*, vol. 71, no. 1, pp. 54–61, 2011.

12. Scardina GA and Messina P, "Nutrition and oral health," *Recenti Progressi in Medicina*, vol. 99, no. 2, pp. 106–111, 2008.(Italian).
13. Touyz LZG. Vitamin C, oral scurvy and periodontal disease. *SA. Med J* 1984; 65: 838-42.
14. Rathee M, Bhorla M, Kundu R. Vitamin C and Oral Health: A Review. *INDIAN JOURNAL OF APPLIED RESEARCH*. **3 (9) Sept 2013. ISSN - 2249-555X**
15. Jacob RA, Sotoudeh G. Vitamin C function and status in chronic disease. *Nutr Clin Care* 2002; 5: 66-74
16. Hathcock JN. Vitamin and Mineral Safety. 2nd edition 2004.
17. Nimse SB<sup>a</sup> and Pal D. Free radicals, natural antioxidants, and their reaction mechanisms. *RSC Adv*, 2015, **5**, 27986-28006
18. Hess WC And Smith BT.The Ascorbic Acid Content Of The Saliva of Carious And Noncarious Individuals. Volume 28 Number 5. *Journal of D R*.October 1949
19. Hegde MN , Kumari S, Hegde ND & Shetty S. Relation Between Salivary And Serum Vitamin C Levels And Dental Caries Experience In Adults - A Biochemical Study. *Nujhs Vol. 3, No.4, December 2013, Issn 2249-7110*
20. Hegde MN, Hegde ND, Kumari S, Jathanna VR. Correlation Between Vitamin C Level And Dental caries – A Clinical Study. *Jcaesok*. 2011;1(2):59-61.
21. Hegde ND , Kumari S, Hegde MN , Chandra MP, Nireeksha. Lipid peroxidation and Vitamin C levels in oral precancerous condition. April – June 2011 *RJPBCS Volume 2 (2) ; 13*
22. Bhat S, Babu SG, Bhat SK, Castelino RL, Rao K, Madi M. Status of serum and salivary ascorbic acid in oral potentially malignant disorders and oral cancer. *Indian J Med Paediatr Oncol* 2017;38:306-1
23. Uwitonzea AM, Murerereheb J, Inezac MC , Harelimanac EI, Nsabimana U.(2018) Effects of vitamin D status on oral health .*Steroid Biochemistry & Molecular Biology* 175(190–194)
24. Gombart AF, Borregaard N. (2005) Human cathelicidin antimicrobial peptide (CAMP) gene is a direct target of the Vitamin D receptor and is strongly up-regulated in myeloid cells by 1,25-dihydroxyvitamin D<sub>3</sub>. *The FASEB Journal*. Vol. 19 (7)
25. Yu M, Jiang QZ , Sun ZY, Kong YY, Chen Z.(2017) Association between single nucleotide polymorphisms and permanent tooth caries susceptibility to permanent tooth caries in Chinese adolescents. Volume 1.p-7
26. Kong YY, Zheng JM, Zhang JW, Jiang QZ, Yang XU, Yu M, Zeng SJ(2017) The relationship between Vitamin D receptor gene polymorphism and deciduous tooth decay in chinese children. *BMC Oral Health* (2017) 17:111
27. Holick MF. Vitamin D deficiency. *N Engl J Med* 2007;357:266-81.
28. [https://www.nutraingredients.com/Article/2014/07/14/DHA-omega-3-linked-to-significantly-improved-periodontal-outcomes-Harvard-data?utm\\_source=copyright&utm\\_medium=OnSite&utm\\_campaign=copyright](https://www.nutraingredients.com/Article/2014/07/14/DHA-omega-3-linked-to-significantly-improved-periodontal-outcomes-Harvard-data?utm_source=copyright&utm_medium=OnSite&utm_campaign=copyright)
29. Calder PC. Omega-3 Fatty Acids and Inflammatory Processes. *Nutrients* 2010, 2, 355-374; doi:10.3390/nu2030355
30. Naqvi AZ, Buettner C, Phillips RS, Davis RB, Mukamal KJ. n-3 fatty acids and periodontitis in US adults. *J Am Diet Assoc*. 2010;110(11):1669-75.
31. Rosenstein, Elliot D. et al. Pilot study of dietary fatty acid in the treatment of adult periodontitis .*Prostaglandins, Leukotrienes and Essential Fatty Acids* , Volume 68 , Issue 3 , 213 - 218
32. Pontes HA, Neto NC, Ferreira KB, Fonseca FP, Vallinoto GM, Pontes FS, et al. Oral manifestations of vitamin B12 deficiency: A case report. *JCDA*. 2009; 75: 533-7.
33. M Hugar S, S Dhariwal N, Majeed A, Badakar C, Gokhale N, Mistry L. Assessment of Vitamin B<sub>12</sub> and Its Correlation with Dental Caries and Gingival Diseases in 10- to 14-year-old Children: A Cross-sectional Study. *Int J Clin Pediatr Dent*. 2017;10(2):142-146.
34. Wilcox AJ, Lie RT, Solvoll K, et al. Folic acid supplements and risk of facial clefts: national population based case-control study. *BMJ*. 2007 Mar 3;334(7591):464.

248  
249  
250  
251

UNDER PEER REVIEW