

1 **Original Research Article**

2 **THE EFFECT OF ETHANOLIC EXTRACT OF *TRIDAX PROCUMBENS* ON**  
3 **POTASSIUM BROMATE INDUCED TOXICITY IN THE KIDNEY OF WISTAR**  
4 **RATS.**

5  
6  
7 **ABSTRACT**

8 **Aim:** To investigate the histological effect of ethanolic extract of *Tridax procumbens* leaf commonly  
9 used as medicinal plant, on potassium bromate induced renotoxicity in adult wistar rats.

10 **Place and Duration of Study:** Department of Anatomy, Faculty of Basic Medical Sciences, Abia  
11 State University, Uturu Nigeria within three months.

12 **Methodology:** Twenty adult wistar rats weighing between 160 – 180g were divided into four groups  
13 of five rats each. Group A served as the control and received distilled water only for 14 days, Group B  
14 received 100mg/kg of potassium bromate only for 14 days, Group C received 300mg/kg of *Tridax*  
15 *procumbens* leaf extract only for 14 days and Group D received 100mg/kg of potassium bromate +  
16 300mg/kg of *Tridax procumbens* leaf extract simultaneously for 14 days. Twenty four hours after the  
17 last administration, the animals were weighed, anaesthetized and sacrificed. The kidneys were  
18 harvested and weighed. Statistical analysis using one way ANOVA and Dunnett's post hoc test was  
19 done for all parameters measured. The significance was set at  $P < 0.05$ .

20 **Results:** There was significant decrease in mean body weight of group B animals ( $178.0 \pm 4.55$  to  
21  $162.3 \pm 2.59$ ) and significant increase in kidney weight of group B animals ( $0.75 \pm 0.02$ ) when  
22 compared to the control and other treated groups. Extract of *Tridax procumbens* inhibited potassium  
23 bromate induced weight loss and increase in kidney weight. Histologically, there was no significant  
24 pathology of the kidney tissue after treatment with *Tridax procumbens*.

25 **Conclusion:** From this study, it can be deduced that ethanolic extract of *Tridax procumbens* leaf has  
26 got significant protective effect against potassium bromate induced toxicity in the kidney of wistar rats.

27 **Keywords:** *Tridax procumbens*, Toxicity, Potassium Bromate and Kidney, Weight Gain.

28

## 29 **1.0 INTRODUCTION**

30 Potassium bromate ( $KBrO_3$ ) is an oxidizing agent that exists as a white crystal powder. It has been  
31 used as a food additive mainly in the making of bread and as dough conditioner [1]. Potassium  
32 bromate has been found to be generated as a contaminant in drinking water; this is due to the  
33 conversion of bromide found naturally in water to bromate by ozone which is used as disinfectant  
34 [2,3]. Toxicity studies have shown the dangers potassium bromate poses to health if consumed in  
35 water or food, with previous reports documenting the induction of multiple organ toxicity in humans  
36 and experimental animals [4,5]. Furthermore, researchers found potassium bromate to have the  
37 potential of inducing cancer, liver failure, kidney failure, deafness, pains, redness of the eye and skin  
38 [6,7]. This led to the ban of potassium bromate as food additives in several developed and developing  
39 countries [8]. Despite its ban, some developing countries still make use of potassium bromate as flour  
40 enhancer.

41 Plant derived products have been used for medicinal purposes for centuries and presently, it is  
42 estimated that about 80% of the world population relies on botanical preparations as medicines to  
43 meet their health needs [9]. This may be attributable to the down turn in the economy, as herbal  
44 medicine is perceived to be a cheaper means of treatment [10]. *Tridax procumbens* Linn (Family  
45 Asteraceae) is specie of flowering plant in the daisy family. Its common names include “coat button”  
46 and “Tridax daisy” in English, “cadillo chisaca” in Spanish, “herbe caille” in French, “jayanti veda” in  
47 Sanskrit, “Ghamra” in Hindi, “Doyadi” in Marathi, “Thata poodi” in tamil, “Kotobukigiku” in chinese,  
48 “Bishalya Karani” in Oriya, “Chiravanak” in malayalam and “mbuli” in Ibo [11]. *Tridax procumbens* is  
49 native to Central America and tropical South America, but has spread throughout the tropical and  
50 subtropical parts of the world [12]. Extract of this plant has been found to possess significant  
51 medicinal properties against blood pressure, bronchial catarrh, malaria, dysentery, diarrhea, stomach  
52 ache, headache and wound healing [13]. In addition, the plant has also shown various

53 pharmacological activities like Immunomodulatory, Antidiabetic, Antihepatotoxic and Anti-oxidant,  
54 Anti-inflammatory, Analgesic, and marked depressant action on respiration [14-18].

55 Most organ function impairment is a direct consequence of changes in the histological structures of  
56 the organ. With limited information on the cellular changes associated with potassium bromate toxicity  
57 in kidney tissues, this study therefore investigates the effect of *Tridax procumbens* on potassium  
58 bromate induced toxicity in the kidney.

## 59 **2.0 MATERIALS AND METHODS**

### 60 **2.1 Animals**

61 Twenty (20) healthy adult wistar rats weighing between 160-180g were procured from the animal  
62 house of Abia State University, Uturu. They were kept in standard cages under normal temperature  
63 (27-30°C) and were fed with Guinea feeds (pelletized) and water *ad libitum*. The animals were  
64 acclimatized for a period of two weeks before treatment. The ethical committee of the College for  
65 animal care and use, Abia State University, Uturu approved the study design in compliance with the  
66 National regulation for animal research.

### 67 **2.2 Collection and Preparation of Plant Material**

68 Fresh leaves of *Tridax procumbens* were obtained from Uturu, Abia State and were identified by the  
69 Herbarium officer of Botany department, Abia State University, Uturu. The leaves were rinsed in a  
70 basin of water to remove sand and debris, put in a sieve to drip off water and then dried at 40°C in a  
71 thermostatically controlled oven. The dried leaves were crushed into fine powder using a laboratory  
72 blender and extraction was done using ethanol. The coarse powder was soaked in ethanol for forty  
73 eight (48) hours and then filtered into a beaker with a white cloth. The filtrate was concentrated using  
74 a rotary evaporator and further dried using laboratory oven into a jelly-like form and stored in  
75 refrigerator for future use. The stock solution of the extract was prepared by dissolving 1g of the  
76 extract in 10ml of distilled water.

77 Potassium bromate was procured from the Department of Biochemistry, Abia State University, Uturu.  
78 1g of potassium bromate was dissolved in 20ml of distilled to give a concentration of 50mg/ml.

## 79 **2.3 Experimental Protocol**

80 The twenty adult wistar rats were weighed and randomly allocated into four (4) groups of five animals  
81 each, designated as groups A, B, C and D.

82 Group A served as the control group and received 2ml/kg of distilled water only

83 Group B received 100mg/kg of potassium bromate only for 14 days

84 Group C received 300mg/kg of *Tridax procumbens* leaf extract only for 14 days

85 Group D received 100mg/kg of potassium bromate + 300mg/kg of *Tridax procumbens* leaf extract  
86 simultaneously for 14 days.

87 The extracts were administered orally once daily between the hours of 10-11am and lasted for a  
88 period of fourteen (14) days. Twenty four hours after the last administration, the animals were  
89 weighed, anaesthetized by chloroform inhalation and dissected. The kidneys were harvested,  
90 weighed and fixed in 10% formal saline for histological examination.

## 91 **2.4 Tissue Processing**

92 The kidney tissues were passed through the processes fixation, dehydration, clearing, infiltration,  
93 embedding, sectioning and staining. The tissues were fixed in 10% formal saline, followed by  
94 dehydration with graded percentages of alcohol (50%, 70%, 90% and absolute alcohol). After  
95 dehydration, the tissues were then cleared in xylene after which it was embedded in paraffin wax.  
96 Rotatory microtome was used to obtain tissue sections of 3-5µm thick. The sections were  
97 deparaffinised, hydrated and stained using Haematoxylin and Eosin (H&E) dye. The slides were later  
98 viewed under the light microscope and the images captured.

## 99 **2.5 Statistical Analysis**

100 Data was analysed using Statistical Package for Social Sciences (SPSS) software version 16  
101 (Chicago IL) and results were presented as Mean ± standard error of mean (SEM). One way Analysis  
102 of Variance (ANOVA; 95% confidence interval) was used to determine the significance of difference in

103 the means of all parameters. Dunnett post-hoc multiple comparison procedure was done for  
104 comparisons between treated groups and control.

### 105 3.0 RESULTS

#### 106 3.1 Body Weight Changes

107 Table 1 below shows the mean body weight changes in groups A, B, C and D respectively. There was  
108 significant ( $P = .003$ ) loss of body weight in group B compared to the control.

109 **Table 1:** Mean  $\pm$  SEM of initial mean body weight, final mean body weight and mean weight gain in all  
110 the groups (A, B, C and D)

GROUPS	INITIAL BODY WEIGHT	FINAL BODY	
		WEIGHT	WEIGHT GAIN
A	161.8 $\pm$ 9.91	177.3 $\pm$ 11.15	15.5 $\pm$ 3.01
B	178.0 $\pm$ 4.55	162.3 $\pm$ 2.59	-15.8 $\pm$ 2.95*
C	163.5 $\pm$ 5.81	179.8 $\pm$ 7.55	16.25 $\pm$ 8.98
D	162.3 $\pm$ 7.48	175.5 $\pm$ 5.91	13.25 $\pm$ 3.92

111 \*significant compared to control

#### 112 3.2 Kidney Weights

113 There was significant increase ( $P = .04$ ) in the relative kidney weight in group B compared to the  
114 control and other experimental groups (Table 2). The extract of *Tridax procumbens* showed no  
115 significant difference in the relative kidney weights of other groups when compared to the control.

116 **Table 2:** Effect of ethanolic extract of the leaf of *Tridax procumbens* on relative kidney weight of  
117 treated rats

118

GROUPS	KIDNEY WEIGHTS
A	0.59 $\pm$ 0.03
B	0.75 $\pm$ 0.02*
C	0.58 $\pm$ 0.08

D	0.59 ± 0.03
PROB. OF SIG.	<0.05

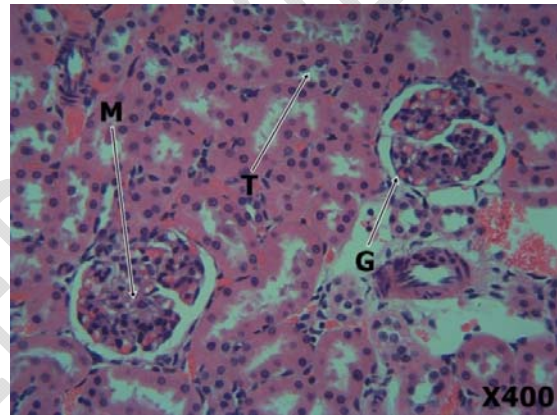
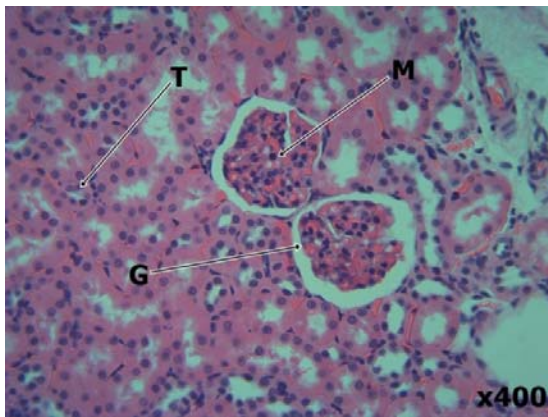
119 \_\_\_\_\_ \*significant compared to control

120

121

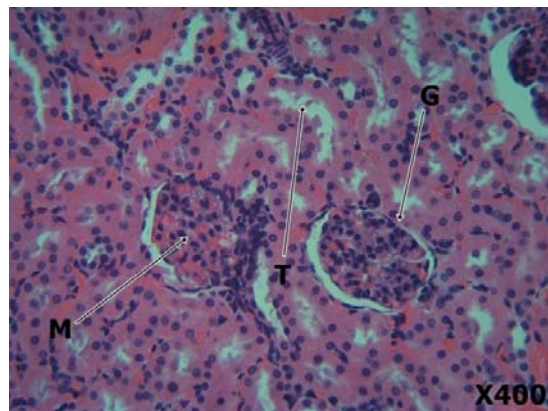
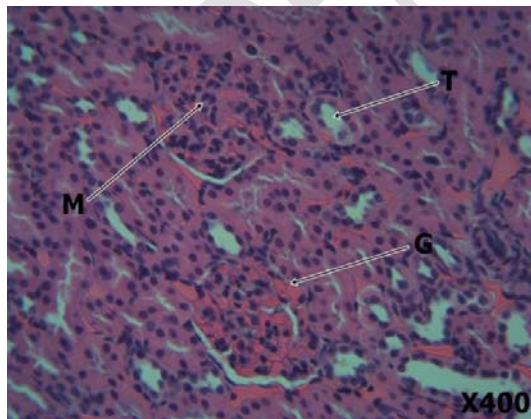
122

123 **3.3 Histological Findings**



125 Plate 1 (Control)

Plate 2 (Potassium bromate 100mg/kg)



126

127 Plate 3 (*Tridax procumbens* 300mg/kg)

Plate 4 (potassium bromate 100mg/kg + *Tridax*

128 *procumbens* 300mg/kg)

129 **Figure 1:** Plates 1-4 shows the photomicrograph of kidney tissues of the treated rats. Plate 1 is the  
130 kidney tissue of rats given distilled water showing normal features of the kidney such as glomeruli (G),  
131 renal tubules (T) and mesangium (M). Plate 2 is the kidney tissue of rats treated with 100mg/kg b.w of  
132 potassium bromate only showing severe distortion of renal architecture with focal tubular necrosis,  
133 severe haemorrhage in the interstitium and focal loss of glomeruli. Plate 3 is the kidney tissue of rats  
134 treated with 300mg/kg body weight of ethanolic extract of *Tridax procumbens* only showing mild  
135 congestion of the glomerulus, normal tubules and mesangium. Plate 4 is the kidney tissue of rats  
136 treated with 100mg/kg of potassium bromate and 300mg/kg of extract of *Tridax procumbens* showing  
137 moderate restoration of renal architecture to normal with healthy glomerulus, well perfused tubular  
138 tissue and normal mesangium. However, there is mild haemorrhage in the interstitium of some areas.

#### 139 **4.0 DISCUSSION**

140 Medicinal plants contain numerous biologically active compounds that have shown to be useful in  
141 improving the life and treatment of diseases [19]. *Tridax procumbens* appear to be a very promising  
142 medicinal plant containing many active molecules evident by its vast medicinal and pharmacological  
143 properties [18].

144 There was statistically significant reduction in body weight of animals in group B when compared to  
145 the control. This could probably be as a result of loss of appetite by the animals in the group or due to  
146 prolonged exposure to toxicity. This is in agreement with the findings of Okalie and Ikewuchi [20] who  
147 reported a significant reduction in the body weights of rabbits that received potassium bromate. In  
148 contrast, Farombi *et al.* [4] and Watanabe *et al.* [21] reported the absence of the effect of potassium  
149 bromate on the body weight of the animals.

150 The relative kidney weight showed a statistically significant increase in group B animals when  
151 compared to control group A. This however could be pathological as the kidney might have been  
152 inflamed due to toxicity. This is in support with previous works done by Farombi *et al.* [4] who reported  
153 relative liver and kidney weight increase in rats administered potassium bromate. The relative kidney  
154 weight of groups C and D were similar to that of the control and it could be as a result of the

155 antioxidant and anti-inflammatory properties present in the leaves of *Tridax procumbens* which are  
156 responsible for inhibiting inflammation.

157 The histopathological finding reveals that kidney tissues in group B showed cellular abnormality in the  
158 kidney with evidences of tubular necrosis. This may be due to the nephrotoxic effect of potassium  
159 bromate. This is in agreement with earlier studies by Akanji *et al.* [22] and El-Sokkary [23]. Group D  
160 showed normal kidney tissue architecture. This may be related to the importance of vitamin E as an  
161 antioxidant that scavenges free radicals curbing the damage mechanism of potassium bromate. This  
162 is in conformity with previous research by Adeluwoye *et al.* [24]) who showed that ethanolic extract of  
163 *Tridax procumbens* possesses some antioxidant effects.

## 164 **5.0 CONCLUSION**

165 The ethanolic extract of *Tridax procumbens* leaf showed no significant pathology in the kidney tissues  
166 of the rats. This study clearly demonstrates that *Tridax procumbens* has the potential ability to protect  
167 against potassium bromate induced kidney toxicity in adult wistar rats by acting as antioxidant.

168

169

170

## 171 **REFERENCES**

- 172 1. Diachenko GW and Warner CR. Potassium bromate in bakery products. In LEE, TC. and HO,  
173 CT. (Eds.). *Bioactive Compounds in Foods*. Washington: American Chemical Society. 2002 p.  
174 218.
- 175 2. Ueno H, Oishi K, Sayato Y, Nakamuno K. (2000). Oxidative Cell Damage in Kat-sod Assay of  
176 Oxyhalides as Inorganic Disinfection by-product and their Occurrence by Ozonation. *Arch*  
177 *Environ Contam Toxicol.* 2000;38(1):1-6.
- 178 3. Cavangagh JE, Weinberg HS, Gold A, Sangalah R, Marburg D, Glase W. Ozonation  
179 Byproducts; Identification of Bromohydrins from the Ozonation of Natural Waters with  
180 Enhanced Bromide Levels. *Environ. Sci. Technol.* 1992;26:1658-62.



- 181 4. Farombi EO, Alabi MC, Akuru TO. Kolaviron modulates cellular redox status and impairment  
182 of membrane protein activities induced by potassium bromate KBr O<sub>3</sub> in rats. *Pharmacol Res.*  
183 2002;45:63–8.
- 184 5. Dimkpa U, Ukoha UU, Anyabolu EA, Uchefuna RC, Anikeh LC, Oji OJ et al. Hepatotoxic  
185 Effects of Potassium Bromate on Adult Wistar Rats. *Journal of Biology, Agriculture and*  
186 *Healthcare.* 2013;3(7):111-115.
- 187 6. Mack RB. Round up the usual Suspects; Potassium bromate poisoning. *North Carolina*  
188 *Medical Journal* 1988;49: 243-245.
- 189 7. DeAngelo AB, George MH, Kilburn SR, Moore TM, Wolf DC. Carcinogenicity of potassium  
190 bromate administered in the drinking water to male B6C3F mice and F344/N rats. *Toxicologic*  
191 *Pathology.* 1998;26(5):587-594.
- 192 8. Ekop AS, Obot IB, Ikpatt EN. Anti-Nutritional Factors and Potassium Bromate Content in  
193 Bread and Flour Samples in Uyo Metropolis. *Niger. E-J. Chem.* 2008;5(4): 736-741.
- 194 9. Shri JNM. Ginger: It's Role in Xenobiotic Metabolism. *ICMR Bulletin.* 2003;33(6): 57-63.
- 195 10. Kamboj VP. Herbal medicine. *Curr Sci.* 2000;78:35-51.
- 196 11. Rahman AH, Alam MS, Khan SK, Ferdous A, Islam AK, Rahman MM. Taxonomic studies on  
197 the family Asteraceae (compositae) of the Rajshahi division. *Research Journal of Agriculture*  
198 *and Biological Sciences.* 2008;42: 134-140.
- 199 12. Chauhan BS and Germination DE. Ecology of Two Troublesome Asteraceae Species of  
200 Rainfed Rice: Siam Weed (*Chromolaena odorata*) and Coat Buttons (*Tridax procumbens*).  
201 *Johnson Weed Science.* 2008;56, 567–573.
- 202 13. Sahoo M and Chand PK. In vitro multiplication of a medicinal herb *Tridax procumbens* L.  
203 (Mexican Daisy, coat button): influence of explanting season, growth regulator synergy,  
204 culture passage and planting substrate. *Phytomorphology.* 1998;48: 195 – 206.
- 205 14. Ravikumar V, Shivashangari KS, Devaki T. Effect of *Tridax procumbens* on liver antioxidant  
206 defense system during lipopolysaccharid- induced in Dgalactosomine sensitized rats. *Mol. Cell*  
207 *Biochem.* 2005;269(1-2):131-6.

208 15. Vyas P, Suresh Tiwari U, Rastogi B, Singh P. Immunomodulatory effects of aqueous extract  
209 of *Tridax procumbens* in experimental animals. *Journal of Ethnopharmacology*.  
210 2004;92:113-119.

211 16. Bhagwat DA, Killedar SG, Adnaik RS. Anti-diabetic activity of leaf extract of *Tridax*  
212 *procumbens*. *International Journal of Green Pharmacy*. 2008;2:126-8.

213 17. Reddipalli H. Anti-hepatotoxic and anti-oxidant defense potential of *Tridax procumbens*. *Int. J.*  
214 *of Green Pharmacy*. 2008;2(3):164-169.

215 18. Diwan PV, Iravati K, Margaret I, Sattur PB. Pharmacology and Biochemical Evaluation of  
216 *Tridax procumbens* on inflammation. *Indian J of Pharmacology*. 1989;21: 1-7.

217 19. Shivananda N. Influence of Ethanol Extract of *Vinca rosea* on Wound Healing in Diabetic  
218 Rats. *Online Journal of Biological Sciences*. 2006;62: 51-55.

219 20. Okalie NP and Ikewuchi JC. Cataractogenic Potential of Bromate Mediated Oxidative Stress in  
220 Rabbits. *Journal Med. Sci*. 2004;4:158-163.

221 21. Watanabe S, Tajima Y, Yamaguchi T, Fukui T. Potassium bromate induced hyper-uricemia  
222 stimulates acute kidney damage and oxidative stress . *J.Health Sci*. 2004;50, 647-653.

223 22. Akanji MA, Nafiu MO, Yakubu MT. Enzyme activities and histopathology of selected tissues in  
224 rats treated with potassium bromate. *African Journal of Biomedical Research*. 2008;11: 87-95.

225 23. El-Sokkary GH. Melatonin protects against oxidative stress induced by the kidney carcinogen  
226 potassium bromate. *Neuroendocrinol*, 2006;21:461-468.

227 24. Adeluwoye AO, Odunola OA, Gbadegesin MA, Adelabu OO. Assessment of the Effect of  
228 Ethanol Extract of *Tridax Procumbens* (linn.) on Sodium Arsenite-induced Toxicities in Male  
229 Wistar Rats. *Am. J. Biomed. Sci*. 2017;9(3): 151-165.

230

231