

Comparative study between classic abdominoperineal resection versus sphincter saving techniques for treatment of low rectal cancer

Abstract:

Introduction : Intersphincteric resection of low rectal tumors is a surgical technique extending rectal resection into the intersphincteric space. This procedure is performed by a synchronous abdominoperineal approach with mesorectal excision and excision of the entire or part of the internal sphincter

Aim of the work : is to evaluate the oncological and functional outcome of classic abdominoperineal resection (APR) compared to sphincter sparing (intersphincteric resection) (ISR) procedures

Patient :Group A patients (10 patients) : who meet the criteria of ISR possibility and candidates for sphincter preserving procedures
Group B patients (10 patients) : who didn't meet the criteria to do ISR , were subjected to APR

Methods :*Total ISR involves complete excision of the internal sphincter. The cut line is at the intersphincteric groove. B. Subtotal ISR involves partial excision of the internal sphincter. The cut line is between the dentate line and the intersphincteric groove. C. Modified partial ISR the cut line is below the dentate line on one side of the tumor. On the opposite side of the tumor, the cut line is above the dentate line. .D Partial ISR the cut line is at or above the level of the dentate line*

Results : showed that after 6 months, out of 10 patients underwent ISR , 6 patients were highly satisfied with Grade I continence according to Kirwan's grade . While 4 patients were Grade II , i.e. : Incontinent to flatus .Non significant difference in the rate of recurrence between the two groups .

Conclusion: in low rectal cancer, the sphincter preservation appears to have nearly the same oncologic outcome compared to APR,. However, patients with sphincter preservation have certainly demonstrated an indisputable better functional outcome, in terms of stoma avoidance and adequate continence

Introduction:

In recent years, intersphincteric resection (ISR) has been proposed to offer sphincter preservation in patients with very low rectal lesions, as an alternative to APR (1).

Intersphincteric resection of low rectal tumors is a surgical technique extending rectal resection into the intersphincteric space. This procedure is performed by a synchronous abdominoperineal approach with mesorectal excision and excision of the entire or part of the internal sphincter (2).

The principle of the ISR technique is based on the facts that rectal tumors expand into the visceral structures, i.e. proximally the rectum and distally the internal anal canal; and that there is an embryonic plane of fusion between the visceral structures and the surrounding somatic skeletal muscles of the pelvic floor. The aim is to remove the viscus without damaging the skeletal muscles (3).

*** Patients:**

This study has been conducted at Beni-Suef university hospital – Beni-SuefUniversity .

and diagnosed with low rectal cancer
(extraperitoneal) with clinical stages II (cT3-4, N0,
M0) and III (cT1-4, N+, M0)

*** Inclusion criteria:**

- 1- Low rectal cancer: distal tumor edge within 3-6 cm from the anal verge.
- 2- Disease stage: stage II and stage III .
- 3- Satisfactory preoperative sphincter function and continence

*** Exclusion criteria:**

- 1- Unsatisfactory preoperative sphincter function and continence .
- 2- Disease stage: stage I

*** Indications of ISR:**

- 1- Low rectal tumors: with distal tumor edge at a distance ranging from 3 to 6 cm from the anal verge.
- 2- Local spread restricted to rectal wall or internal anal sphincter (IAS) (i.e. T2).
- 3- Satisfactory preoperative sphincter function and continence.
- 4- Absence of distant metastases.

*** Contraindications of ISR:**

- 1- T4 lesions (tumors invading the visceral peritoneum or adjacent organs or structures: including puborectalis).
- 2- Unsatisfactory preoperative sphincter function and continence.
- 3- Tumors invading the external anal sphincter .

Accordingly, patients were categorized preoperatively as follows:

- a- Group A patients (10 patients) : who meet the criteria of ISR possibility and candidates for sphincter preserving procedures
- b- Group B patients (10 patients) : who didn't meet the criteria mentioned above to do ISR ,

were subjected to APR.

Methods:

- Preoperative concomitant chemoradiotherapy(CCRT):

Surgical Technique:

ISR candidates

:Total ISR involves complete excision of the internal sphincter. The cut line is at the intersphincteric groove. B. Subtotal ISR involves partial excision of the internal sphincter. The cut line is between the dentate line and the intersphincteric groove. C. Modified partial ISR the cut line is below the dentate line on one side of the tumor. On the opposite side of the tumor, the cut line is above the dentate line. .D Partial ISR the cut line is at or above the level of the dentate line(4)

Surgery was done after an interval period of about 6-8 weeks after the end of chemoradiation allowing the maximum response of CCRT to be obtained.

Surgical procedures (ISR for the 10 ISR candidates after CCRT were performed according to the methods described by Schiessel and his colleagues (5)

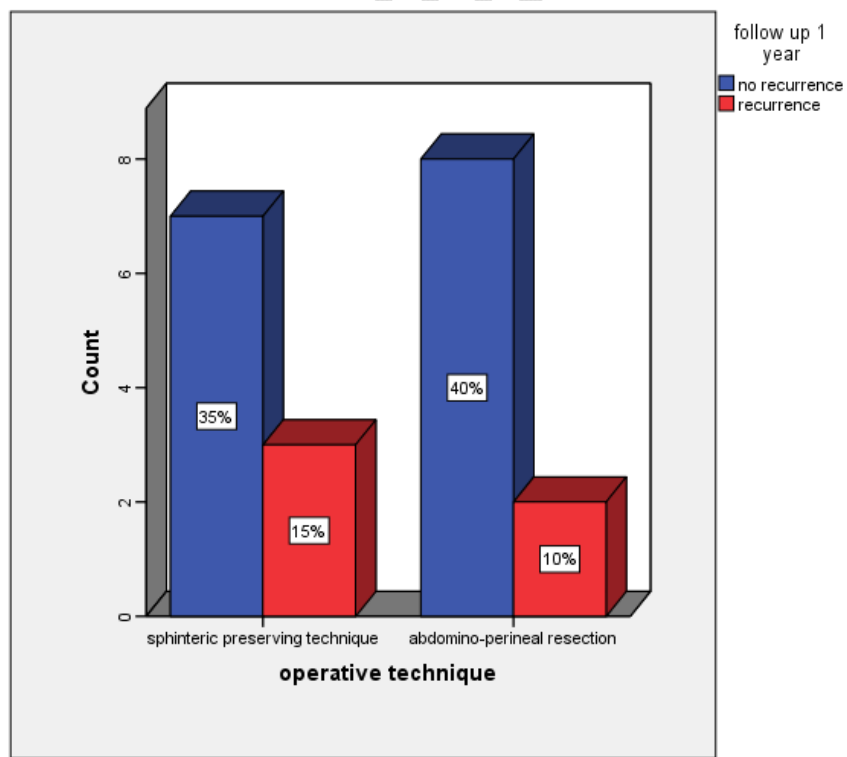
Results

Recurrence of malignancy (one year follow up)

Table 1 : Recurrence ratio

			operative technique		Total
			sphinteric preserving technique	abdomino-perineal resection	
follow up 1 year	no recurrence	Count	7	8	15
		% within operative technique	70.0%	80.0%	75.0%
		% of Total	35.0%	40.0%	75.0%
	Recurrence	Count	3	2	5
		% within operative technique	30.0%	20.0%	25.0%
		% of Total	15.0%	10.0%	25.0%

Fig 1Recurrence ratio



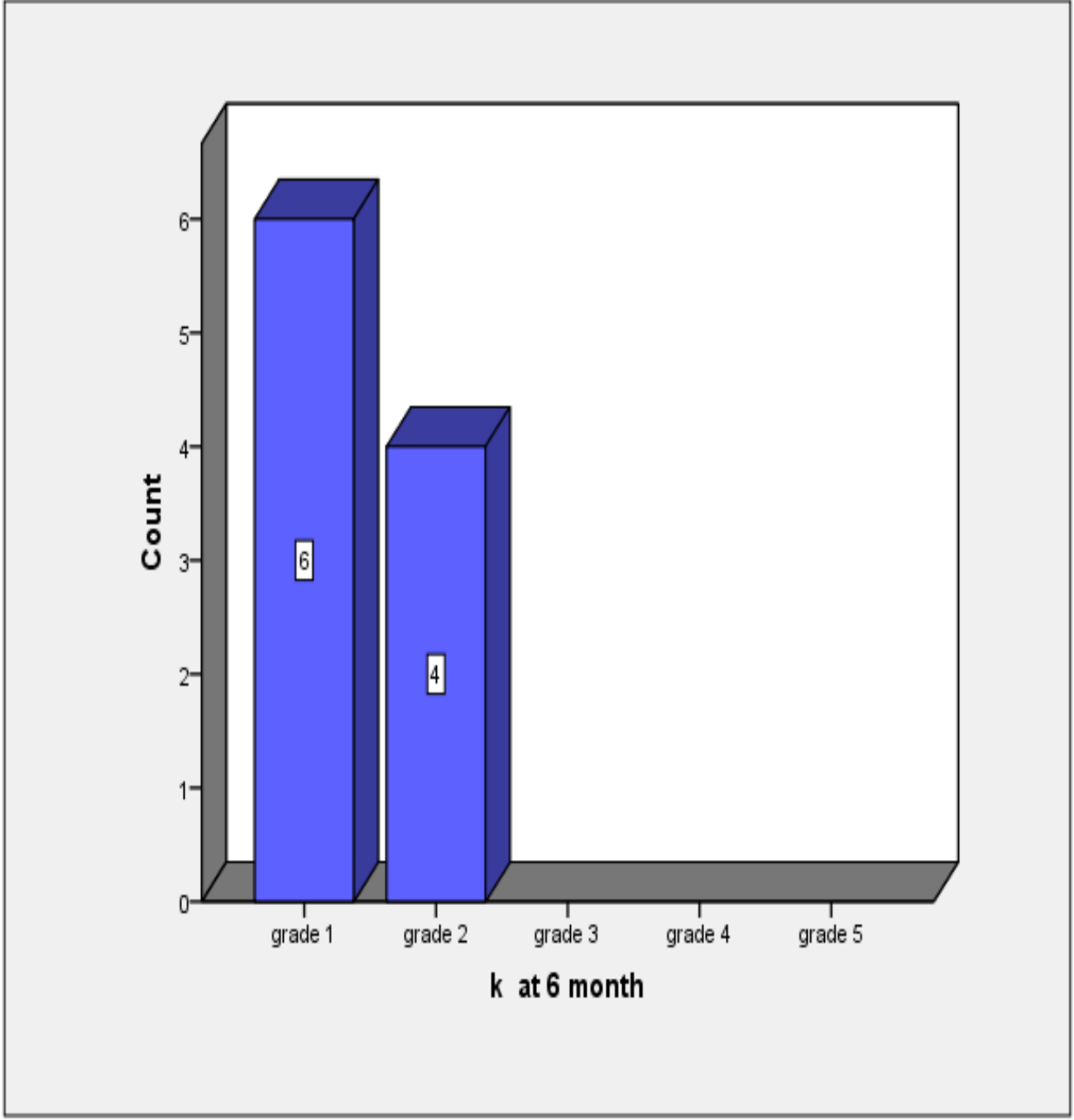


Fig. 2 : Continence grade according to kirwan's(6)

Discussion:

The main aim of the ISR technique is to provide a better quality of life keeping the patient continent compared to the permanent stoma in APR .

Assessment of the continence after ISR was done using Kirwan's grade mentioned above , and the results showed that after 6 months, out of 10 patients underwent ISR , 6 patients were highly satisfied with Grade I continence according to Kirwan's grade . While 4 patients were Grade II , i.e. : Incontinent to flatus . This result was not the same during the first 5 months owing to the presence of protective stoma which was usually closed within three months maximally and the patients needed a period for physiotherapy to regain their anal sphincter function ,this goes hand in hand with Gawad and his colleagues' study (7) , 70 %of patients were kirwan's grade one , 20% were Grade II , while 10 % were Grade 4 with frequent major soiling . The above mentioned results were obtained after 12 months post stoma closure .

Another subjective study conducted by Bujko (8 ,9) and his colleagues which included 100 patients after ISR who subjected into a questionnaire about the continence , anal stenosis , the need to use enema , feeling of incomplete defecation and the overall life quality reduction due to incontinence , the results should that that 44 % were highly satisfied with their life style after the operation , 38% reported slight reduction in their quality of life , while 18% reported a" very much reduction " in their quality of life according to their own words , **this was in contrast to our study.**

In our study , the follow up of the patients that was done every three months up to one year showed non significant recurrence rates between both groups of the

study. For the ISR group , 3 cases showed recurrence during the 1st year follow up postoperative period without distant mets, while 7 patients did not witness recurrence during this period . On the other side 2 out of 10 patients of the APR group showed local recurrence , one of them with distant mets . Our statistical data analysis showed insignificant p value ,this goes hand in hand with Gawad and his colleagues (7) who stated in their study that the recurrence rate of both compared group was also statistically insignificant (p = 0.107, and 0.948, for ISR and APR groups respectively) .

Conclusion : in low rectal cancer, the sphincter preservation appears to have nearly the same oncologic outcome compared to APR,. However, patients with sphincter preservation have certainly demonstrated an indisputable better functional outcome, in terms of stoma avoidance and adequate continence

References

- 1 - Taylor, F.G.M. et al., 2011. Preoperative high-resolution magnetic resonance imaging can identify good prognosis stage I, II, and III rectal cancer best managed by surgery alone: a prospective, multicenter, European study. *Annals of Surgery*, 253(4), pp.711–719
- 2-Schiessel, R. et al., 2005. Technique and long-term results of intersphincteric resection for low rectal cancer. *Diseases of the Colon and Rectum*, 48(10), pp.1858–1865.
- 3- Sanghera, P. et al., 2008. Chemoradiotherapy for rectal cancer: an updated analysis of factors affecting pathological response. *Clinical oncology (Royal College of Radiologists (Great Britain))*, 20(2), pp.176–83
- 4- Rullier, E.& Goffre, B., et al., 2001. Preoperative radiochemotherapy and sphincter-saving resection for T3 carcinomas of the lower third of the rectum. *Annals of surgery*, 234(5), pp.633–40

5-Roscurshim, I.G., Angelita Habr Gama., Rodrigo Oliva p., 2008.
Interval between surgery and neoadjuvant chemoradiation therapy
for distal rectal cancer : Does delayed surgery have an impact on
outcome ?. International Journal of radiation oncology,biology,
physics,71(4), pp.1181–1188

6 - Kirwan, R.P., Lian, L. & Lavery, I.C., 2011. Does a subcentimeter
distal resection margin adversely influence oncologic outcomes in
patients with rectal cancer undergoing restorative proctectomy? ,
Diseases of the Colon and Rectum. 54(2),pp. 157–163.

7 -GAWAD , I. FAKHR , M. LOTAYEF , O. MANSOUR , N. MOKHTAR , 2015 -3
Journal of the Egyptian national cancer institute
(2015) 27 , 19-24

8- Bujko, K. et al., 2012. Is the 1-cm Rule of Distal Bowel Resection Margin in Rectal
Cancer Based on Clinical Evidence? A Systematic Review. Annals of Surgical
Oncology, 19(3), pp.801–808.

9-Bujko, K. et al., 2006. Long-term results of a randomized trial comparing
preoperative short- course radiotherapy with preoperative conventionally
fractionated chemoradiation for rectal cancer. British Journal of Surgery, 93(10),
pp.1215–1223.