

Original Research Article

Central nervous system (CNS) manifestations in probable case of rickettsial infections in children in Central Karnataka.

Abstract

Introduction: Central nervous system (CNS) manifestations in children with rickettsial diseases are increasingly being reported from various parts of India but still rickettsial disease, as a cause of central nervous system (CNS) infections are underdiagnosed because of lack of freely available rapid and cheap diagnostic tests and varied clinical spectrum of rickettsial fever. **Objective:** To report CNS manifestations in probable case of rickettsial diseases so as to increase awareness amongst pediatricians. **Materials and Methods:** A retrospective analysis of children (birth to 18 years) hospitalized in Bapuji child health institute, which is secondary referral centre catering to children from five districts of Karnataka, with diagnosis of rickettsial disease from January 2016 to December 2018. The diagnosis of rickettsial infections was made by scoring system proposed by Rathi et al (Rathi Goodman Aghai scoring system), weil felix test, prompt response to doxycycline within 48 hours and exclusion of differential diagnoses. **Results:** Out of 278 patients, who were diagnosed as probable case of rickettsia, 172 patients had neurological involvement. Out of 172 patients with diagnosis of rickettsial disease having symptomatic neurological involvement, 148 (86%) had neurological manifestation as the main presenting feature while remaining presented with non-neurological manifestations of rickettsial diseases too along with neurological manifestations. The youngest patient was 3 month old infant. The various neurological manifestations seen were altered mental status (76%), irritability (61%), headache (48%), meningeal signs (32%), seizures (31%), papilloedema (26%), focal neurological deficits (18%), cerebrospinal fluid (CSF) abnormalities (76%) and neuroimaging abnormalities (28%). **Conclusions:** The myriads of neurological manifestations were seen with varying range of severity. Pediatricians should be aware of neurological manifestations seen in rickettsial infections and should have high index of suspicion for rickettsial diseases in febrile patients having neurological features specially in endemic areas.

Keywords: Rickettsia, Weil Felix, Papilloedema, Doxycycline

Abbreviation: CNS – Central nervous system, CSF – Cerebro spinal fluid, FLAIR – Fluid attenuated inversion recovery, DNA – Deoxy nucleic acid, ICMR – Indian council of medical research, RGA - Rathi Goodman Aghai, PCR – Polymerase chain reaction, ELISA – Enzyme linked immune sorbent assay

Introduction

Rickettsial diseases are one of the most incapacitating, covert, notoriously difficult to diagnose, reemerging infections of the present time reported from various parts of India and rest of the world. They present with fever, rash, edema, eschar, systemic features and various life threatening complications. The pharmacological therapy is easy and affordable with dramatic results and needs to be started on clinical suspicion, as there is no specific test for early

diagnosis¹. Variable prevalence (28–80%) of neurological manifestations in Rickettsial diseases are reported^{2,3}. Various clinicopathological syndromes seen are aseptic meningitis, acute encephalitic syndrome, meningoencephalitis, postinfectious demyelination and cerebral infarcts. We report a series of 172 probable case⁴ of Rickettsial diseases having symptomatic neurological involvement and fulfill the inclusion criteria.

Objective

To report **central nervous system** manifestations in probable case of rickettsial diseases so as to increase awareness amongst pediatricians **in central Karnataka**.

Materials and Methods

We conducted a retrospective review of children admitted in our center Bapuji Child Health & Research Institute, JJM Medical College, Davangere over a period of three years (from January 2016 to December 2018).

Inclusion criteria

- a) Children who were age less than 18 years
- b) Children with score more than 14 in RGA scoring system
- c) Children with neurological involvement (in the form of headache or irritability or seizures or altered mental status or meningeal signs or papilloedema or focal neurological deficits or CSF abnormalities or neuroimaging abnormalities)
- d) Children with defervescence of fever within 48 hrs of beginning of doxycycline treatment
- e) Children with positive weil felix test – a single titre above 1:80

Exclusion criteria

- a) Children with established alternative etiology of fever.

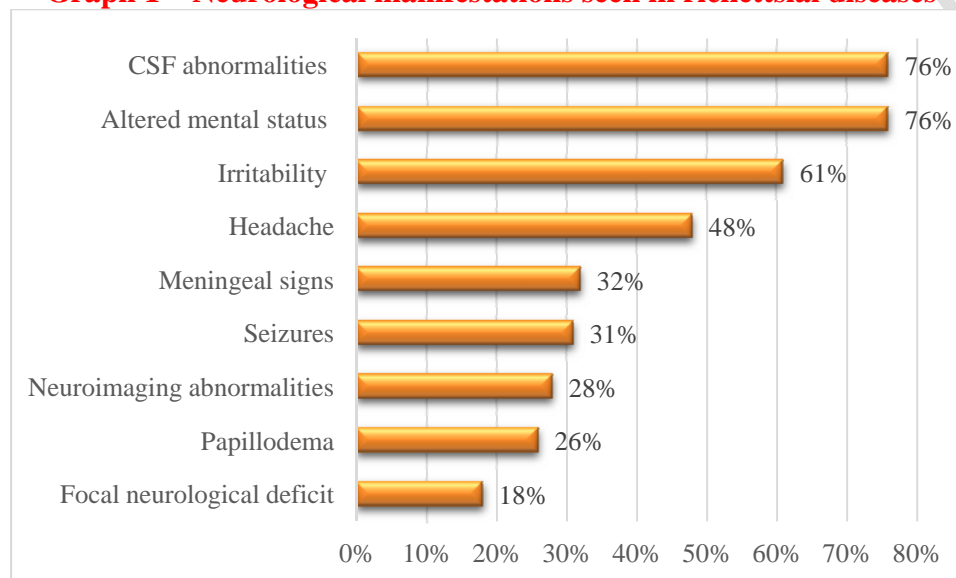
Out of 278 cases, a total of 172 patients were qualified for the review. Their clinical, CSF analysis and neuroimaging features were collected. The CSF analysis was done in all the cases but neuroimaging (MRI) was done in only 27 patients due to financial constraints. All cases were treated with oral or nasogastric doxycycline 5 mg/kg/day / I.V Azithromycin 10 mg/kg/day for 7–10 days. Other symptomatic therapies like antipyretics, IV mannitol, IV fluids and anticonvulsants were used as per the clinical scenario. Antibiotics, antimalarials and antivirals were started empirically at the time of admission in 48 (27%) patients, whose diagnosis was uncertain at initial presentation and were promptly withdrawn once the positive report. Various neurological manifestations were noted and their incidence was calculated. Patients having drowsiness, confusion, stupor, delirium or coma were classified as altered mental status. History of headache was elicited only in patients 6 years of age and above.

Results

Out of 278 patients of probable case of rickettsial infection, a total of 172 (61%) patients met the inclusion criteria. 112 (65%) patients had scrub typhus and 60 (35%) had spotted fever group Rickettsiosis. The youngest patient in our analysis was 3 months, who was referred as a

case of sepsis on day 5 of illness with fever, rash, anasarca and seizures. 145 (84%) patients responded well to therapy in 3 – 10 days with defervescence of febrile illness and complete recovery in neurological manifestations. 6 (3%) patients died inspite of therapy due to status epilepticus, ARDS and encephalitis respectively. 12 (6%) patients had persistent neurological deficit on discharge (gaze palsy, opsoclonus myoclonus syndrome and hemiparesis), all of which recovered completely within 8 weeks on follow up. Fever was seen in all patients. Various neurological findings were seen in varying severity as shown in Graph 1.

Graph 1 – Neurological manifestations seen in rickettsial diseases



Out of 53 patients with seizures, 9 had partial while 44 had generalized seizures (32 out of these 44 had status epilepticus). Out of 30 patients with focal neurological deficits, 14 patients had hemiparesis, 11 patients had 3rd cranial nerve palsy, 4 patients had 6th cranial nerve palsy and 1 patient had opsoclonus myoclonus syndrome. CSF abnormalities were seen in 130 (76%) patients and were in the form of mildly raised proteins (48–92 mg%) and pleocytosis of 100–500 cells / cu mm (lymphocyte predominance in 75% and polymorphonuclear predominance in 25% cases). The bacterial cultures on CSF were done which were found to be normal. Various neuroimaging abnormalities noted were meningeal enhancement, sulcal effacement, abnormal hyperintense signals in gray matter on T2 and FLAIR, cerebral infarct and compressed ventricular system suggestive of raised intracranial pressure. Late neurological sequelae like depression, behavioral disturbances, learning disability described earlier³ were not studied in this series.

Discussion

Neurological manifestations have long been recognized as complications of rickettsial infections and the word “typhus” itself comes from the Greek word whose meaning – hazy or smoky – is related to the mental status of affected individuals⁴. The CNS involvement in rickettsial diseases are secondary to systemic nature of disease and infective vasculitis caused by them but direct invasion is also documented⁵. Majority of patients have neurological involvement in the form of aseptic meningitis, meningoencephalitis, acute encephalitic

syndrome, cerebral infarct or post-infective demyelination like Guillain Barre syndrome or acute demyelinating encephalomyelitis⁶.

We are reporting a series of 172 patients of rickettsial diseases who had neurological involvement from southern India in Karnataka. 61% (172/278) of rickettsial diseases in children had neurological manifestations either at presentation or during the course of their hospitalization. Out of total 278 patients with rickettsial diseases, 46% (130) had CSF abnormalities, while CSF abnormalities were found in 76% (130/172) patients of rickettsial diseases who had symptomatic CNS involvement. The neurological involvement was seen at all ages, youngest being a 3 months infant. Four neonates were reported from Tamil Nadu, where neonatal sepsis was caused by Rickettsia and 2 of them had seizures⁷. The most common neurological manifestations encountered were headache, irritability and CSF abnormalities, while papilloedema was the rarest. One such study⁸, showed headache in 70%, seizures in 40%, meningeal signs in 30% and abnormal MRI in 100% cases. Another two studies^{9,10} showed headache in 90%, seizures in 17%, meningeal signs in 21% and abnormal MRI in 35% cases while comparable figures in our study were 48%, 31%, 32% and 28% respectively. The differences could be because they studied only Rocky Mountain Spotted Fever in former study and small sample size in the later study.

Limitations

As per the recent guidelines by ICMR, a confirmed case is one with rickettsial DNA detected in eschar samples or whole blood by PCR Or rising antibody titers on acute and convalescent sera detected by Indirect Immune Fluorescence Assay (IFA) or Indirect Immunoperoxidase Assay (IPA). Due to non availability of these confirmatory tests, RGA scoring system and Weil Felix test used as essential criteria for diagnosis. Further study is required to understand the long-term prognosis of the neurological abnormalities seen in these patients.

Conclusion

Rickettsial diseases can present with various neurological features of varying severity. Their diagnosis should be considered in cases of aseptic meningitis, meningoencephalitis and acute encephalitic syndrome associated with fever of short duration without an obvious cause, specially in endemic areas for these infections. CSF showing mildly elevated proteins and mild pleocytosis is compatible with diagnosis but low glucose level should prompt clinician to search for alternative diagnosis. Timely diagnosis prevents morbidity, mortality and lowers economic burden on patients for unnecessary diagnostic workups and unwarranted therapies

References

1. Rath N, Rath A. Rickettsial infections: Indian perspective. Indian Pediatr. 2010;47:157–164.
2. Rath N, Rath A, Goodman MH, Aghai ZH. Rickettsial Diseases in Central India: proposed clinical scoring system for early detection of spotted fever. Indian Pediatr. 2011;48:867–872.

3. Dass, R, Deka, NM, Duwarah, SG. Characteristics of pediatric scrub typhus during an outbreak in the north-eastern region of India: peculiarities in clinical presentation, lab findings and complications. *Indian J Pediatr* 2011; 78: 1365–1370.
4. Rathi N, Kulkarni A, Yewale .IAP Guidelines on Rickettsial Diseases in Children. 2017;54:223-229.
5. Thomas R, Puranik P, Kalal B, Britto C, Kamalesh S, Rego S, *et al*. Five-year analysis of rickettsial fevers in children in South India: Clinical manifestations and complications. *J Infect Dev Ctries* 2016;10:657-61.
6. Jena, SS, Mathew, A, Sanjith A. Cerebral venous sinus thrombosis presentation in severe scrub typhus infection: A rare entity. *Neurol India* 2014; 62: 308–310.
7. Sood AK, Chauhan L, Gupta H. CNS manifestations in Orientia tsutsugamushi Disease in North India. *Indian J Pediatr*. 2016;83:634.
8. Arthi P, Bagyalakshmi R, Krishna M, *et al*. First case series of emerging Rickettsial neonatal sepsis identified by PCR based DNA sequencing. *Ind J Med Microbiol*. 2013;31(4):343–348.
9. Kelsey I, Sumit P, Karen B, *et al*. Neurologic manifestations of RMSF in children and adults. S208. *OFID*. 2014;1(Suppl. 1). Poster Abstracts.
10. Rathi N, Maheshwari M, Khandelwal R. Neurological manifestations of rickettsial infections in children. *Pediatric Infectious Disease*. 2016;7:64-6.