

Effects Of Methanolic Root Extract Of *Holarrehna floribunda* On Liver Enzymes and Histopathology of the Ovaries and testes Tissues In Wistar Rats.

ABSTRACT

Aim: This study was conducted with the aim of investigating the effects of methanolic root extract of *Holarrehna floribunda* on serum activities of some liver enzymes and histopathology of the ovaries and testes tissues of the rats .

Methods: Twenty- four male and female Wistar rats (150-250g body weight) were randomly assigned into four groups of 6 rats each. Group 1 (Control male) had taken normal rat chow and drinking water. Group 2 (Control female) had taken normal rat chow and drinking water, Group 3 (Male test group), was administered with 200 mg/kg of *Holarrehna floribunda* extract, Group 4 (Female test group), was administered with 200 mg/kg of *Holarrehna floribunda*, Group The feeding had regimens lasted for 5 weeks.

Results:The effects of administrating the extract on the serum enzymes, revealed the activity of ALT in Group 1 is 28.60 ± 2.71 U/L and Group 3 is 29.20 ± 1.43 U/L while for Groups 2 and 4 were 34.00 ± 0.00 U/L and 32.86 ± 2.87 U/L, There was significant decrease ($p < 0.05$) in ALT between group 2 and 4 and no significant increase ($p < 0.05$) between Group 1 and Group 3. The values of AST obtained in Group 1 is 53.00 ± 1.87 U/L and Group 3 is 33.40 ± 2.60 U/L, Group 2 and 4 were 38.00 ± 2.50 U/L and 35.43 ± 1.91 U/L. There was significant decrease ($p < 0.05$) between Group 2 and Group 4 and a increase between Group 1 and Group 3.

The histological integrity of the testes and ovary had been examined. Results revealed that for the tissues of the testes, there was no evidence of histological distortion; the oocytes and the follicles were normal. While in the extract administered group, there were large number of Leydig cells present in between the seminiferous tubules.

Conclusion: This present study exhibited that the extract has no toxic effect on the liver-. The histologic results showed no disorganization and degeneration in the ovary and testes. These results can help to explain why *Holarrehna floribunda* might be used in improving sterility/fertility disorders of women.

Key words: Histopathology, liver enzymes, histological distortion, oocytes, ovaries and testes tissues

1. Introduction

Globally, infertility affects about 50 to 80 million couples at some point of their reproductive lives with a variety of biological and behavioral determinants. A variety of the plants are claimed to have fertility regulating properties and a few have been tested for such effect [1,2,3,4], *Holarrehna floribunda* is one of these plants. Various medicinal plants ranging from

Quassiaamara, [5,6,7,8], Garcinia kola, [9] and Vernonia amygdalina, [10] have been implicated in male infertility. Fortunately, several countries in the world are endowed with plant biodiversity, and there is currently an awareness about the significance of plant remedies in health care delivery system. In many parts of the world, efforts are now being aimed at investigating therapeutic efficacy of locally available medicinal herbal plants. The beneficial role of medicinal plants in the treatment of female infertility has been numerously indicated.

^{The} ✓ Phytochemicals are **the** biochemical compounds formed during **the** normal metabolic processes **of plants**. These substances are often referred to as “secondary metabolites”. There are several classes of phytochemicals including; alkaloids, flavonoids, coumarins, glycosides, gums, polysaccharides, phenols, tannins, terpenes and terpenoids [11]. Phytochemicals can act as agents that prevent undesirable side effects of the main active substances or assist in the assimilation of the main substances [12].

^{The} ✓ Phytochemicals are found in a variety of **plants, including** an important component of either human or animal diets. Such plants may include fruits, seeds, herbs and vegetables [13]. Contrary to **the** synthetic pharmaceuticals based upon **the** single chemicals, many medicinal and aromatic plants exert their health beneficial effects through the synergistic action of **the** several chemical compounds acting at single or multiple target sites associated with a biochemical or physiological process. These synergistic pharmacological effects can be beneficial by eliminating the problematic side effects associated with the predominance of a single xenobiotic compound in the body [14].

———The additive interactions that underlie the effectiveness of a number of phytomedicines have been extensively documented [15]. Most of these phytochemical constituents are potent bioactive compounds found in medicinal plant parts which are precursors for the synthesis of

useful drugs [16] and in-depth knowledge of such composition in a plant can aid in its wider and efficient exploitation for medicinal purposes.

Traditional medicine of this same Africa region indicates that the root extract of *Holarrhena floribunda* is used to stimulate fertility, solve stomach upset and use as a pain relief substance. Although there is no scientific evidence to support the ethnopharmacological efficacy of *Holarrhena floribunda* on female reproduction, tribes continue to popularise the use in the management of the cases of sterility/infertility in women. In Nigeria, the root of *Holarrhena Floribunda* is employed traditionally in the treatment of Malaria, diarrhea, dysentery, fever, pains, female sterility, skin infections, venereal diseases, cancer and snake bite [17]. The use of the root of this plant in the treatment of the mentioned diseases have not been studied scientifically hence the need for this kind of research.

2. Methods

2.1. Identification and preparation of plant materials

^{The} ✓ Fresh roots of *Holarrhena floribunda* was collected from local garden at the University of Uyo, Uyo, Akwa Ibom State, Nigeria. The sample of the plant specimen was identified and authenticated by a ^b Botanist from the botanic garden, and the voucher specimen with identification number (PES/Herb/uc/129) was deposited in the Herbarium of the University of Calabar. The roots were sorted to eliminate any dead matter and other unwanted particles. The roots of *Holarrhena floribunda* were washed with clean water, cut into pieces and dried under shade at a temperature of $25 \pm 0.5^{\circ}\text{C}$. Mortar and pestle were used to pulverize the root until it formed a coarse powder. ^a And the methanol extracts were obtained by soxhlet extraction of the powder. The extracts were concentrated to the dryness in vacuo at 40°C . The dried extracts were weighed, ^{an} stored in specimen bottles and kept in the refrigerator at -4°C until used. ^a ✓ Appropriate

concentration of the extract ^{that} will be subsequently made by dilution with distilled water and administered to the animals. ^a

2.2. Handling and treatment of animals

Twenty four (24) adult male and female albino rats weighing between 150-250 grams obtained from the disease free stock of the animal house. The study had been performed at the Department of Biochemistry, College of Medical Sciences University of Calabar, Calabar Nigeria. The rats were divided into four groups of six rats each (Table 1). The rats were acclimatized in the experimental Animal House for one week before the commencement of the experiment. The animals were housed in stainless steel cages under standard conditions (ambient temperature, $28.0 \pm 2.0^\circ \text{C}$ and humidity, 46%, with a 12 hr light/dark cycle), fed with the normal rat pellets. All the rats in both test and control groups are allowed free access to feed and water *ad libitum*, throughout the experimental period. Good hygiene maintained by constant cleaning and removal of faeces and spilled feed from cages daily. The extract had been administered for 40 days.

TABLE 1

Animal groupings

Groups	Number of animals	Treatment
1. (Control Male)	6	Distilled Water

2. (Control Female)	6	Distilled Water
3. (Male 200mg/kg)	6	Root extract of HF
4. (Female 200mg/kg)	6	Root extract of HF

Group 1 (Control male group received distilled water as placebo),

Group 2 (Control female group received distilled water as placebo),

Group 3 (Test group male received oral dose of *Holarrhena floribunda*),

Group 4 (Test group female received oral dose of *Holarrhena floribunda* root extract).

2.3. Collection of blood and tissues for analyses

All the animals were anaesthetized in chloroform vapour, twenty-four (24) hours after the last day of extract administration, and dissected for blood collection. The Blood samples was collected by cardiac puncture into a set of plain sample bottles, allowed to clot for 2 hours after which serum was obtained by centrifugation at 3000 rpm. Serum was used for biochemical estimations. The testes and ovaries were obtained and fixed in 10% formaldehyde solution for further processing and histological examination.

2.4. Biochemical estimations

Biochemical analysis which included estimation of serum activities of liver enzymes-alanine aminotransferase and aspartate aminotransferase had been carried out according to the method described by Reithman and Frankel (1957).

2.5. Statistical analysis

~~the~~ Results obtained from ~~this~~ ^{the present} study was analyzed by one-way analysis of variance (ANOVA), followed by Student's t-test to evaluate the significance of the difference between the mean value of the measured parameters in the respective test and control groups using SPSS windows. A significant change was considered acceptable at ~~P~~ ^P < 0.05.

3.0. Results

The ~~Result~~ ^s, exhibiting the comparison of weekly body weight changes of animals in the respective groups were ~~summarize~~ ^{summarized} in the graph below ~~.~~ ^{the}

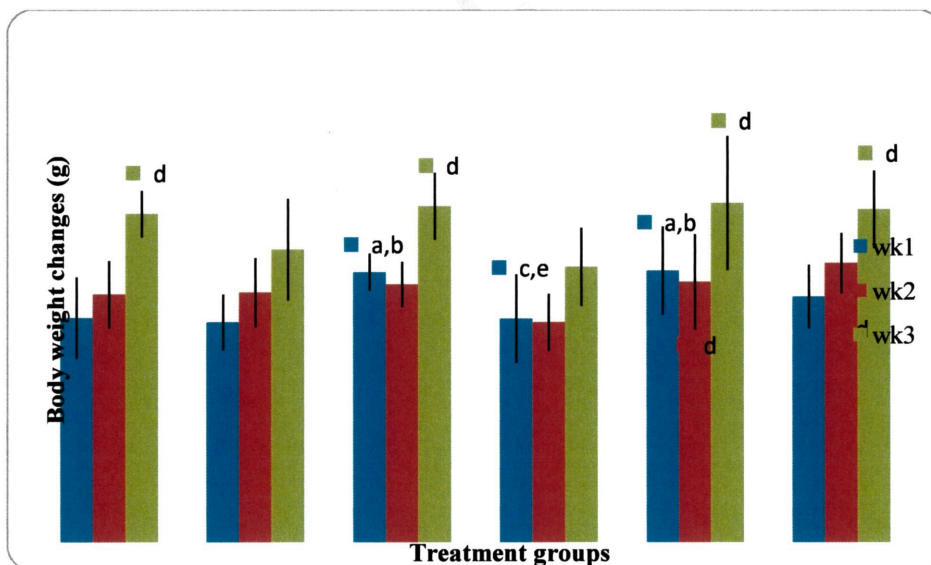


Figure ??
Figure legend ?

The Comparison of weekly ^{the} body weight changes of animals in the respective groups. The Values are presented as mean ± SEM; n = 6; a = p>0.05 vs C; b = p>0.05 vs FC; c = p>0.05 vs MT; d = p>0.05 vs FT; e = p>0.05 vs MFC

3.1. Effects of administration of *Holarrhena floribunda* root extract on liver enzymes

The Result of the effect of administration of *Holarrhena floribunda* root extract on the liver enzymes in the respective groups were summarized on Table 2. The Values obtained exhibits the activity of ALT (U/L) in Groups 1 and 3 were 28.60±2.71U/L and 29.20±1.43U/L while for Group 2 and 4 were 34.00±0.00U/L and 32.86±2.87U/L respectively. There was no significance difference (p>0.05) in ALT between Groups 2 and 4 and no significant increase (p>0.05) between 1 and 3. The values of AST (U/L) obtained from Table 2 shows Group 1 and 3 were 35.00±1.87U/L and 33.40±2.60U/L respectively, Group 2 and 4 were 38.00±2.50U/L and 35.43±1.91U/L difference respectively. There was no significant (p<0.05) decrease between group 2 and 4 and a slight increase between 1 and 3.

3.2. The Results of the effect of administration of *Holarrhena floribunda* root extract on the liver enzymes in the respective groups

Table 2

	ALT (U/L)	AST (U/L)
Group 1 MC	28.60±2.71	35.00±1.87
Group 2 FC	34.00±0.00	38.50±2.50
Group 3	29.20±1.43 ^a	33.40±2.60 ^a

MT

Group 4	32.86±2.87 ^b	35.43±1.91 ^b
FT		

The values expressed as mean ± SEM, significant at $p < 0.05$. ^a insignificant at $p < 0.05$ compared with group 1 (Male control), ^b insignificant at $p < 0.05$ compared with Group 2 (Female control). MC = male control group; FC = female control group; MT = male test group; FT = female test group.

3.3. The effect of administration of *Holarrhena floribunda* extract on the histology of testes and ovarian tissues

Figure 1: A Photomicrograph of testis of male control (MC) group surrounded by a thick capsule called tunica albuginea (Basement membrane). Normal appearance of the spermatozoa with no visible histopathologic distortion ^{observed} seen.

Figure 2: A Photomicrograph of the ovary of female control (NC) group revealed normal appearance of the oocytes surrounded by epithelial cells. The section, exhibiting an outer region called cortex (top arrow head) and an inner portion called medulla (big arrow). The portion of these two components varies according to age. No histopathologic are observed.

Figure 3: A Photomicrograph of male testes of *Holarrhena floribunda* (HF)- treated group with 200 mg/kg body weight of extract, exhibiting normal appearance of testes surrounded by a basement membrane which is still intact. Huge amount of Leydig cells present in between the seminiferous tubules. No visible histopathologic abnormality.

Figure 4: A photomicrograph of female ovary of *Holarrhena floribunda* (HF)- treated group, treated with 200 mg/kg body weight of the extract shows ovarian section with follicles seen in

the cortex. Equally seen are oocytes that are surrounded by epithelial cells that form the follicles. No disorganization or degeneration are observed.

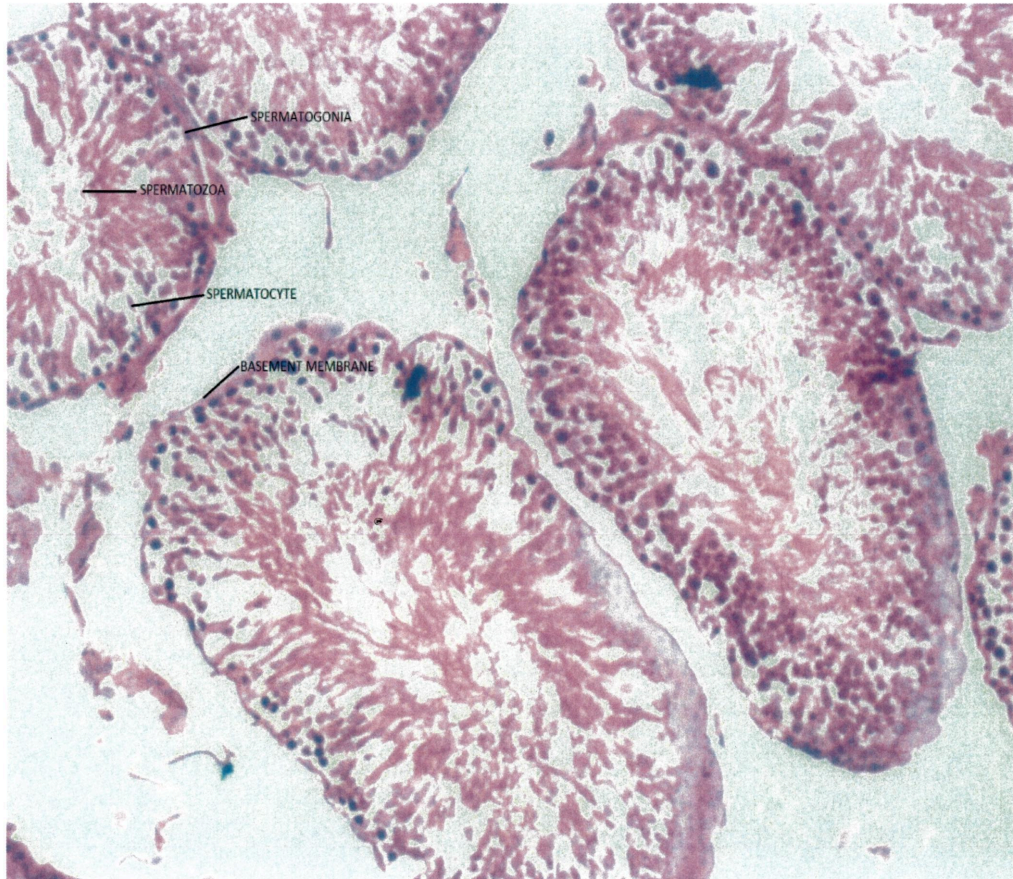


Figure 1: A Photomicrograph of the testis of male control (MC) group.
(Original Magnification, $\times 100$, Haematoxylin & Eosin) staining

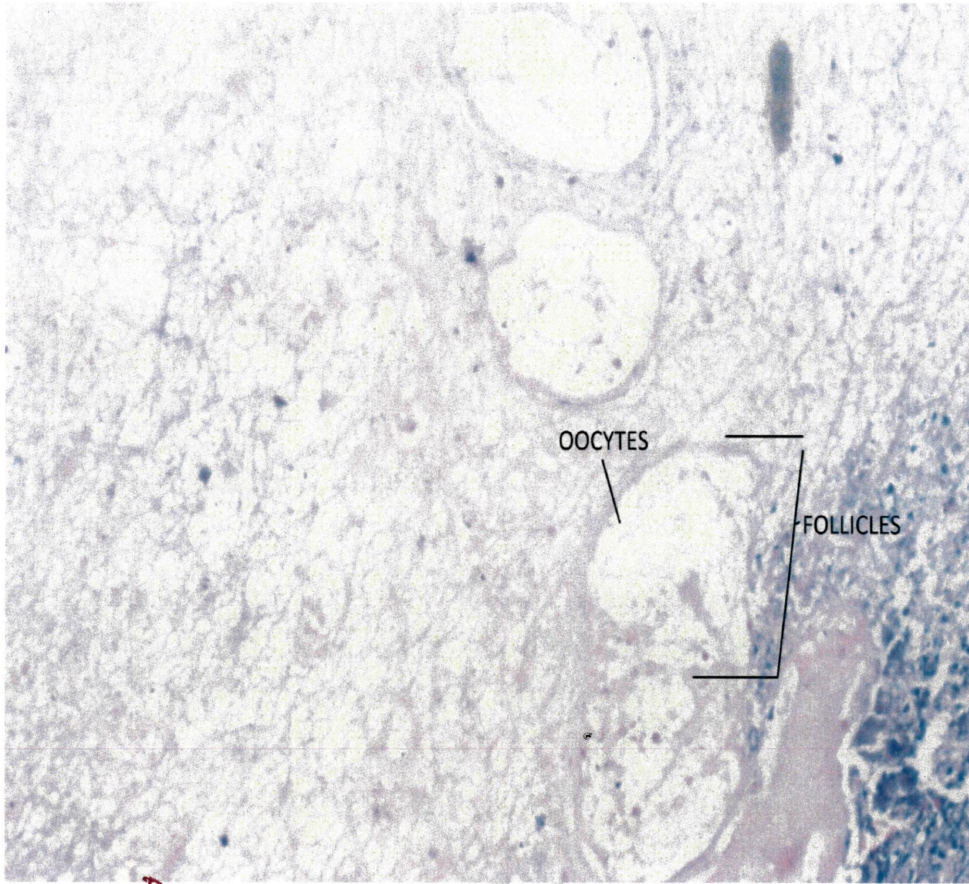


Figure 2: A Photomicrograph of the ovary of female control (FC) group (Original Magnification, x 100, Haematoxylin & Eosin staining).

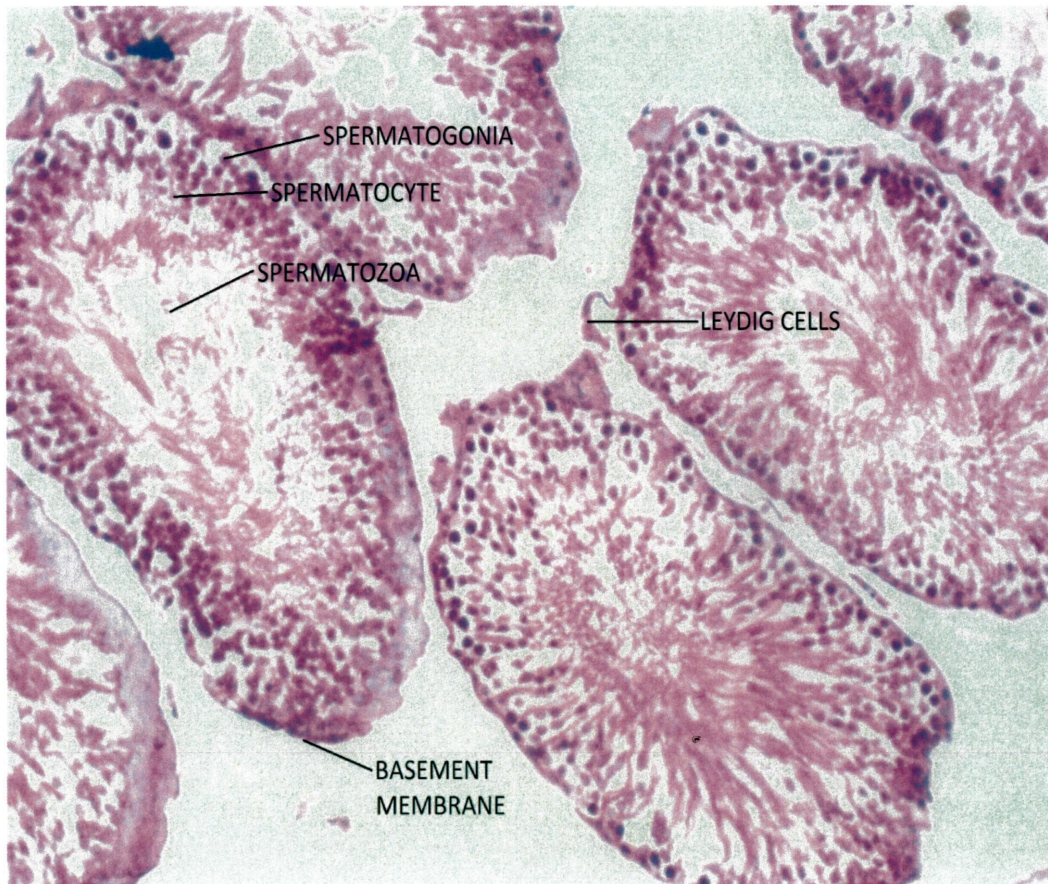


Figure 3: A Photomicrograph of male testes of *Holarrhena floribunda* (HF)-treated group with 200 mg/kg body weight of the extract, (Original Magnification, x 100, Haematoxylin & Eosin staining).

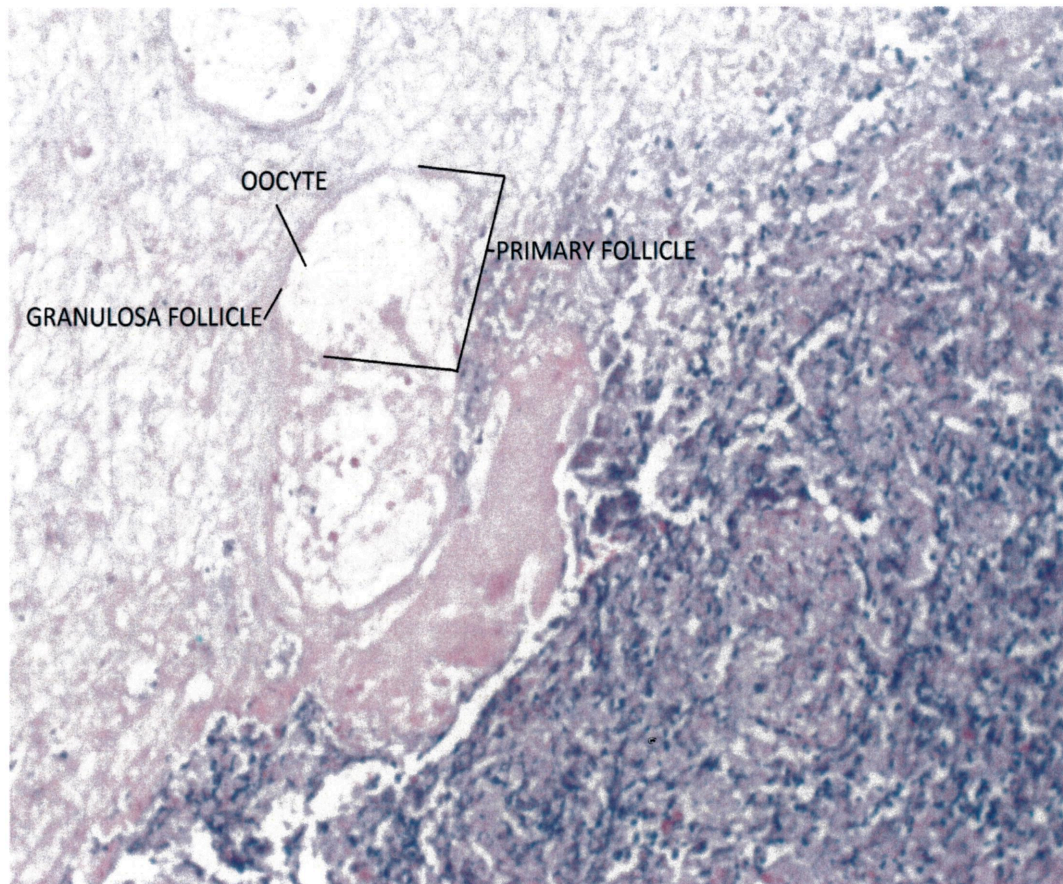


Figure 4: A Photomicrograph of female ovary of *Holarrhena floribunda* (HF)-treated –group with 200 mg/kg body weight of the extract (Original Magnification, x – 100, Haematoxylin & Eosin-staining) .

4. Discussion

The aim of the present study is evaluating the effects methanolic root extract of *Holarrhena floribunda* on serum activities of some liver enzymes and histopathology of the ovaries and testes of rats. Serum enzyme levels are the most commonly used biochemical tools for the assessment of the hepato-cellular injury whereas increase in amino transferases (ALT and AST) generally reflects liver cell damage. That of ALP is more specific for cholestasis. Free radical induced lipid peroxidation of cellular membrane alters membrane integrity leading to increased membrane permeability and loss of cellular content into the circulation. The extract reduced the levels of AST and ALT in Groups 1 and 3 while for Groups 2 and 4. The values of AST shows

?
↓
?

Groups 1 and 3 and Groups 2 and 4 were indications of its non toxicity and protective activity of this extract.

reverse
this
sentence

Effect of administration of *Holarrhena floribunda* extract on the histopathologic architecture of testes and ovary tissues showed that the extract improved the level of sex hormones in both the male and female rats [18]. The histopathologic and/or architectural integrity of the testes and ovary tissues in the experimental groups ^{had been} were examined and compared with the controls. ^{the} Results revealed no evidence of histopathologic distortion of the testes for the controls, because ^{the} cross sections of the testes tissues showed a preserved architecture of the seminiferous tubules and basement membrane. For female control ovary, ⁺ The oocytes and the follicles were normal. In the extract administered groups where the testes showed the normal histological appearance surrounded by the basement membrane, indicating that they were intact. There were large number of leydig cells present in between the seminiferous tubules. There was no histopathologic abnormality in the female treated group, ⁺ The ovary and the follicles were ^{in a} normal. From the results obtained in this research, ^{it} showed that the extract improved the level of sex hormones in both the male and female rats and the extract treated rats showed non toxicity.

5. Conclusion

In conclusion, *Holarrhena floribunda* methanol root showed no toxic effect on the liver. There was increased in body weight changes. The histopathologic results showed no disorganization and degeneration in the ovary and testes. These results can help to explain why *Holarrehna floribunda* might be used in improving sterility/fertility disorders of women.

the

ETHICAL APPROVAL

Authors received ethical approval according to international /university standard.

COMPETING INTERESTS

All the Authors have declared that no competing interests.

REFERENCES

- [1] Baker VA, Hepburn PA, Kennedy SJ. Safety of phytosterol esters. Part 1. Assessment of oestrogenicity using a combination of *in vivo* and *in vitro* assays. *Food Chemical Toxicology*.1999; 37 (1):13–22.
- [2] Telefo PB, Moundipa PF & Tchouanguép FM. Oestrogenicity and effect on hepatic metabolism of the aqueous extract of the leaf mixture of *Aloe buettneri*, *Dicliptera verticillata*, *Hibiscus macranthus* and *Justiciainsularis*. *Fitoterapia*.2002;73 (1):472–478.
- [3] Cherdshewasart W, Kitsamai Y& Malaivijitnond S. Evaluation of the estrogenic activity of the wild *Puerariamirifica* by vaginal cornification assay. *Journal of Reproductive Development*.2007; 53 (2):385–393.
- [4] Ganguly M, Borthakur M, Devi N. & Mahanta R. Antifertility activity of the methanolic leaf extract of *Cissampelospareira* in female albino mice. *Journal of Ethnopharmacology*. 2007; 111 (1):688–691.
- [5] Raji Y & Bolarinwa, AF. Antifertility activity of Quassiaamara in male rats-in vivo study. *Journal of Life Science*.1997; 61 (1): 1007-1014.
- [6] Ratnasooriya WD & Dharmasiri MG. Effects of *Terminalia catappa* seeds on sexual behaviour and fertility of male rats. *Asian Journal of Andrology*.2000; 8 (2): 115-121.
- [7] Reznikoff-Etievant MF, Zittoun J, Vaylet C, Pernet P. & Milliez, J. Low vitamin B12 level as risk factor for very early recurrent abortion. *European Journal of Obstetrics Gynecological Reproductive Biology*.2002 ; 104 (1):156–159.
- [8] Raji Y, Oloyo AK, Morakinyo AO.Effect of methanol extract of *Ricinus communis*seed on reproduction of male rats. *Asian Journal of Andrology*.2006; 8 (2): 105-111.

- [9] Akpantah AO, Oremosu AA, Ajala M, Noronha CC, Okanlawon CC. The effect of crude extract of garcina kola seed on the histology and hormonal milieu of male Sprague Dawley rats' reproductive organs. *Nigerian Journal of Health Biomedical Sciences*. 2003; 2 (1): 40-46.
- [10] Oyeyimi MO, Ajala OO, Leigh OO, Adesiji TF. The spermiogram of Wistar rats treated with aqueous leaf extract of Vernoniaamygdalina. *Proceedings of the 44th annual congress of the Nigerian Veterinary Medical Association*. 2008; Delta, pp: 89-92.
- [11] Okwu DE. Evaluation of the chemical composition of indigenous species and flavouring agents. *Journal of Science*. 2004; 6 (1): 30-75.
- [12] Anonymous. Medical, culinary and aromatic plants in the near East-Medic. 2007; <http://www.fao.org/dorep/x5402e16.htm>.
- [13] Okwu DE & Josiah C. Evaluation of the chemical composition of two Nigeria medicinal plants. *African Journal of Technology*. 2006; 5(4): 357-361.
- [14] Tyler VE. Phytomedicines: back to the future. *Journal of Natural Product*. 1999; 62 (1): 1589-1592
- [15] Kaufman, P. B., Cseke, L. J., Warber, S., Duke, J. A. & Brielmann, H. L. (1999). — *Natural products from plants*. CRC press, Boca Raton. p 36-76.
- [16] Sofowora A. Screening plants for bioactive agents. In: *Medicinal plants and traditional medicine in Africa*. 2nd Ed. Ibadan, Nigeria: Spectrum Books Ltd. 1993; 159-177. ed. P? PP?
- [17] Burkill H M, The useful plants of West Tropical Africa. *Kew Royal Botanic Gardens*. 1997; 4: 59-103. (?)
- [18] Dennis A, Udosen EO, Ekam VS, and Ekpe IP. Effects of Methanolic Root Extract of Holarrhena floribunda on the Lipid Profile and Sex Hormones in Wistar Rats. *Asian Journal of Research in Biochemistry*. 2018; 3(3): 1-7