

## **Original Research Paper**

### **Incidence of pulmonary papillary carcinoma in lungs of dromedary camels affected with pneumonia for the first time in Sudan**

#### **Abstract:**

**Aims:** To study the pathology of lung tissue affected with tumors and isolate, identify the bacteria associated with these tumors in dromedary camels in Sudan to investigate the relationship between tumor and bacteria.

**Study Design:** 45 lung samples of camels slaughtered at Tambool abattoir, Al-Gazeera state in Sudan of age ranging between 10-15 years, were subjected to pathological and bacteriological studies using standard methods.

**Place of Study:** This study was undertaken in the Departments of Pathology and Bacteriology, Central Veterinary Research Laboratories, Ministry of Animal Resources and Fisheries, Khartoum during 2015.

**Methodology:** The isolates were characterized using different techniques: conventional, Api kits and automated system Vitek 2 Compact. In histopathological method portions of Lungs tissues were fixed in 10% formalin, processed by standard method for paraffin wax embedding, 5 micron sections were cut and stained with hematoxylin and eosin (H and E).

**Results:** Four out of 45 lung samples (8.9%) were diagnosed as pulmonary papillary carcinoma. The most striking changes were complete obliteration of lungs tissues architecture, which were replaced with papillary fibrovascular projections with complex secondary and tertiary branches. The cells lined projections were found in clumps with indefinite borders and mostly overlapping each other. The nucleoli of these cells showed atypia with vesicular nucleoli forming empty glass appearance, with dark nucleoli, psammoma bodies were identified in all cases and were often associated with the papillary component, either within

fibrovascular cores or lining epithelium, infiltration of mononuclear cells, haemorrhage, necrosed detached tumor cells, and odema was detected in the affected lungs.

In this study *Strep suis* (*S. suis*), *Bacillus* and *Staph aureus* (*S. aureus*) were isolated from lungs affected with papillary carcinoma, the isolation of these bacteria may have an importance in the future studies to determine the relationship between bacteria and such tumor.

Conclusion: the current study considered to be the first report for occurrence of pulmonary papillary carcinoma in dromedary camel in Sudan.

Key words: *Bacteria, Carcinoma, Dromedary, Camel, Tumor, Sudan*

## 1. Introduction

Although neoplastic conditions are rare reported in camels it is supposed that Camelids are susceptible to all the various tumor types that affect domestic animals. The previous publications in cancer of camel were; cutaneous papillomatosis associated with papilloma virus in dromedaries was published in 1990 in central Somalia, cases of papillomatosis in Kenya, United Arab Emirates, Sudan, Saudi Arabia and in eastern Sudan [1], Squamous cell carcinoma of the foot and chondrosarcoma of the left carpal joint in camels by [2]. A general report of neoplasia in camels [3] and a basal cell carcinoma in a dromedary camel [4], toenail tumors in the dromedary camel [5]. Four types of mammary neoplasia in the dromedary camel were reported by [6]. In lung cancer of camel there were few studies like; Mammary and pulmonary carcinoma in dromedary camel by [7] and Pulmonary Leiomyoma in a Dromedary [8].

Tumors are classified as either benign or malignant, according to their appearance and behavior. Tumor nomenclature is based on histological and behavior patterns. Histology provides information about the type of cell from which the tumor has arisen, whereas

behavior provides information as to whether the cell is benign or malignant [9]. Benign tumors are usually well differentiated, localized that do not invade the surrounding tissues or metastasize to other organs. Metastasis is the process whereby malignant cells spread from their site of origin (a primary tumor) to distant sites and grow into secondary tumors. Malignant tumors are capable of invasion and spread to distant organs. This distinction is crucial in the clinic because metastatic disease is associated with significant morbidity and mortality. Malignant neoplasms can show a range of differentiations [9]. There are four main routes of metastasis, these are: local invasion which is the most common pattern of spread of malignant tumors by direct growth into adjacent tissues, lymphatic spread by forming secondary tumors in lymph nodes, blood-borne (haematogenous) spread in which the cells enter the bloodstream and form secondary tumors in organs perfused by blood that has drained from a tumor and transcoelomic spread in pleural, pericardial and peritoneal cavities [9].

Metastatic lung tumors are the most common and they result from displacement of malignant cells from a primary site to lymph vessels or veins, reaching the pulmonary circulation and lung tissue [10].

The development of cancer is associated with several genetic and environmental factors. Furthermore there has been an association between the development of cancer and bacterial and viral infections for decades. Several viruses can integrate into the human genome and directly initiate tumorigenesis, such as human papillomavirus (HPV) in cervical cancer and herpesvirus in Kaposi's sarcoma [11, 12]. In other cases, the development of cancer is indirect, such as with *Helicobacter pylori*, which contributes to both gastric cancer and mucosa-associated lymphoid tissue (MALT) lymphoma due to chronic inflammation caused by the bacteria [13, 14].

Numerous studies have reported different indigenous bacterial species being isolated from infected lesions in patients[15,16]. As early as 1868 Bush reported 2 patients with sarcoma that had been infected with *Streptococcus* spp[10]

## **2. Material and methods**

### **2.1. Collection of samples**

45 pneumonic lungs samples were collected aseptically for bacterial isolation and identification, each in a sterile plastic bag and transported immediately on ice to the bacteriology department for isolation and identification of bacteria, another sample from each lung was impregnated in 10% formalin for pathological studied.

### **2.2. Cultural procedure**

Different types of media were used for isolation of the bacteria from the specimens collected. Those were: nutrient agar, blood agar, brain heart infusion, mannitol salt agar. The surface of each lung sample was cauterized with a red hot scalpel blade for decontamination. A deep incision was then made in each lung surface using sterile scalpel blade; a sterile swab was dipped into the incised area and streaked onto sheep blood agar plate. The cultures were incubated at 37 °C for 24 hours.

### **2.3. Identification of bacterial isolates:**

Different procedures were used to identify the isolates using conventional, Api kits and full automated system, Vitek 2 Compact.

### **2.4. Characterization of the isolates using API kits:**

For isolate with the Api kits, the organisms were sub-cultured on blood agar plates, each separately and after incubation for 24 hours at 37 °C, for staph and strep Gram stain and catalase test were performed, then colonies from each fresh culture, were emulsified in Api medium and adjusted visually to 0.5 and

4respectively MacFarland opacity tube that was prepared by adding 0.05 of 1.0% barium chloride to 9.95 of 1.0% sulfuric acid according to the type of kit.

### **2.5.Characterization by the Vitek 2 compact:**

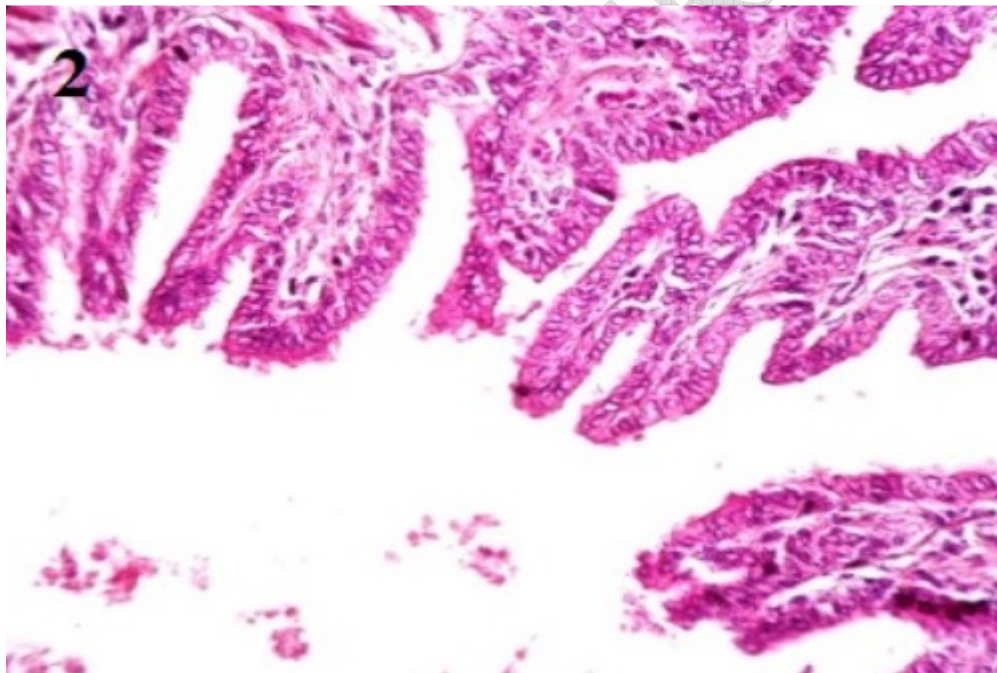
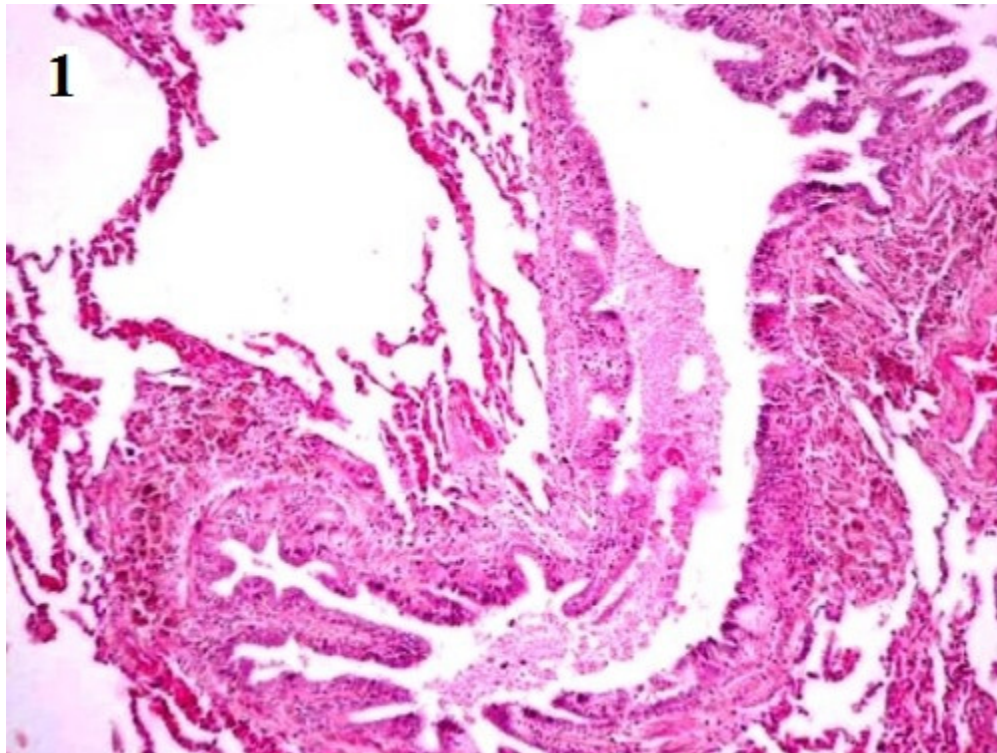
The card for each Gram positive bacteria was automatically filled by a vacuum device, sealed and inserted into the Vitek 2 reader – incubator module (incubation temperature 35.5°C) and subjected to a kinetic colorimetric measurement every 15 min. Data were analyzed using Vitek 2 database version 4.01. All cards used were automatically discarded into a waste container. Final identification results were available in approximately 8 hours or less.

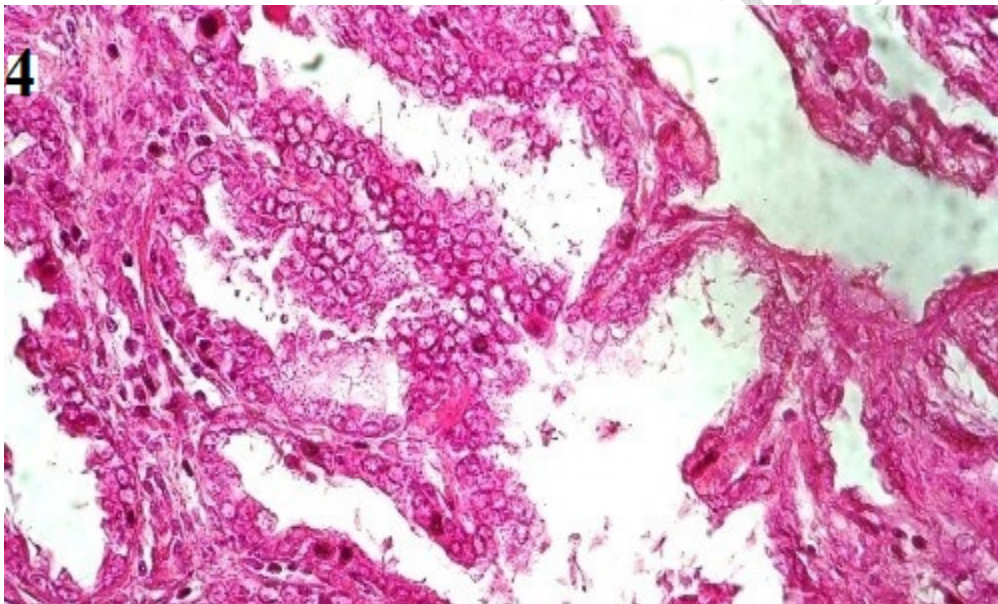
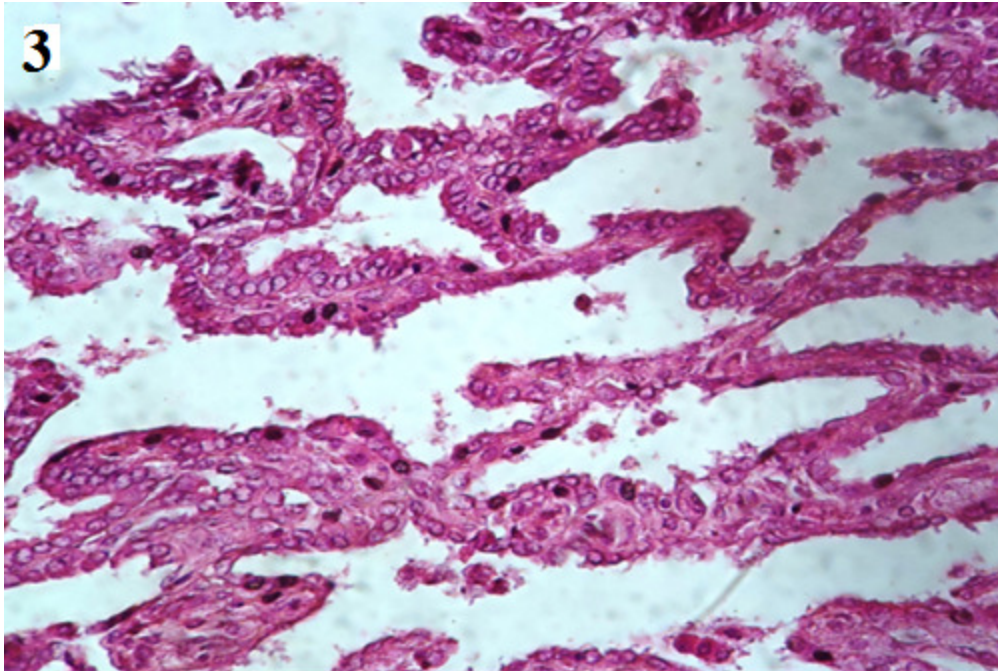
### **2.6.Histopathological Method:**

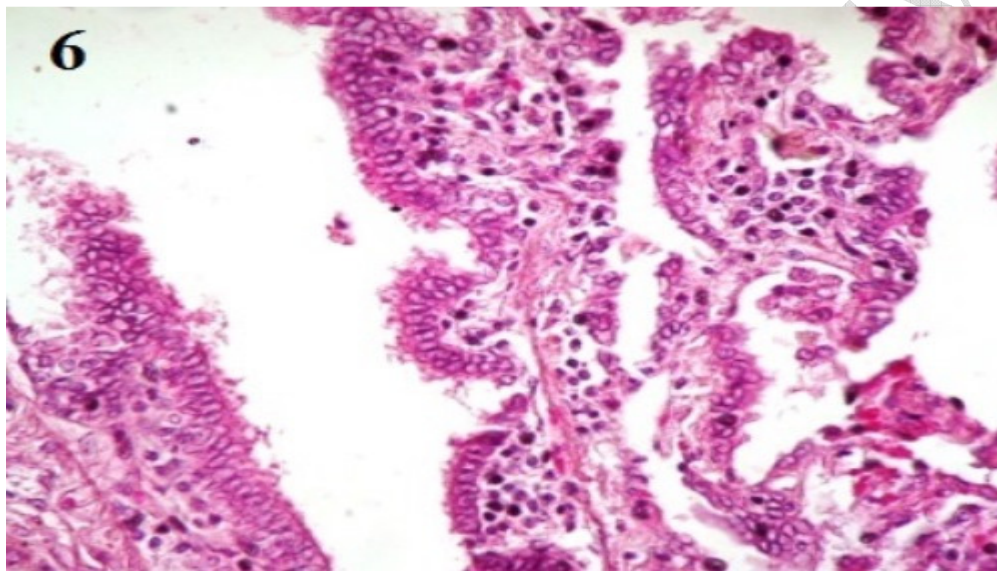
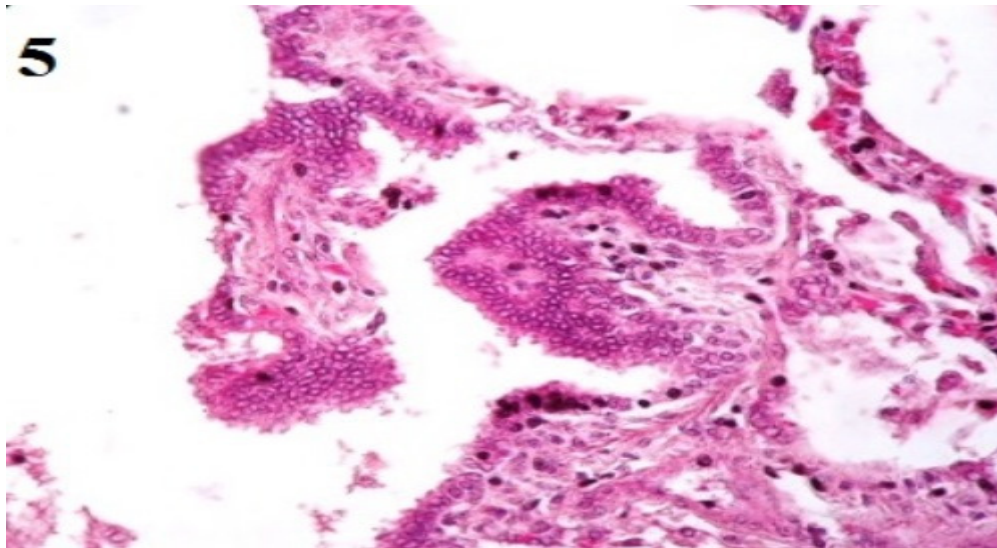
Tissue specimens collected for histopathological examination were fixed in 10% formalin solution, processed by standard paraffin embedding technique; microtomy of the embedded tissue to 5-6 micron thick sections was carried out. These sections were placed onto glass slides, dried and stained with hematoxylin and eosin (H&E).

## **3. Results and discussion**

45 pneumonic lungs samples were collected as mentioned before, various types of bacteria were isolated and different histopathological lesions were noticed but four out of 45 lung samples (8.9%) were diagnosed as pulmonary papillary carcinoma from which *S.aureus*, *S.suis* and *bacillus* sp were isolated.







**1- complete destruction of normal lung architecture, large papillary projection with complex branching.**

**2- fibrovascular cores within papillary projection with primary and secondary branches.**

**3 atypical cells, dark chromatin (nuclear atypia) in some areas, detachment of neoplastic cells floating between tumor branches.**

**4- necrosis, rupture of alveolar with edematous fluid.**

**5-Astormal infiltration of mononuclear cells, loss of arrangement, cell clumps, empty glass appearance, necrosis of tumor cell.**

**6-Psammoma bodies , cuboidal and columnar neoplastic cells.**

In this study, papillary carcinoma described as an unusual histopathological growth pattern characterized by complex papillary infoldings with complex branching, these agree with Cesar [17]. This report described pulmonary papillary carcinoma in female camels, which was diagnosed in Four out of 45 lung samples (8.9%) these animals were slaughtered at Tambool abattoir, at Al-Gazeera state in Sudan of age ranging between 10-15 years. To my knowledge, these are rare malignant tumors in lungs of animals, with a few documented reports in canine and feline.

Grossly, at necropsy, the animals were emaciated with multiple well defined pale yellowish spherical masses of various sizes and soft in consistency scattered in lungs were noticed, the cut surfaces were hemorrhagic.

In the current study the underlying pulmonary architecture was completely distorted and destructed, the neoplastic cells were small, cuboidal, or sometimes columnar as appear in fig 1, this similar to the description of Moulton [18] who reviewed the classification of Lung Carcinomas in the Dog and Cat. Papillary carcinoma of the lung is composed of papillary tufts containing fibrovascular cores (Fig 2).

Papillary carcinoma, also characterized by vesicular chromatin and prominent nucleoli (nuclear atypia) (fig 3). In the present study, Psammoma bodies were noticed (fig 6) and they often associated with the papillary component, either within fibrovascular cores or lining epithelium as described previously by [19].

Astormal infiltration of mononuclear cells andnecrosis (fig 4, 5) which defined by presence of aggregates of cellular necrosis, nuclear debris and neutrophils were apparently detected in my study in compair byElmahi,[20]who characterizeadenomatious lesion in pneumonic lung of local indoginous Saudi goot.

A definitive diagnosis of cancer is frequently obtained by standard histopathology,biopsy specimens are analyzed by routine hematoxylinand eosin (H&E) staining for histopathologic evaluation. In this study, cells are scrutinized for features of malignancy, including abnormal morphology, evidence of invasion mononuclear cells as seen in fig 5 presence of abnormal mitoses, high nuclear cytoplasmic ratio, and absence of encapsulation. Malignant neoplasms are frequently poorly to moderately differentiated in fig 1 and 6 some may be so anaplastic that the cell of origin cannot be determined, these were similar to theprevious observations [21].

Acquired atelectasis consists of two main forms: compressive and obstructive. Compressive atelectasis has two main causes: space-occupying masses in the pleural cavity, such as abscesses and tumors, or from the transferred pressures, such as that caused by bloat, hydrothorax, hemothorax, chylothorax, and empyema. Another form of compressive atelectasis occurs when the negative pressure in the thoracic cavityis lost because of pneumothorax. This form generally has massive atelectasis and thus is also referred to as lung collapse. Obstructive (absorption) atelectasis occurs when there is a reduction in the diameter of the airways caused by mucosal edema and inflammation, or when the lumen of the airway is blocked by mucus plugs, exudate[21],this is similar to (fig 3).Microscopically the alveoli are collapsed andthe alveolar walls appear parallel and close togetheras in (fig1).

in this study *S.suis* was isolated from pneumonic lung tosses that affected with papillary carcinoma, this was in agreement with

Byron who reviewed many cases of *S.suis* infection and cancer together in human from different countries[21].

There are several proposed factors involved in how bacteria replicate and survive within tumors. Traditionally, the main mechanism is thought to be due to the hypoxic nature of many solid tumors, which results in low oxygen levels compared with normal tissues, providing a unique growth environment for anaerobic and facultative anaerobic bacteria [22]. Other factors contributing to bacterial replication in the tumor include the presence of bacterial nutrients within the necrotic region such as purines [23]. Furthermore, the involvement of bacterial chemotaxis towards chemo-attractant compounds present in necrotic regions (e.g. aspartate, serine, citrate, ribose or galactose) produced by quiescent cancer cells has also been suggested as a contributing factor [23].

*S. aureus* and *Bacillus* sp were mentioned by Joanne et al who reviewed the bacteria that were identified within patients of tumors and how they might be used in early detection of cancer (Bacteria and tumors: causative agents or opportunistic inhabitants)[10]

In a study done by Katja in 2017, he demonstrated that purified Lipoteichoic acid (LTA) of *S.aureus* effectively induces growth of non-small-cell-lung-cancer (NSCLC) cell lines of adenocarcinoma and squamous cell carcinoma origin. Thus infection with gram positive bacteria may directly contribute to tumor growth in lung cancer[24].

A case of *S.suis* infection associated with early stage colorectal carcinoma in a man who was an animal farmer was reported by Ioannis in 2006, this may explain the relationship between *S.suis* and neoplasia [25].

Detachment of tumor cells were observed clearly in the figures, this was explained by Bethan[9] as follows: detachment of tumor cells from neighboring cells, Invasion of the tissue basement membrane and then surrounding connective tissue, extravasation

into blood/lymphatic vessels, evasion of the host's defense mechanisms, often by forming a tumor cell embolus with platelets or host lymphoid cells and Adherence to endothelium at a distant site [9].

#### **4. Conclusion:**

Although we cannot rule out the relationship between cancer and infection, we believe that malignancy, led to an immunosuppressed condition that facilitated the development of bacterial infection.

Pulmonary papillary carcinoma is a rare malignant neoplasm in camel.

The definitive diagnosis of this pulmonary neoplasia can be established only by a histopathological examination.

Screening for bacteria present in cancer tissues of various histological types may open up new dimensions in our understanding of this relationship, and its importance, if any. As high throughput deep sequencing technologies become more available, mining for bacterial strains adapted to survive within the tumor microenvironment will permit dedicated studies on this phenomenon, perhaps even leading to the characterization of a potential 'tumor microbiome',

#### **References:**

1. Abdelmalik I Kh, Annabel R and Ahmed K. Papillomavirus Infection in Humans and Dromedary Camels in Eastern Sudan. Vector-borne and zoonotic diseases, 2018; 18(8)
2. Janardhan KS, Ganta CK, Andrews G A. & Anderson DE. "Chondrosarcoma in a Dromedary Camel (*Camelus Dromedarius*)," Journal of Veterinary Diagnostic Investigation, 2011; 23, 619 –622.

3. Ramadan RO. Neoplasia in camels. J. Science and Technology, King Aziz University of Science and Technology. The Camel. 2004;Vol. 2, 38-43. (in Arabic).

4. Al-Hizab FA, Ramadan RO, Al-Mubarak AI and Abdelsalam EB. Basal cell carcinoma in a one humped camel (*Camelus dromedarius*). A clinical report. J. Camel Pract. Res. 2007;14(1), 49-50.

5. Siddiqui MI, Al-Kubati SA, Telfah MN, Rashid J and Hashmi S. Frequency and type of toenail tumors in the dromedary camel, Open Veterinary Journal, (2013), Vol. 3(1): 64-68.

6. Abeer AM, Zakia AM, Muna EA and Afaf EA. Incidence of Multiple Mammary Tumors and Fibroadenoma in Pathological Study of Udder Affections in Camel (*Camelus dromedarius*) Journal of Cancer and Tumor International, 2016; 4(1): 1-7

7. Bryant B, Portas T, Montali R. Mammary and pulmonary carcinoma in dromedary camel. Australian veterinary journal, 2007; 85(1): 59-61

8. Gamal W and Shawky A. Pulmonary Leiomyoma in a dromedary camel (*Camelus Dromedarius*). International Journal of Veterinary Medicine: Research & Reports Vol. 2013; Article ID 773813, DOI: 10.5171/2013.773818

9. Bethan G, Daniel JO, Atul A. Pathology Edinburgh London New York Oxford Philadelphia St Louis Sydney Toronto 2012.

10. Joanne C and Mark T. Bacteria and tumours: causative agents or

opportunistic inhabitants?. *Infectious Agents and Cancer* 2013, 8:11.

11. Chang Y, et al: Identification of herpesvirus-like DNA sequences in AIDS-associated Kaposi's sarcoma. *Science* 1994, 266(5192):1865–1869.

12. Huang YQ, et al: Transcription of human herpesvirus-like agent (HHV-8) in Kaposi's sarcoma. *J Clin Invest* 1996, 97(12):2803–2806.

13. Cover TL, Blaser MJ: *Helicobacter pylori* in health and disease. *Gastroenterology* 2009, 136(6):1863–1873.

14. Polk DB, Peek RM Jr: *Helicobacter pylori*: gastric cancer and beyond. *Nat Rev Cancer* 2010, 10(6):403–414.

15. Liong MT: Safety of probiotics: translocation and infection. *Nutr Rev* 2008, 66(4):192–202.

16. Zhou JS, et al: Acute oral toxicity and bacterial translocation studies on potentially probiotic strains of lactic acid bacteria. *Food Chem Toxicol* 2000, 38(2–3):153–161.

17. Cesar A. Moran, MD. Pulmonary Adenocarcinoma The Expanding Spectrum of Histologic Variants. *Arch Pathol Lab Med*. 2006; Vol 130

18. MoultoncJE, Tscharne VO and Schneider R. Classification of Lung Carcinomas in the Dog and Cat. *Vet. Pathol*. 1981; 18: 513-528

19. Silver, susan AMD; Askin, Frederic BMD. True papillary carcinoma of lung :Adistinctclinicopathologicentity. The American journal of surgical pathology,21(1)1997:43-51.
20. Elmahi BA. Adenomatous lesion in a pneumonic lung of a local indigenous saudi goat. Pakistan journal of biological sciences, 2005; 8(4) p542-545
21. Donald MM, James FZ. Pathological basis of veterinary diseases, Emerging Infectious Diseases • [www.cdc.gov/eid](http://www.cdc.gov/eid), 2014; 20(6)
22. Wei MQ, *et al*: Facultative or obligate anaerobic bacteria have the potentialfor multimodality therapy of solid tumours. Eur J Cancer, 2007; 43(3):490–496.
23. Baban CK, *et al*: Bacteria as vectors for gene therapy of cancer. BioengBugs 2010; 1(6):385–394.
24. Katja H, Christian P, ReinertUlf,Mira Y,Florentine SB, Jochen W, Bastian Eul, Gabriele D,Friedrich G, Werner S, Ulrich G. Lipoteichoic acids from *Staphylococcus aureus* stimulate proliferation of human non-small-cell lung cancer cells in vitro. Cancer ImmunolImmunother (2017); 66:799–809.
25. Ioannis A, *streptococcus suis* endocarditis and colon carcinoma: a case report.clinical colorectal cancer 2006; 6(3), p226-228