

## Histo-toxicity of Corexit 9500 dispersant on Gill and Liver of *Clarias gariepinus* (Burchell 1822)

### ABSTRACT

Corexit 9500 is a chemical sprayed on oil spills, toxic to marine organisms causing aquatic pollution and deaths. The aim of this study was to assess the chronic toxicity of Corexit 9500 on histology of liver and gill of juveniles of *Clarias gariepinus*. Range finding tests were conducted over a 96-hr period after acclimatization of the test organisms in the laboratory. The test organisms 10/treatment were exposed to the following concentrations of Corexit 9500; 0.00 ml/L, 0.0125 ml/L, 0.025 ml/L and 0.05 ml/L in triplicate. Liver and gill were excised from fish every week for histological assay using standard methods. The LC<sub>50</sub> at 96hrs was 0.115 ml/L. The growth in length and weight of *C. gariepinus* was significantly higher in the control than the test treatments ( $p < 0.05$ ). Hyperplasias, necrosis of epithelial cells, inflammation of the secondary gill lamella and hypertrophic primary gill lamella were observed in the exposed gills. Hepatic lesions in the liver tissues of the fishes exposed to Corexit 9500 were characterized by hyperplasia, narrowing of the central vein and vacuolations. The alterations observed in the liver and gill tissues indicated that Corexit 9500 may have interfered with transamination and metabolic processes, with the possibility of affecting the physiological functions of the fish in an aquatic environment.

**Keywords:** Corexit 9500, *Clarias gariepinus*, Dispersant, Gill, Liver, Histotoxicity

### 1. INTRODUCTION

Oil spill dispersants are tools or reagents known to be efficacious in the dispersal of oil spills [1]. They are made up of a complex mixture of solvents and surfactants which aid in lowering the interfacial tension of oil and water, enabling phase mixing, formation of micelle and dispersion at the surface [2]. The toxicity of these chemicals is of immense concern as different chemicals when combined together in an effluent can have unknown synergistic effects even if their respective toxicities are known and of no consequence [3, 1]. However, toxicity is a relative property of a chemical, which refers to its potential to have deleterious effects on living organism. Acute toxicity is a property of a substance that has toxic effects on an organism, when the organism is exposed to a lethal dose of a substance once and chronic

toxicity is a property of a substance that has toxic effects on a living organism, when the organism is repeatedly exposed to that substance [4].

Fishes are veritable tools for assessing the effect of pollution in aquatic environments because of their mobile nature [5]. *Clarias gariepinus* belong to the family Clariidae and contribute greatly to the commercial catch of the artisanal fishers in fresh water communities of the Niger Delta and Nigeria at large. It is also a preferred species for aquaculture and greatly enhances the protein requirements of the people. In Nigeria, the Niger-Delta region has been affected the most by oil spills resulting in the degradation of the environment and in a bid to control the pollution, several dispersants have been introduced into water bodies which may also impact natural and man-made ponds, thus triggering acute and chronic responses in fish and other aquatic lives.

Corexit 9500 is one of the several dispersants that are commercially available and used to change the inherent chemical and physical properties of oil, thereby changing the oil's transport, fate, and potential effects in the environment. In Nigeria, the use of dispersants is permitted only in an offshore environment [6]; however, Corexit 9500 is not among the approved dispersants in Nigeria [7] and was first used in the British Petroleum Deepwater Horizon (DWH) Oil spill in the Gulf of Mexico in 2010, without knowledge of its toxicological effects on aquatic fauna. Consequently, [8] reported that the absence of thorough scientific research on dispersants and the chemicals that comprise dispersants, as well as the lack of public disclosure of each dispersant's ingredients and formulation, hinders any effort to understand the full impacts of dispersant use. Nevertheless, some studies have investigated the chemical reactions of Corexit 9500 and other dispersant (Goldscrew, Eco-Remover, Rigwash, Biosolve) on spilled oil and their toxicity to some aquatic vertebrate and invertebrate fauna [9, 10, 11, 12, 13 and 14], however, there is a dearth of information on the

histopathological responses of Corexit 9500 on the gill and liver of *Clarias gariepinus*. This study is aimed at filling some of the gaps in the knowledge of 'Corexit 9500' using measurable histopathological alterations in the gill and liver tissues as well as its effect on growth, survival and on the physicochemical characteristics of the medium.

## **2. MATERIALS AND METHODS**

### **2.1 Acclimatization and Feeding of fish**

Live juveniles of *Clarias gariepinus* were obtained from Sokari Integrated Farm and Services (a private fish farm) in Port Harcourt City and acclimatized in a square glass aquaria for fourteen days [15]. The choice of this fresh water species was as a result of its high aquaculture value by fish farmers of natural and man-made ponds in the Niger-Delta, availability and ease of handling. Three hundred (300) juveniles (mean length  $8.40 \pm 2.40$  cm and mean weight  $3.28 \pm 1.28$  g SE) were kept at room temperature  $27 \pm 2^{\circ}\text{C}$  in a 'borehole' waterfilled glass aquaria of 400 Litres capacity. A Hunzu air pump was used to provide aeration. The water exchange was done every two days and fish were fed twice a day with 1% body weight of fish feed made up of 35% crude protein.

### **2.2 Procurement of Corexit 9500**

Corexit 9500 was purchased from a chemical shop in Port Harcourt in 4 litre plastic gallon and stored for use in the preparation of the test solution. The active ingredient includes; Sodium nitrate 7661-99-4, Sodium nitrate 7632-00-0 and Sodium tetraborate 130-3-4 (Lot no. BPOJ1337A). The dispersant was a 'Type 1' dispersant, so it was not diluted. In order to determine the appropriate concentrations a preliminary range finding test was carried out on a group of five fishes which were exposed to six spaced sample dilution of the stock solution in logarithmic series of 0.1, 1, 3, 5, 7, 9 and 15 ml/L for 24 hours. The test fishes were first

observed after an exposure period of 8 hours [16] and 4 hours interval and a control. The lowest concentration with signs of behavioural anomaly (erratic swimming, hyperventilation) was noticed at 5ml/L plastic basin after about 8 hours.

### **2.3 Experimental design**

The experimental design was a Complete Randomized Design (CRD). Toxicity was assessed by diluting the oil spill dispersant in concentrations. Acute and chronic toxicity tests were carried out. The tests were compared against themselves and the control; each test chamber had ten (10) fish base on the loading weight. It was recommended that the loading rate for static renewal tests in the test solutions should not surpass 0.65g/L at 20<sup>0</sup>C for acute tests and 0.40g/L at 25<sup>0</sup>C for chronic test and the plastic container should not be crowded [17].

### **2.4 Definitive test/LC<sub>50</sub>**

Definitive test 0.1, 0.3, 0.5, and 0.7ml/L of Corexit 9500 and a control were used for measuring mortality of fish over a period of 96 hours [18]. 2.0ml/L was used as the dilution factor [19,20]. The test solution was renewed every 24 hours and fishes were not fed during the experiment.

### **2.5. Chronic testing**

A 25L plastic basin was used for dilution of test solution. However, the test concentration of 0.00 (control), 0.0125, 0.025, and 0.05ml/L of Corexit 9500 in dilution water were prepared by separately mixing 0.2, 0.4 and 0.8ml/L of Corexit 9500 in 16 litres of water. A 2 ml syringe was used for measuring the dispersant into one litre of water [20] while the fish was randomly introduced into the test basins. The test concentration and water in the plastic basin were renewed after every 2days. All treatment concentrations had 3 replicates of ten fish and there were no sexual considerations.

### **2.5.1 Evaluation of some physicochemical parameters**

The water quality of the test media were measured in-situ to ascertain its correctness for fish survival based on recommended quality parameters [15, 21], thus in this study pH, Dissolved Oxygen (DO), Conductivity and Temperature were measured on a weekly basis using a standard Hanna multi-parameter probe (model no: HI98130).

### **2.5.2 Dissection**

At the end of every week the fishes from each concentration were immobilized by cervical dislocation prior to dissection on a dissecting board; a surgical blade was used to make a longitudinal slit on the ventral surface of the abdominal wall, from the anus to a point by the pectoral fin, the operculum was then opened to reveal the gills. The alimentary tract was removed completely and liver separated from the anterior part of the gut while the gills were cut out and placed in separate Petri-dishes and preserved in Universal bottles containing 10% formal saline solution for histological assay.

### **2.5.3 Histopathological examination**

The universal bottles containing the gill and liver samples were immediately transported to the Histopathology laboratory of the Rivers State University. Histological analysis was done on the test organisms to evaluate the sub lethal effects of the different concentration according to [15]. Tissue processing was then done by systematic dehydrating, clearing, impregnating, and embedding. This was done by an automatic tissue processor after which they were microtomed. In the dehydration, the tissues were sequentially put in 10% formal saline, 70% , 90%, 95% alcohol, absolute I(100% alcohol), absolute II, and finally in absolute III. After this the tissues were cleared in Xylene I and Xylene II. Impregnation involved putting the dehydrated and cleared tissues in molten Paraffin Wax (Wax I and then Wax II) (between 50-60<sup>0</sup>C) in cassettes within the wax cups. The tissues were then embedded

and microtomed (4 - 5 $\mu$ ) and placed on glass slides to dry. The microtomed tissues were stained using the H & E method which involved staining the tissues for three minutes with Haematoxylin (H) and for 10 minutes in 1% solution of Eosin (E). Micrographs of stained slides were obtained using a Leica ATC 2000 Photomicroscope at X100 magnification.

## 2.6 Statistical Method

Data obtained from this study was collated and subjected to one way analysis of variance (ANOVA) and Tukey was used for mean separation using JMP-SAS version 12. Results were considered significant at P-value <0.05.

## 3. RESULTS

### 3.1 Mortality Rate

Table 1 shows the mortality rate of *C. gariepinus* exposed to acute concentrations of Corexit 9500. It indicated that out of the total fishes exposed to the various concentrations during the study period 0, 2, 4 and 9 individual fishes died in 0.3, 0.5 and 0.7ml/L concentrations while 1, 2, 6 and 1 fishes died within 48 hrs. At a seventy-two hour period only a single mortality was recorded at 0.1 and 0.3ml/L concentrations.

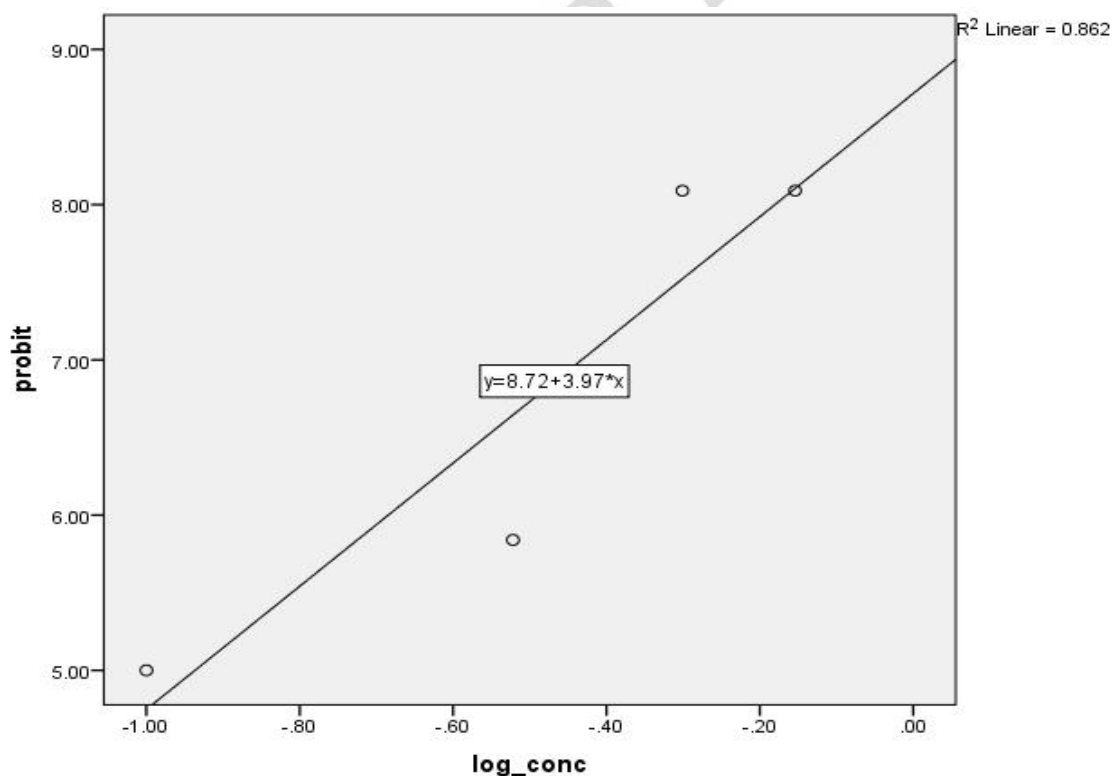
**Table 1:** Mortality rate of *Clarias gariepinus* exposed to acute concentrations of Corexit 9500.

Conc. in (ml/L)	Log of Conc.	of Deaths	24 hours	48 hours	72 hours	96 hours	Total mortality	Probit
0.0	0	10	0	0	0	0	0	0

0.1	-1	10	0	1	1	3	5	5
0.3	-0.522	10	2	2	1	3	8	5.84
0.5	-0.301	10	4	6	0	0	10	8.09
0.7	-0.154	10	9	1	0	0	10	8.09

### 3.2 Definitive Test/ $LC_{50}$

Test concentrations of 0.7, 0.5 and 0.3 ml/L resulted in total mortality of fish over a period of 24, 48, 72 and 96 hours. While the 0.1 ml/L concentration led to 50% mortality after 96 hours for Corexit 9500. The 96-hr Median Lethal Concentrations ( $LC_{50}$ ) of the dispersant (Fig 1) obtained from graphical illustration was 0.115 ml/L. The Coefficient of Determination ( $r^2$ ) between the log concentration of the dispersant (Corexit 9500) and the probit mortality was 0.862.



**Figure 1:** The Lethal Concentration ( $LC_{50}$ ) at 96-hr for Corexit 9500 in *C. gariepinus*

### 3.3 Physicochemical parameters

The physicochemical parameters (Table 2) of all the test media showed that temperature was not significantly different at  $P>0.05$  (26.17-26.53°C). The DO of control was significantly higher than that of the treatments, with the lowest DO observed in the 0.05ml/L treatment. pH was acidic for all treatments including the control but was more acidic with increasing concentration of Corexit 9500 (5.84-5.51). The pH value for each treatment was different ( $p<0.05$ ). The conductivity of the control was not different from the treatments, but the treatments were different from each other ( $p<0.05$ )

**Table 2: Mean ( $\pm$ SE) of physicochemical parameters in exposure tanks**

Concentrations ml/L	Conductivity (s/m)	Temp(°C)	DO(ml/L)	pH
Control	21.53 $\pm$ 0.50 <sup>abc</sup>	26.50 $\pm$ 0.14 <sup>a</sup>	6.15 $\pm$ 0.33 <sup>a</sup>	5.84 $\pm$ 0.12 <sup>a</sup>
0.0125	20.42 $\pm$ 0.67 <sup>b</sup>	26.53 $\pm$ 0.35 <sup>a</sup>	5.63 $\pm$ 0.22 <sup>b</sup>	5.56 $\pm$ 0.08 <sup>bc</sup>
0.025	23.87 $\pm$ 3.57 <sup>c</sup>	26.17 $\pm$ 0.16 <sup>a</sup>	5.76 $\pm$ 0.41 <sup>b</sup>	5.64 $\pm$ 0.24 <sup>b</sup>
0.05	21.25 $\pm$ 0.61 <sup>a</sup>	26.31 $\pm$ 1.19 <sup>a</sup>	5.35 $\pm$ 0.22 <sup>c</sup>	5.51 $\pm$ 0.10 <sup>c</sup>

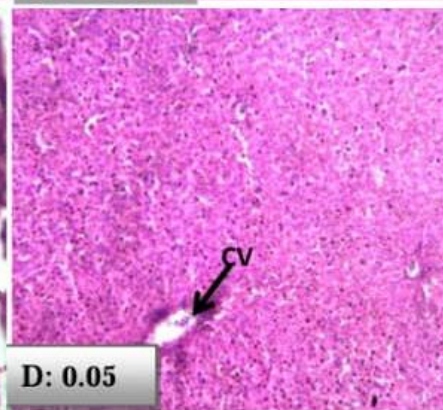
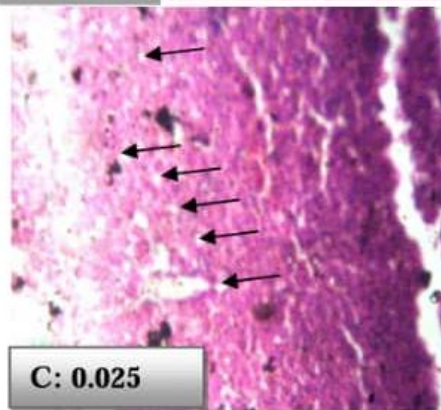
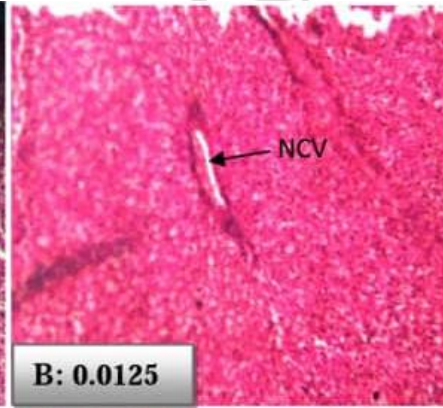
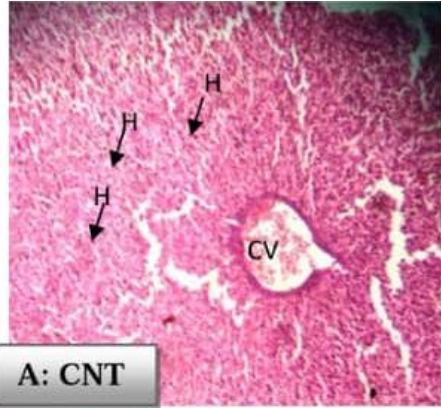
*Values with different superscript in the same column are significantly different from each other ( $p<0.05$ )*

### **3.4 Histology of Liver and Gills of *C. gariepinus***

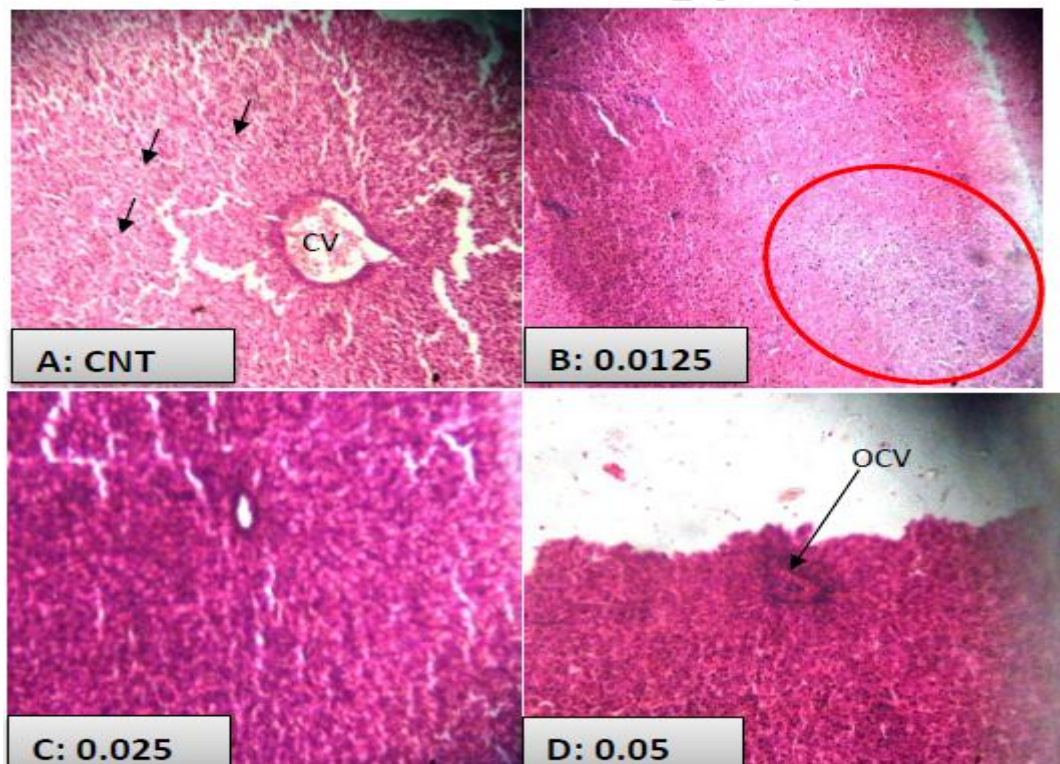
#### **3.4.1 Liver**

The photomicrographs of the liver (Plate 1) in week one showed mild hyperplasia at 0.05ml/L exposure concentration and vacuolation of liver parenchyma at 0.025ml/L exposure concentration. Slides were generally similar for the lower concentrations and the control, however by the second week, the lowest exposure concentration of 0.0125ml/L showed tissue necrosis as well as occlusion of the central vein (OCV) as evident from Plate 2. By the 3<sup>rd</sup> week, liver cells at 0.025ml/l and 0.05ml/l exposure concentrations showed vacuolation of the liver stroma ( Plate 3).

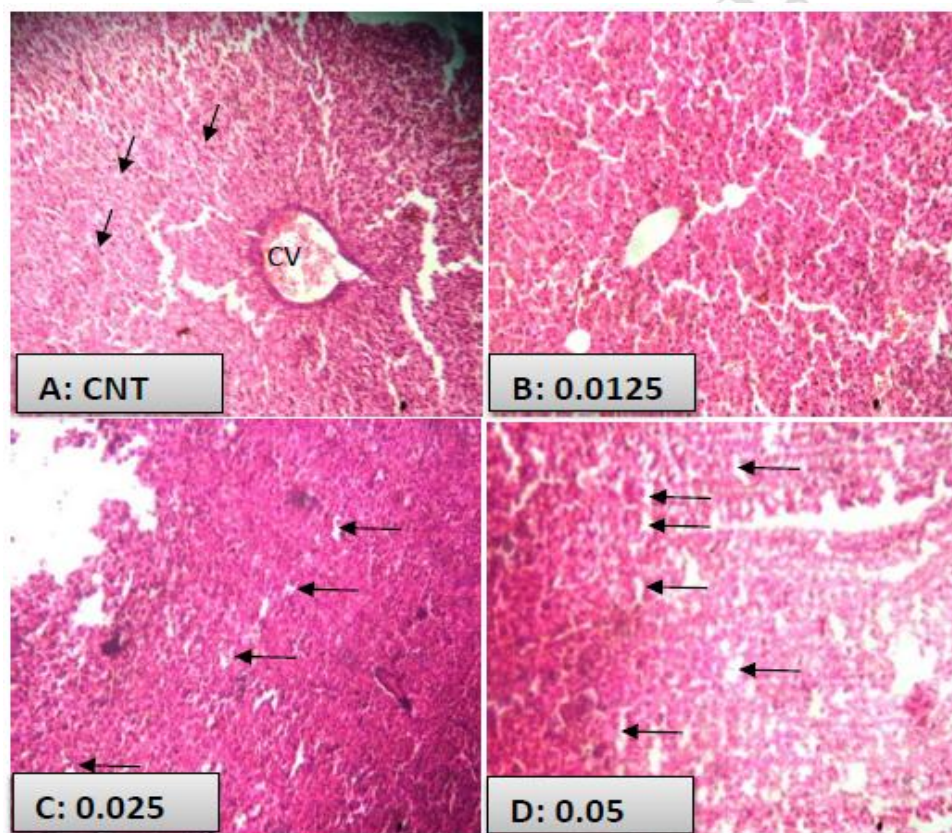




**Plate 1:** Photomicrographs of the Liver of fish exposed to various concentrations of Corexit 9500 (A= Control (CNT), B= 0.0125, C = 0.025 and D= 0.05ml/L) in week one (Mag. x100).



**Plate 2:** Photomicrographs of Liver of fish exposed to various concentration of Corexit 9500 [A= Control (CNT), B= 0.0125, C = 0.025 and D= 0.05ml/L) in week two (Mag. x100). Slide A (Control) is the liver with a normal Central Vein (CV) and Hepatocyte (H) indicated by the black arrows, while slide B shows tissue necrosis (red circle). However, there is no notable histological change in slide C while in slide D there was occlusion of the Central Vein (OCV) with marked inflammatory cells.

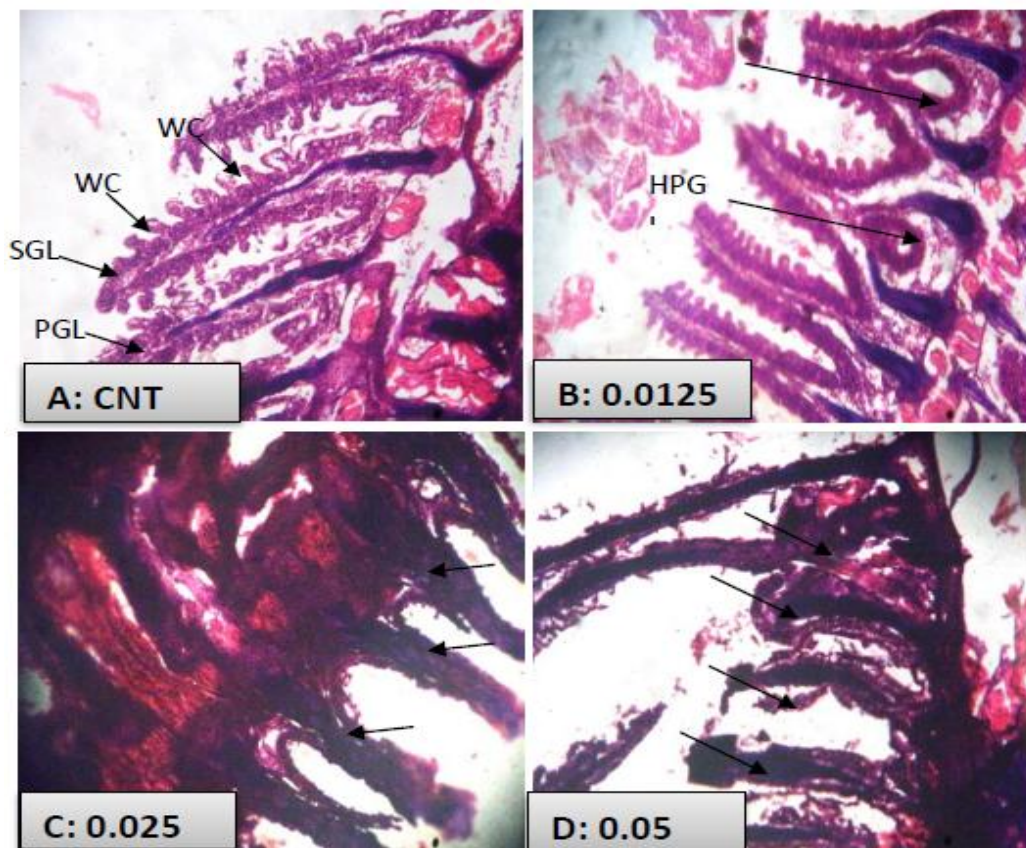


**Plate 3:** Photomicrographs of Liver of fish exposed to various concentration of Corexit 9500 [A= Control (CNT), B= 0.0125, C = 0.025 and D= 0.05ml/L] in week three (Mag.x100). In Plate 3 the following observations were noted ; Slide A ( Control) indicated that the liver had a normal Central Vein (CV) and Hepatocyte (black arrow) , there was no notable changes in slide B while Slide C and D showed vacuolisation ( black arrow) of the liver stroma.



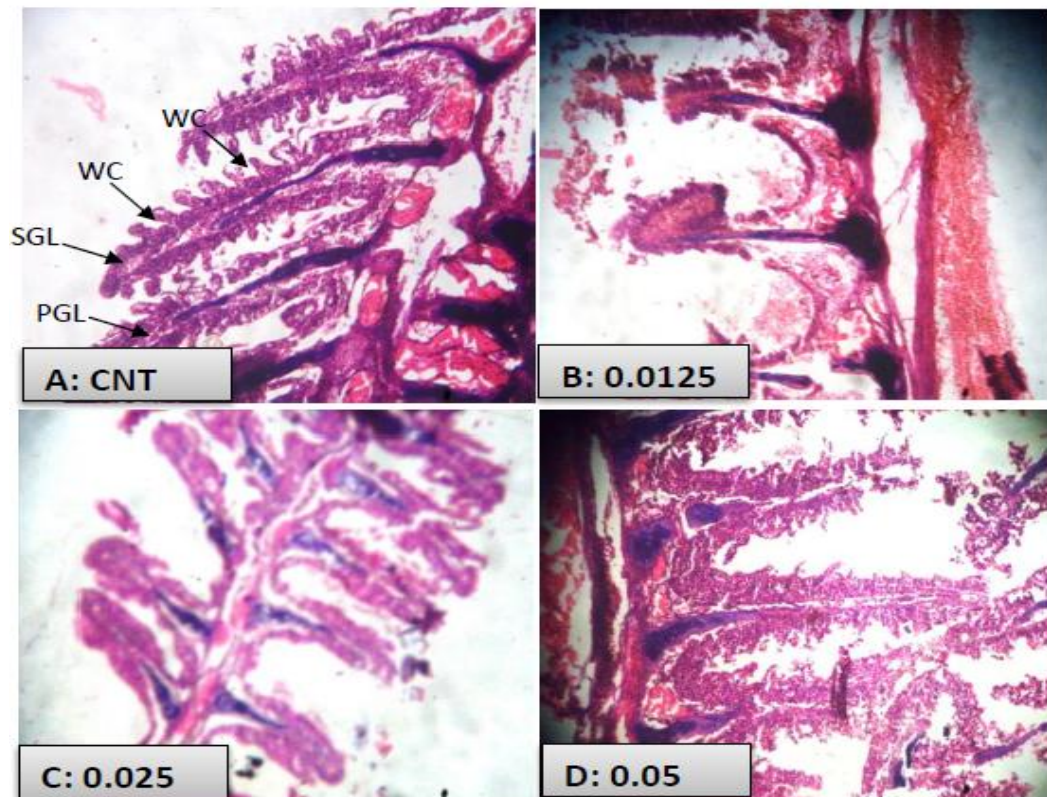
### 3.4.2Gills

Plate 4 showed fish gills had hypertrophy in the primary gill lamellae at the 0.025ml/L concentration and inflammation of the secondary gill lamellae at the higher exposure concentrations (0.025 and 0.05ml/L) in the first week of exposure. Further histological analysis showed that in Slide A (Control) the gill had a normal water channel (WC), primary and secondary gill lamella (PGL and SGL), while slide B had hypertrophic primary gill lamella (HPGL). C and D showed inflammation of the secondary gill lamella (Arrow).



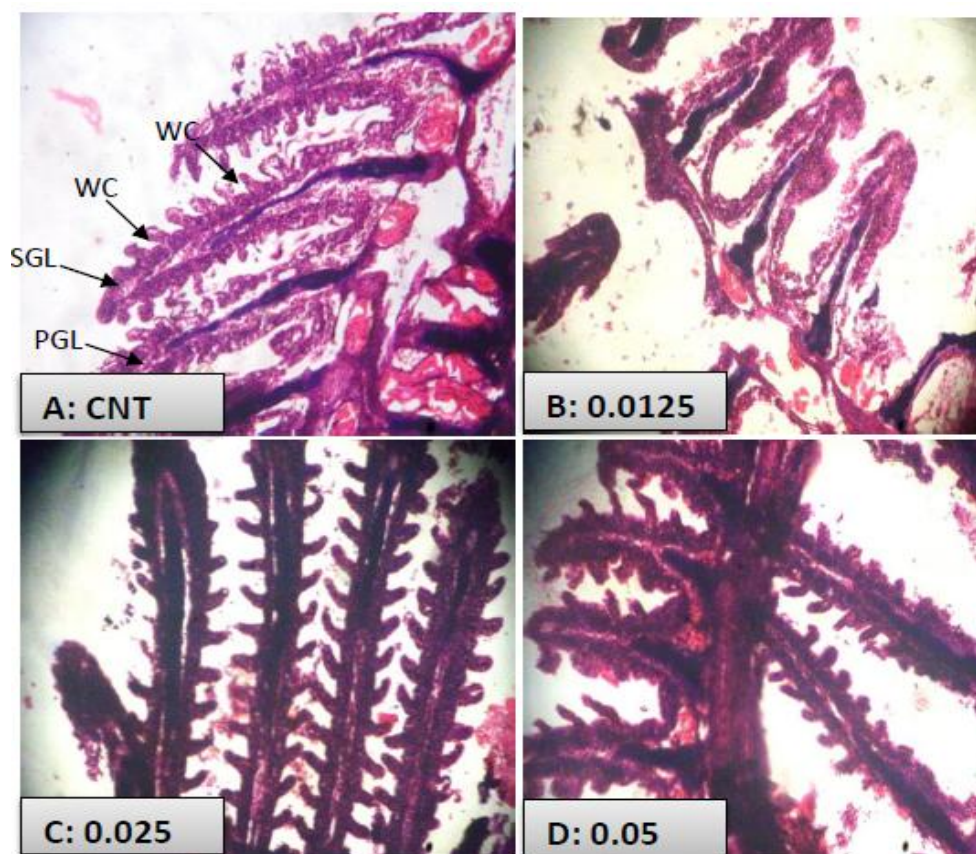
**Plate 4:** Photomicrographs of Gill of fish exposed to various concentration (0.0125, 0.025 and 0.05ml/L) of Corexit 9500 in week one (Mag. x100).

Plate 5 shows the photomicrographs in the second week of sampling which indicated that there was loss of secondary gill lamellae at the 0.0125ml/L exposure concentration, while the higher concentrations of 0.025 and 0.05ml/L appeared to be similar to the control.



**Plate 5:** Photomicrographs of Gill of fish exposed to various concentration (0.0125, 0.025 and 0.05ml/L) of Corexit 9500 in week two (Mag. x100).

Plate 6 shows the photomicrographs at the third week of exposure and it clearly confirms that the secondary gill lamellae and water channels were poorly displayed in comparison to the control while the higher concentrations of exposure revealed inflammation of the primary and secondary gill lamellae.



**Plate 6:** Photomicrographs of Gill of fish exposed to various concentration (0.0125, 0.025 and 0.05ml/L) of Corexit 9500 in week three (Mag. x100).

#### 4. DISCUSSIONS

##### 4.1 Definitive test/LC<sub>50</sub>

Data obtained from this study is indicative that 96 hour LC<sub>50</sub> for *C. gariepinus* juveniles exposed to Corexit 9500 was 0.115ml/l. This result was lower than that reported by [1]. The 96 hour LC<sub>50</sub> is not constant and is known to vary for different toxicant [22, 23] and concentrations [24].

##### 4.2 Physicochemical parameters



The observed significant ( $P \geq 0.05$ ) decrease in the values of DO with increasing concentrations of Corexit 9500 could be attributed to the ability of the dispersant to reduce soluble oxygen and interfere with diffusion of atmospheric oxygen in the medium. The reduced dissolved oxygen content of the Corexit 9500 with higher concentration might have caused stress in the fish resulting in reduced feed uptake activity and suffocation which might have led to the fish death during acute testing. Similar results were observed by [25] and [26].

#### **4.3 Histopathology of Liver and Gills**

The outcomes from the current investigation suggest that the histopathological lesions observed in the fishes were as a result of exposure to Corexit 9500 compounds. Histopathological characteristics of particular organs express condition and time-integrated endogenous and exogenous effects on the organism stemming from alterations at lower levels of biological organization [27]. Therefore, histological changes occur earlier than reproductive changes and are more sensitive than growth or reproductive parameters and, as an integrative parameter, provide a superior assessment for the growth and development of the organism than a single biochemical parameter [28].

The liver is the main organ for detoxification [29] that suffers serious morphological alterations in fish exposed to water toxicants [30]. Therefore toxic effects of chemicals usually appear primarily in the liver. Alterations in the liver may be useful as markers that indicate prior exposure to environmental stressors. Significant deformations in liver on exposure to the Corexit 9500 were observed and may affect the various liver functions of *C. gariepinus* as observed by previous studies [31, 32]. Necrosis was also observed which indicated that the capacity of *C. gariepinus* to maintain homeostasis was affected.

The changes in the gills of *C. gariepinus* exposed to the water toxicants fall within the general reactions of fish organs to environmental pollutants. Fernandes and Mazon [33] observed that fish gills are the prime target organ of all pollutants due to their extensive surface area in contact with the external medium. The reduced distance between the external medium and gill morphology are important biomarkers that provide a rapid method of detection of the effect of pollutants [34]. The damage of gills of fish exposed to the sub-lethal concentrations of Corexit 9500 was severe. Extensive structural loss was observed in the gills of Corexit 9500 treated group. The observed lamellar necrosis and inflammation of the primary and secondary lamellar of the gill epithelium are direct responses induced by the action of Corexit 9500, this is in accordance with [35] classification of gill lesions. Hypertrophy was also observed in the Corexit 9500 treated group. Gill alterations such as hyperplasia of the epithelial cells can be considered adaptive, since they increase the distance between the external environment and blood, serving as a barrier to the entrance of contaminants. Hyperplasia as the fish's response maybe (1) to ward off or block something that irritates its tissues, whether externally or internally, or (2) to quickly heal an injured or irritated site. Hypertrophy however, may play a role in the early stages of neoplasia. Gill hyperplasia might serve as a defensive mechanism leading to a decrease in the respiratory surface and an increase in the toxicant-blood diffusion distance. Changes in fish gill are among the most common responses to environmental pollutants [36].

The gills of Corexit 9500 treated samples exhibited lamellar telangiectasis (localised dilation of blood vessel). This appearance of the secondary lamellae results from the collapse of the pillar cell system and breakdown of vascular integrity with a release of large quantities of blood that push the lamellar epithelium outward [37]. Shortening and clubbing of ends of the secondary gill lamellae and clubbing of adjacent lamellae were well marked in the Corexit 9500 treated group.



## 5. CONCLUSIONS / RECOMMENDATIONS

The histology of *C. gariepinus* with occlusion of the central vein, hyperplasia and vacuolation of liver parenchyma, and hypertrophy in primary gill lamellae of the gills are attributed to Corexit 9500 induced hepatic and gill toxicity. The result of such exposure led to stress-induced retarded growth and deaths through impaired cellular functions. Corexit 9500 was found to be highly toxic to *C. gariepinus* even at very low concentration. The  $LC_{50}$  for *C. gariepinus* juveniles exposed to Corexit 9500 was 0.115ml/L. The parameters measured could provide useful information for evaluating the toxicological effects of Corexit 9500 on some fresh water fish and help in the diagnosis of the pollution. Thus, long term and short term sequential data should be provided on the use of different types of dispersant and their impact when mixed with crude oil and studies should be carried out on oil spill dispersant using different species as their impact is species selective. Furthermore, dispersants should be used as a last resort in the field when combating an oil spill.

## ETHICAL APPROVAL

We declare that principles of animal care were followed and to the best of our knowledge there were no existing national ethical laws at the time of study.

## COMPETING INTERESTS DISCLAIMER:

Authors have declared that no competing interests exist. The products used for this research are commonly and predominantly use products in our area of research and country. There is absolutely no conflict of interest between the authors and producers of the products because we do not intend to use these products as an avenue for any litigation but for the advancement of knowledge. Also, the research was not funded by the producing company rather it was funded by personal efforts of the authors.

## REFERENCES

1. Nwaizuzu, C., Joel, O.F., & Sikoki, F.D. (2016). *Synergistic Effects of Dispersed Bonny light Crude oil on selected Aquatic Organism*, SPE Nigeria Annual International Conference and Exhibition (Accepted manuscript).
2. Van Scoy, A.R., Lin, C.Y., Anderson, B.S., Philips, B.M., Martin, M.J., McCall, J., Todd, C.R., Crane, B., Sowby, M. L., Viant, M. R. & Tjeerdema, R.S. (2010). Metabolic responses produced by crude versus dispersed oil in Chinook salmon pre-smolts via NMR-based metabolomics, *Ecotoxicity and Environmental Safety* 73, 710 – 717.
3. Joel, O.F., Amajuoyi, C. & Dede, E.B. (2009). Dose time Effect of Crude Oil and Hydro-test Effluent on Freshwater and Brackish Water Habitats, *J. Appl. Sci. Environ. Manage.*, 13(2):41- 45.
4. Klaassen, C. D. & Eaton, D. L. (1991). Principle of Toxicology. In: Casarelt and Doull's Toxicology: The Basic Science of Poisons, 4th ed., M. O. Amdur, J. Doull and C. D. Klaassen (eds). Pergamom, Press, New York. 12 –49.
5. Van der Oost, R., Beyer, J. & Vermeulen, N. P. F. (2003). Fish bioaccumulation and biomarkers in environmental risk assessment: a review. *Environmental Toxicology & Pharmacology* 13(2): 57-149.
6. DPR, (2002). Environmental Guidelines and Standards for the Petroleum Industry in Nigeria (EGASPIN), Revised Edition 2002. Department of Petroleum Resources (DPR): 277 –288.
7. DPR[Department of Petroleum Resources]. (2018). List of approved chemicals for the Nigerian oil and gas industry. <http://www.dpr.gov.ng>. Accessed 4th March , 2018.
8. Toxipedia Consulting Services (2011). Chaos of clean-up: Analysis of potential health and environmental impacts of chemicals in dispersant products. Eathjustice, Oakland, Gulf Restoration Network , New Orleans and Florida Wildlife Federation, Tallahassee , U.S.A. 18pp
9. Uffort , E.E. & Odokuma, L.O. (2018). Acute toxicity of two oil spill dispersants used in Nigerian Petroleum Industries to Nitrobacter and Thiobacillus. *IOSR Journal of Environmental Science, Toxicology and Food Technology* 12 (4), 19 – 25.
10. Prince, C.N. & Lucky, O.O.(2017). Impact of Rigwash oil spill dispersants on the biodegradation of crude oil in Nigeria. *Microbiology Research Journal International* 18(4), 1- 10. DOI:10.9734/MRJI/2017/30857.
11. Rodrigo, A., Cammie, J.H., & Edward, B.(2014). Toxicity of dispersant Corexit 9500A and Crude oil to marine microzooplankton . *Ecotoxicity and Environmental Safety* 106C, 76 -85. DOI: 10:1016/j.ecoenv.2014.04.028.
12. Blair, K. (2011). "DISPERANTS: Chemicals BP used may cause cancer". Pensacola News Journal. Archived from the original on 28 July 2013.

13. Alagoa, K. J. (2010). Effect of Goldcrew and Corexit on selected blood parameter of the African catfish (*Clarias gariepinus*) following sublethal exposure. *Journal of Environmental Chemistry and Ecotoxicity*, 2(5):67-72.
14. Lindstrom, J.E., White, D.M. & Braddock, J.F. (1999). Biodegradation of dispersed oil using Corexit 9500. A report produced for Alaska Department of Environmental Conservation Division of Spill Prevention and Response.
15. Lelei, K.E. & Sikoki, F.D. (2013). Uptake of Polycyclic Aromatic Hydrocarbons by the fingerlings of *Oreochromis niloticus* (Linnaeus, 1757) from the dispersed phase of bonny light crude oil, Proceedings of The 3rd Annual International Conference Syiah Kuala University (AIC Unsyiah) 2013 In conjunction with The 2nd International Conference on Multidisciplinary Research (ICMR) Banda Aceh, Indonesia.
16. USEPA [United States Environmental Protection Agency] (2010). EPA Response to BP Spill in the Gulf of Mexico. Website. US Environment Protection Agency, Washington, D.C. [http://www.epa.gov?bpspill/dispersant methods.html](http://www.epa.gov?bpspill/dispersant%20methods.html)
17. WDNR [Wisconsin Department of Natural Resources]. (2004). Aquatic life toxicity testing methods manual, 2nd ed., Editors; Kari, F., Diana, D., Steve, G., Eric, K., & Greg, S., Bureau of Watershed Management. State of Wisconsin , USA. 80pp
18. Makinde, G.E.O., Olaifa, F.E. & Banjo, O.T. (2015). Acute toxicity and histopathological changes in gill and liver of Catfish (*Clarias gariepinus*) juvenile exposed to 2, 4-D Amine (Herbex D SI), *Journal of Biology, Agriculture and Healthcare*, 5(4).
19. USEPA[United States Environmental Protection Agency] (2002). Methods for measuring the acute toxicity of effluents and receiving waters to freshwaters and marine organisms. pp. 266.
20. OECD[Organization for Economic Co-operation and Development] (1992). Guidelines for testing of chemicals, Fish acute toxicity test. pp. 29
21. APHA (1992). Standard methods for the examination of water and wastewater, 18th Edition, American Public Health Association (APHA), American Water Works Association (AWWA) , Water Environment Federation (WEF), editors, Greenberg, A.E., Eaton, A.D & Clesceri , L.S., 1015 Fifteenth Street , NW , Washington , DC 20005.
22. Samabaswa, K.S. & Rao, K. R. (1985). Toxicity of Elsan to the Indian snakehead(*Channa punctatus*).*Indian Journal of Fisheries*, 3:153-159.
23. Ayotunde, E. O., Ofem, B. O., Okey, I. B., Ikpi, G. U., Ochang, S. N., Agbam, N. E. & Omini, D. O. (2010). Toxicity of pawpaw (*Carica papaya*) seed provided to sharp-tooth catfish *Clarias gariepinus* fingerlings and effects on haematological parameters. *International Journal of Fisheries and Aquaculture*, 2:71-78
24. Cagauan, A. G., Galaites, M. C. & Fajardo, L. J. (2004). Evaluation of botanical piscicides on nile tilapia (*Oreochromis niloticus*) and mosquito fish (*Gambusia affinis*). Proceedings of the 6th International Symposium on tilapia in aquaculture, September 12-16, Manila, Philippines, American Tilapia Association and Philippine Bureau of Fisheries and Aquatic Resources, 179-187.

25. Baden S.P. (1982). Oxygen consumption rate of shrimp exposed to crude oil extract. *Marine Pollution Bulletin*, 13(7): 230-233.
26. Boyd, C.E. & Lichthoppler, F. (1979). Water quality management in fish pond culture Research and development series No. 22. International center for aquacultural experimentation, Auburn University, Auburn Alabama. p.183.
27. Chavin, W.(1973).Teleostean endocrine and para-endocrine alteration of utility in environmental studies. In: Chavin W. (Editors). Response of fish to environmental change. Thomas Springfield, IL: 199-238.
28. Segner H. & Braunbeck T. (1988). Hepatocellular adaptation to extreme nutritional conditions in *Idus melanotus* L (Cyprinidae). A morphofunctional analysis. *Fish Physiology and Biochemistry* 5:79-97.
29. Dutta, H. M., Adhikari, N. K., Singh, P. K. & Munshi, J. S. (1993), Histopathological changes induced by malathion in the liver of a freshwater catfish, *Heteropneustes fossilis* (Bloch). *B. Environ. Contam.Tox.*, 51: 895-900.
30. Rodrigues, E. L. & Fanta, E. (1998). Liver histopathology of the fish *Brachydanio rerio* after acute exposure to sublethal levels of the organophosphate dimethoate 500. *Revista Brasileira de Zoologia*, 15, 441-450 (English abstract only).
31. Gingerich W.H. (1982). Hepatic toxicology of fishes. In: *Aquatic toxicology*. (LJ Weber, Ed), pp. 55-105. Raven Press, New York.
32. Vaillant, C., Le Guellec, C., Pakdel, F., & Valotaire, Y. (1988). Vitellogenin gene expression in primary culture of male rainbow trout hepatocytes. *General and Comparative Endocrinology* 70 ,284-290.
33. Fernandes, M.N. & Mazon, A. F. (2003). "Environmental Pollution and fish gill morphology. In: Val, A.L. Kapoor, B.G. (Eds.). *Fish adaptations science publishers*, Enfield, USA, pp 203-231.
34. Gabriel,U.U., Obomanu, F.G. & Edori, O.S. (2010). Biochemical changes in hybrid cat fish (*Heterobranchus bidorsalis*, *Clarias gariepinus*) treated with Nuacron. *Chinese Journal of Applied Environmental Biology* 16 (3):353 – 357.
35. Richmonds, C. & Dutta, H. M. (1989). Histopathological changes induced by malathion in the gills of Bluegill *Leopomis microchirus*. *Bulletin of Environmental contamination and toxicology*, 43:123-130.
36. Mallat, J. (1985). Fish gills structural changes induced by toxicants and other irritants: a statistical review. *Canadian Journal of Fisheries and Aquatic Sciences*, 42:630-648.
37. Alazemi, B. M., Lewis J. W.& Andrews, E. B. (1996). Gills damage in freshwater fish *Gnathonemus petersii* exposed to selected pollutants: an ultrastructural study. *Environmental Technology*, 17:225-238.

UNDER PEER REVIEW