

**POTENTIAL PROTECTIVE EFFECT OF *ANACARDIUM OCCIDENTALE*  
AGAINST PARACETAMOL-INDUCED HEPATOTOXICITY**

**ABSTRACT**

This study investigates the protective effects of ethanolic extract of *Anacardium occidentale* on paracetamol induced liver toxicity in Wistar rats. Twenty five (25) female Wistar rats were randomly divided into five (5) groups of five (5) rats each. The groups were designated as follows; A, B, C, D and E. Group A served as the normal control, group B served as the negative control and received 1000 mg/kg of paracetamol only, group C received 1000 mg/kg of paracetamol then treated with 250 mg/kg of *A. occidentale* extract, group D received 1000 mg/kg of paracetamol then treated with 500 mg/kg of *A. occidentale* extract and group E received 1000 mg/kg of paracetamol together with 500 mg/kg of the extract for 4 weeks respectively. After the last day of administration, the rats were anaesthetized using ketamine and the liver tissues were harvested and sent for histopathological examination. The result revealed significant ( $P < 0.05$ ) decrease in body weight of tested groups compared to their controls after paracetamol administration. The histopathological findings revealed severe focal aggregation of inflammatory cells (SFAIC), severe hepatocellular necrosis in the negative control and showed regeneration of hepatic tissues, which was more significant in the group that received high dose of extract (500 mg/kg). It can be deduced that the ethanolic extract of *A. occidentale* has protective effect against liver toxicity and should be recommended as an alternative traditional treatment.

**Keywords:** *Anacardium occidentale*, paracetamol, liver, acetaminophen, Wistar rats

**1. INTRODUCTION**

Paracetamol, also known as acetaminophen, is the most widely used over the counter medication to treat pain and fever [1]. It is a common analgesic used worldwide and is the first step on the World Health Organization (WHO) pain ladder [2]. Its mechanism of action is unknown; however, recent studies demonstrate that paracetamol inhibits the production of prostaglandin within the central

nervous system and peripheral tissues [3]. The use of paracetamol has been generally considered safe when consumed to the maximum recommended dosage of 4g/day than other commonly used analgesics like the opiates and non-steroidal anti-inflammatory drugs (NSAIDs); but its safety and efficacy has been questioned [4]. Paracetamol toxicity is one of the leading causes of intentional and unintentional poisoning in the United State which could be attributed to its availability as both a single ingredient and in combination with other medications in various concentrations [5]. Its toxicity could also result from either acute or chronic overdose. Hepatotoxicity is a consequence of overconsumption of paracetamol which could result to abnormalities in liver function, acute liver failure and sometimes death [6]. Paracetamol could also cause skin reactions such as steven-Johnson syndrome, kidney cancer [7] and increased risk of childhood asthma during pregnancy [8].

*A. occidentale* (commonly called cashew) is a well-known member of the *Anacardiaceae* family. Although, poisonous plants are ubiquitous, herbal medicine is used by up to 80% of the population in the developing countries [9]. It is widely cultivated in the subtropical and tropical countries of the world and is used in the tropics for the treatment of diarrhoea and coli, the extract of the leaf has been used to lower blood pressure and sugar [10]. In the traditional Nigerian and Brazilian pharmacopoeia, stem bark of *A. occidentale* is known for its anti-inflammatory effects [11,12]. The leaves of *A. occidentale* have been reported to possess phytoconstituents such as saponins, tannins and flavonoids, which exerts antioxidant activities [13]. The seeds are consumed orally in Columbia as aphrodisiac and to cure impotency and also used as anti-venom for snake bites [14]. It has also been found to have pharmacological effect such as anti-ulcerogenic [15], antihyperglycaemic [16] and anti-diabetic properties [17].

The existing management of liver toxicity using orthodox and various methods of medications are very expensive which require prolong use and sometimes are accompanied with serious side effects. However, medicinal plants seem inexpensive and very assessable with little or no side effects. Thus, this study aimed at evaluating the hepatoprotective activity of ethanolic extract of *A. occidentale* leaves on paracetamol induced toxicity.

## 55 **2. Materials and Methods**

### 56 **2.1 Materials**

#### 57 **2.1.1. Preparation of the plants extract**

58 Fresh leaves of cashew were collected from Uli, Anambra state, Nigeria and washed in a basin of  
59 water to remove dirt and debris. The leaves were dried under ambient room temperature after which it  
60 was grounded using laboratory mill into coarse form. 50 g of the coarse powder was macerated in 250  
61 mls of ethanol for 72 hours and then filtered using a filter paper. The filtrate was concentrated using a  
62 rotary evaporator and further dried using thermostat oven into a gel-like form.

#### 63 **2.1.2. Chemical reagents**

64 The chemicals for this study were purchased from Emmy enterprise, Onitsha, Anambra State.  
65 Paracetamol manufactured by Emzor was procured from the pharmaceutical unit of Chukwuemeka  
66 Odumegwu Ojukwu University while 10% formal saline was from the histopathology section of the  
67 college of medicine, Chukwuemeka Odumegwu Ojukwu University.

#### 68 **2.1.3 Ethical approval**

69 Ethical clearance was obtained from the research and ethics committee of the Faculty of Basic  
70 Medical Sciences, Chukwuemeka Odumegwu Ojukwu University, Nigeria. The animals were treated  
71 in line with the National Institute for Health Guide on the Care and Use of Laboratory Animals (1985).

#### 72 **2.1.4 Animals**

73 Twenty five (25) healthy female Wistar rats weighing about 100 to 190 g were purchased from Chris  
74 Animal farm, Nwakpadolu estate, G.R.A Awka, Anambra State and were transferred to the animal  
75 house of the Department of Anatomy, Faculty of Basic Medical Science, Chukwuemeka Odumegwu  
76 Ojukwu University, Uli, Anambra State. They were then housed in standard cages under normal  
77 temperature (27-30 °C) and fed with guinea feed (produced by Grand Cereals Ltd.) and water *ad*  
78 *libitum*. The animals were allowed to acclimatize for a period of two weeks before administration.

79

## 80     **2.2 Experimental procedure**

81     The animals were weighed using digital balance before commencement of administration and after  
82     the last day of administration.

### 83     **2.2.1. Induction of toxicity**

84     Twenty rats were induced with toxicity. 1000 mg of paracetamol was dissolved in 100 ml of distilled  
85     water to give a concentration 10 mg/ml.

### 86     **2.2.2. Experimental design**

87     The rats were randomly divided into five (5) groups of five rats each (n=5) designated as groups A, B,  
88     C, D and E. The extracts were given orally with the use of an oral intubation tube between the hours  
89     of 11 am-1 pm. The breakdown of the treatment of each group is as follows;

90     GROUP A (Normal control): Fed with rat feed and water

91     GROUP B (Negative control): Administered 1000 mg/kg body weight of paracetamol only for three  
92     days, with normal feed and water.

93     GROUP C: Administered 1000 mg/kg body weight of paracetamol only for three days and then  
94     treated with 250 mg/kg body weight of the extract.

95     GROUP D: Administered 1000 mg/kg body weight of paracetamol only for three days and then  
96     treated with 500 mg/kg body weight of the extract.

97     GROUP E: Administered 1000mg/kg body weight of paracetamol and 500 mg/kg body weight of the  
98     extract concurrently.

99     The administration was given orally, once daily between the hours of 11am and 1pm for a period of 28  
100     days. On the 29<sup>th</sup> day, the animals were anesthetized by the injection of ketamine and dissected. The  
101     liver was harvested and fixed in 10% formal saline for histological examination.

### 102     **2.2.3 Histological examination**

103     The livers harvested from the animals were fixed in 10% formal saline. The tissues were processed  
104     by passing them through ascending grades of alcohol and then cleared in xylene after which  
105     embedding in paraffin wax was carried out. Sections of about 3-5  $\mu$ m was obtained using rotatory

microtome which were later deparaffinised, hydrated and stained using haematoxylin and eosin (H&E) dye. The tissues were then mounted using neutral dibutylphthalate xylene (DPX) medium for microscopic examination at x600 magnification.

#### 2.2.4 Statistical analysis

Data were analysed using students't-test, with values expressed as Mean  $\pm$  SEM (Standard Error of Mean). It was done with the use of Statistical Package for Social Sciences (SPSS) software (Version 20). Differences between means were considered at  $P < 0.05$ .

### 3. RESULTS

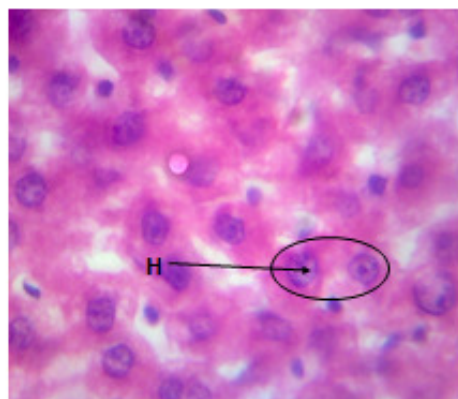
#### 3.1 Body weight change

**Table 1.** Effect of ethanolic extract of *A. occidentale* leaves on body weight of paracetamol induced toxicity rats

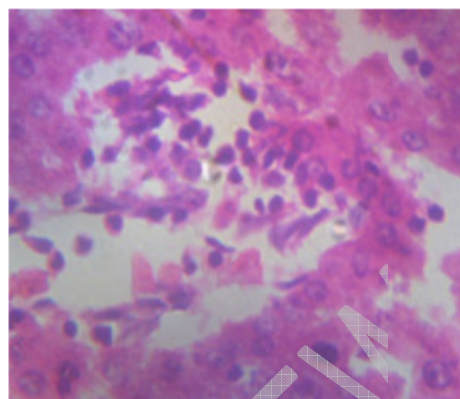
		MEAN	$\pm$ SEM	P-VALUE	T-VALUE
Group A	Initial	116.66	$\pm 8.81$		
	Final	170.00	$\pm 10.00$	0.004**	-16.000
Group B	Initial	150.00	$\pm 5.77$		
	Final	120.00	$\pm 5.77$	0.035*	5.196
Group C	Initial	140.00	$\pm 5.77$		
	Final	113.33	$\pm 3.33$	0.015*	8.000
Group D	Initial	153.33	$\pm 8.81$		
	Final	120.00	$\pm 5.77$	0.038*	5.000
Group E	Initial	190.00	$\pm 5.77$		
	Final	156.66	$\pm 3.33$	0.038*	5.000

Values are expressed as Mean  $\pm$  SEM, \* $P < 0.05$ , \*\*  $P < 0.01$ , final body weight compared to initial body weight.

#### 3.2 Histopathological findings

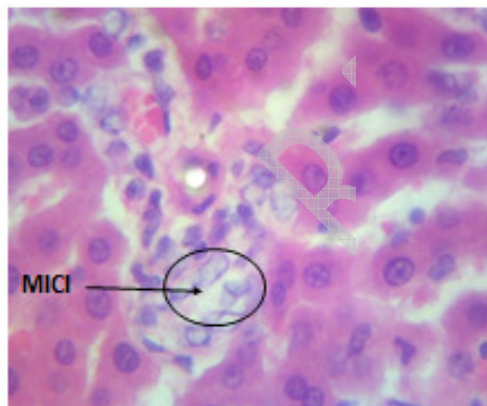


**Plate A:** Photomicrograph of the normal control section of the liver of rats administered with distilled water only showing normal Hepatocyte (H) and cytoarchitecture.

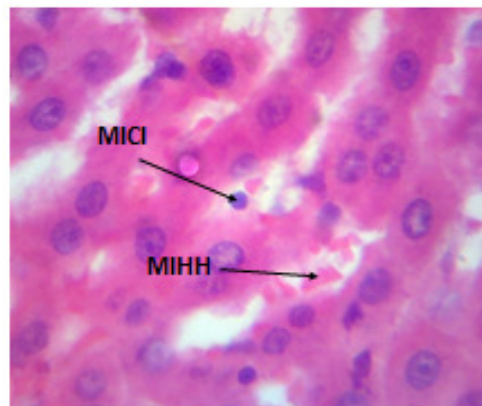


**Plate B:** Photomicrograph of liver tissue of rats administered with 1000 mg/kg of paracetamol only group showing severe focal aggregate of inflammation cells (SFAIC), cytoplasmic ground glass appearance (CGGA) and severe hepatocellular necrosis (HCN).

119



**Plate C:** Photomicrograph of liver tissue of rats administered with 1000 mg/kg of paracetamol and treated with 250 mg/kg of the extract showing moderate regenerated hepatic tissue with moderate inflammatory cell infiltration (MICI) and mild intrahepatic hemorrhage (MIHH).



**Plate D:** Photomicrograph of liver tissue of rats administered with 1000 mg/kg of paracetamol and treated with 500 mg/kg of the extract showing well regenerated hepatic tissue with mild inflammatory cell infiltration (MICI) and mild intrahepatic hemorrhage (MIHH).

120

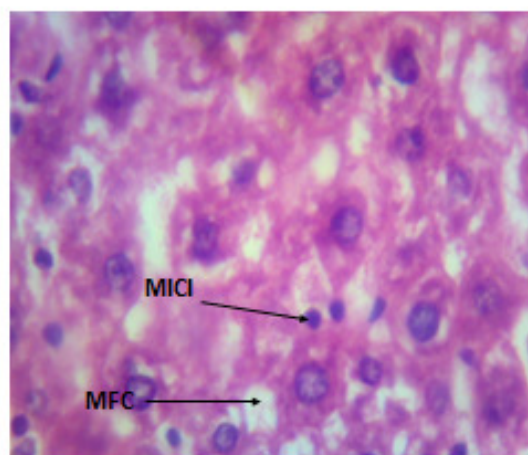


Plate E: Photomicrograph of liver tissue of rats administered with 1000 mg/kg of paracetamol and 500 mg/kg of the extract showing moderate cytoarchitectural regeneration with moderate inflammatory cell infiltration (MICI) and mild fatty changes(MFC).

#### 4. DISCUSSION

The use of plants has shown promising effect in the treatment and management of diseases and toxicity. This is due to the presence of potent bioactive compounds in the plant which have anti-hepatotoxic properties [18].

Findings from this study revealed a significant increase in body weight of the group A animals. However, there was a significant loss of body weight in groups B, C, D and E. The increase in body weight could be physiological as the animals were only exposed to water and feed throughout the study. The reduction in body weight could be as a result of exposure to toxicity or due to loss of appetite by the animals. This is in line with that of Jaouad, 2004 who reported a significant decrease in body weight of rats when administered 225 mg/kg of paracetamol. The groups treated with the extract also showed reduction in weight and could be as a result of the action of anacardiac acid which is a component of the extract that has been found to reduce the deposition of fat by its uncoupling action [19]. This corresponds with the study of Dare et al [20].

Histopathological study of toxicity induced untreated rats showed severe histopathological changes on the hepatic tissue which was due to the paracetamol used in the study. This corresponds with previous report by [21]. The histological study of the treated groups (C, D and E) showed regenerative effect of the liver tissues. *A. occidentale* may possess antioxidant properties that are related to their ability to inhibit peroxidative damage caused by environmental toxicants [22,23]. Higher dose of the extract showed greater restorative effect of the liver tissue than lower dose of the extract. This protective effect is in agreement with previous report [24].

## 5. CONCLUSION

Findings from this study indicate that consumption of ethanolic extract of *A. occidentale* leaf possess hepatoprotective effects on the liver against paracetamol induced toxicity. It should therefore be recommended in the management of liver disorders.

## ACKNOWLEDGMENT

None

## COMPETING INTERESTS

Authors have declared that no competing interests exist

## ETHICAL APPROVAL

All authors hereby declare that principles of laboratory animal care (NIH publication No. 85-23, revised 1985) were followed as well as specific national laws where applicable. All experiments have been examined and approved by the appropriate ethics committee.

## REFERENCES

1. Blieden M, Paramore LC, Shah D, et al. A perspective on the epidemiology of acetaminophen exposure and toxicity in the United States. *Expert Rev Clin Pharmacol* 2014;3:341–8.
2. Jordan KM, Arden NK, Doherty M, et al. EULAR Recommendations 2003: an evidence based approach to the management of knee osteoarthritis: Report of a Task Force of the Standing Committee for International Clinical Studies Including Therapeutic Trials (ESCISIT). *Ann Rheum Dis*. 2003;62:1145–55.
3. Hinz B and Brune K. Paracetamol and cyclooxygenase inhibition: is there a cause for concern? *Ann Rheum Dis* 2012;71:20–5.



4. Larson AM, Polson J, Fontana RJ, et al. Acetaminophen-induced acute liver failure: results of a United States multicentre, prospective study. *Hepatology*. 2001;42(6):1364–72.
5. Bronstein AC and Spyker DA, Cantilena LR et al. 2011 annual report of the American Association of Poison Control Centers' National Poison Data System (NPDS): 29<sup>th</sup> annual report. *Clin Toxicol*. 2012;50:911-1164.
6. Chun LJ, Tong MJ, Busuttill RW et al. Acetaminophen hepatotoxicity and acute liver failure. *J Clin Gastroenterol*. 2009;43:342-349.
7. Choueiri TK, Je Y, Cho E. analgesic use and the risk of kidney cancer: a meta-analysis of epidemiologic studies. *International Journal of Cancer*. 2014;134(2):384-396.
8. Evers S, Weatherall M, Jefferies S, Beasley R. paracetamol in pregnancy and the risk of wheezing in offspring: a systematic review and meta-analysis. *Clinical and Experimental Allergy*. 2011;41(4):482-489.
9. Jaouad EH, Israili ZH, Lyoussi B. Acute toxicity and chronic toxicological studies of *Ajuga iva* in experimental animals. *J Ethnopharm*. 2004;91:43–50.
10. Esimone CO, Okonta JM, Ezugwu CO. Blood sugar lowering effect on *Anacardium occidentale* leaf extract in experimental rabbit model. *J Nat Remed*. 2001;1:60-3.
11. Mota ML. Anti-inflammatory actions of tannins isolated from the bark of *Anacardium occidentale* . *J. Ethnopharmacol*. 1985;13:289-300.
12. Ojewole JA. Laboratory evaluation of hypoglycemic effect of *Anacardium occidentale* Linn (Anacardiaceae) stem-bark extracts in rats. *Methods Find Exp Clin Pharmacol*. 2003;25(3):199–204.
13. Jaiswal YS, Tatke PA, Gabhe SY, Vaidya A. Antioxidant Activity of Various Extracts of Leaves of *Anacardium occidentale* (Cashew). *Research Journal of Pharmaceutical, Biological and Chemical Sciences*. 2010;4:112-119.
14. Orwa C, Mutua A, Kindt R, Jamnadass R, Anthony S. Agroforestry Database: a tree reference and selection guide version 4.0. World Agroforestry Centre, Kenya. 2009.
15. Konan NA. Antiulcerogenic effect and acute toxicity of a hydroethanolic extract from the cashew (*Anacardium occidentale* L.) leaves. *J Ethnopharmacol*. 2007;112(2):237-42.

16. Tedong L. Antihyperglycemic and renal protective activities of *Anacardium occidentale* (Anacardiaceae) leaves in streptozotocin induced diabetic rats. *Afr J Trad CAM*. 2007;3(1):23–35.
17. Kamtchouing P. Protective role of *A. occidentale* extract against streptozotocin-induced diabetes in rats. *J Ethnopharmacol*. 2001;65:95–99.
18. Biswas K, Kumar A, Babaria BA, Prabhu K, Ramachandra SS. Hepatoprotective effect of leaves of *Peltophorum pterocarpum* against paracetamol induced acute liver damage in rats. *J Basic Clin Pharm*. 2010;1:10-5.
19. Toyomizu M, Okamoto K, Ishibash T, Nakatsu T, Akiba Y. Reducing effect of dietary anacardic acid on body fat pads in rats. *Ani. Sci. J.*, 2003;74(6): 499-504.
20. Dare SS, Hamman WO, Musa S, Goji ADT, Oyewale AA, Abba S, Ezekiel I. Effects of Aqueous Extract of *Anacardium occidentale* (Cashew) Leaf on Pregnancy Outcome of Wistar Rats nt. *J. Anim. Veter. Adv*. 2011;3(2): 77-82.
21. Galal RM, Zaki HF, Seif El-Nasr MM, Agha AM. Potential protective effect of honey against paracetamol-induced hepatotoxicity. *Arch Iran Med*. 2012;15(11):674-680.
22. Sahreen S, Khan MR, Khan RA. Evaluation of antioxidant activities of various solvent extracts of *Carissa opaca* fruits. *Food Chem*. 2010;122:1205-11.
23. Faure M, Lissi E, Torres R, Vidella L. Antioxidant activities of lignan and flavonoids. *Phytochemistry*. 1990;29:3773-5.
24. Daniel I, Coston P, Abel N. A. (2014) Hepatoprotective Effect of Methanolic Leaf Extract of *Anacardium occidentale* (Cashew) on Carbon-Tetrachloride-Induced Liver Toxicity in Wistar Rats. *Sub-Saharan African Journal of Medicine*. 2014;1(3):124-131.