

## **Case study**

Pregnancy-related severe hypertriglyceridemia with genetic susceptibility presenting as acute pancreatitis

## **Abstract**

Pregnancy in healthy women is associated with normal changes in lipid metabolism that are essential for fetal growth and development. Hyperlipidemia as a cause of pancreatitis as well as severe hyperlipidemia in pregnancy is not commonly seen in clinical practice. Acute pain abdomen in a pregnant woman near term is almost always related to labor. However, sometimes it could be a presenting feature of some other abdominal pathology. We report a case of acute pancreatitis due to severe hyperlipidemia in a pregnant woman diagnosed after receiving an alert from laboratory of highly lipemic serum. The presentation, management and outcome of the case are discussed.

## **Keywords**

Hyperlipidemias, Pregnancy-Induced, Lipemic serum, Pregnancy outcome, Risk Factors, Pancreatitis.

## **Introduction**

Pregnancy in healthy women is associated with normal changes in lipid metabolism and increase in lipid concentration that are essential for fetal growth and development [1,2]. It is known that total cholesterol (TC) and triglycerides (TG) rise throughout pregnancy. TG, however, rise disproportionately reaching two to four times pre-pregnancy levels by the third trimester [1]. However, these changes fall to pre-pregnancy levels following delivery [1,3]. Pregnancy is also associated with alterations in the composition and size of LDL particles. Previous studies have demonstrated that as TG levels increase, there is a decrease in overall LDL size with an increased proportion of smaller, denser LDL particles that are thought to be more atherogenic [3].

A subset of pregnant women with gestational hypertension, diabetes, and/or preeclampsia have more marked derangement of lipid profiles. The ABCD study showed that atherogenic lipid profiles during the first trimester confer an increased risk of adverse pregnancy outcomes including maternal morbidity, mortality, and preterm delivery [2]. Pregnancy-related hypertriglyceridemia is rare, but it can be life threatening in some patients with genetic susceptibility [4]. Complications can include acute pancreatitis, hyperviscosity syndrome, and possibly preeclampsia [4].

The case discussed had severe hypertriglyceridemia diagnosed during third trimester and she did not have any features of preeclampsia, hyperviscosity syndrome, hypertension or diabetes mellitus. Her triglycerides and pre beta lipoprotein (VLDL) were very high with low LDL, HDL and undetectable lipoprotein A levels. We do not have her lipids value of pre-conception, first or second trimester as they were never done. acute pancreatitis due to severe hyperlipidemia in a pregnant woman diagnosed after receiving an alert from laboratory of highly lipemic serum. The presentation, management and outcome of the case are discussed

### **The Case**

A 31-yr-old G2P1, unbooked, second gravid female was admitted on 27.11.2018 at Fortis Escorts Hospital, Jaipur, for observation in view of abdominal pain and bad obstetric history. She had LSCS 3 ½ years back for severe PIH and oligohydromnios and was taking L Thyroxine 75ug daily since first month of her present pregnancy. She had no other co morbidity. She was previously healthy with no history of cholelithiasis, alcohol, inherited diseases, diabetes, nongestational hyperlipidemia or drug abuse. Her LMP was 13.03.2018 and EDD 20.12.2018. She was initially evaluated in March 2018 when she first visited for a routine gynaecological consult and her laboratory investigations are mentioned in Table 1. Her LFT were normal except for hypoalbuminemia for which she was prescribed high protein diet along with protein supplements. Status of her lipid profile was not known and she had no known family history of dyslipidemia, coronary artery disease (CAD), diabetes mellitus (DM) or hypertension (HT).

She reported on 28.11.2018 with peri-umbilical pain. The pain was initially in right upper abdominal quadrant and flank for last 6 days and she also had vomiting for initial two days of her symptoms. She also had mild epigastric and back discomfort and post prandial pain. She was admitted for further evaluation and routine biochemistry were ordered. Her body temperature was 98.6 °F, blood pressure 120/70 mmHg, heart rate 84 bpm, SpO2 96% on air and respiration 16 bpm. Physical examination showed normal breath sounds and mild subxiphoid tenderness without Grey Turner's or Cullen's sign. Rest of her general and systemic examination was unremarkable. An alert was received from the laboratory that her serum is milky (Figure 1) and is causing analytical interference in certain tests. Her prothrombin time, transaminases, serum bilirubin and GGT could not be done because of grossly lipemic serum (results invalid). However, manual PT-INR was done and was reported to be mildly raised. Her investigations are mentioned in table 1 and 2.

Laboratory examination revealed amylase was 560 U/L; lipase was 720 U/L and blood glucose 83 mg/dl. Serum Triglyceride was 6511 mg/dl, VLDL 1302.2 mg/dl and total cholesterol was 905 mg/dl. Ultrasound abdomen did not reveal any sonographic findings consistent with acute pancreatitis. A single viable fetus with cephalic presentation of gestational age 37 weeks was present. Computerized Tomography scan of abdomen was not done. The diagnosis of acute pancreatitis secondary to severe hypertriglyceridemia was made and she was managed conservatively. However her abdominal pain was not after the treatment of abrosia, intravenous nutritional support, hydration, proton pump inhibitors - rabeprazole , ondansetron ,lipid lowering agents gemfi brozil , fenofibrate, and omega 3 fatty acid. Lower section cesarean section (LSCS) delivery was planned.

After correcting PT-INR with fresh frozen plasma ,a cesarean delivery was planned performed under spinal anesthesia in view of previous bad obstetric history , previous LSCS , scar tenderness, subclinical acute pancreatitis, and severe hyperlipidemia. A male infant weighing 3.252 kg was delivered successfully. The baby cried immediately after birth .Intraoperative findings included thick and milky white blood as shown in Figure 2. There was no ascites. The patient was shifted to floors and discharged on 03.12.2018. She was lost to follow-up.

### **Discussion**

Hypertriglyceridemia (HTG) is a important cause of pancreatitis and severe HTG is uncommon in pregnancy[5,6] . The risk of developing HTG-induced pancreatitis (HTGP) is approximately 5 percent with serum triglycerides >1000 mg/dL and 10 to 20 percent with triglycerides >2000 mg/dL [7]. The case discussed had HTG with serum TG 6511 mg/dl. Early clinical recognition of (HTGP) is important to provide appropriate therapy and to prevent further episodes [8-10]. In the present case abdominal pain and raised serum levels of pancreatic enzymes to more than three times the upper limit of normal confirmed acute pancreatitis.

Patients usually have pre-existing genetic defects or diseases that can compromise lipid metabolism [11]. Though we could not get her parents lipid profile checked, her brother had dydlipidemia with raised total cholesterol, triglycerides and VLDL levels suggesting underlying genetic susceptibility. Since pregnancy associated HTG is so rare, and because pathogenesis of acute hyperlipidemic pancreatitis in pregnancy is still under research and there is a incomplete understanding of the diverse genetic factors that predispose to this condition, screening these patients genetically is not recommended at this time [4]. However,

the risk of developing severe pregnancy-associated HTG should be considered in a woman whose Pre-pregnancy fasting TG level exceeds 4 mmol/liter. In most of the women of child bearing age no routine lipid profile is done in clinical practice and in almost all pregnant women there is no such report when they come for the first consultation. A family history of dyslipidemia, features of metabolic syndrome (such as obesity, diabetes mellitus, or hypertension), or past history of non-gallstone pancreatitis should work as a trigger for lipid profile determination [4]. No such features were there in the case presented. In the present case we could diagnose hypertriglyceridemia after receiving an alert from the laboratory and then thought of possible pancreatitis. Does this mean that all abdominal pains at term are not labor pains and one should have all possible differentials in mind.

Early diagnosis and prompt intervention are proved to be life-saving in these patients. Management Principles include multidisciplinary care team, low-fat diet, nutritional fat supplements to prevent essential fatty acids deficiency, fibrates, niacin-based preparations and Therapeutic plasma exchange or lipid apheresis. Treatment of acute hyperlipidemic pancreatitis should be non-operative in addition to appropriate timing, indications for surgery and operative procedures should follow the principles of minimally invasive surgery [12,13]. Few studies have reported pregnancy-associated hyperlipidemic pancreatitis complicated with chylous ascites [14]. We managed the patient with supportive care, low fat diet (less than 20% of calories from fat), topical sunflower oil (to prevent EFA deficiency), nutritional supplement with omega 3 fatty acids, and fibrates (gemfibrozil 600 mg twice daily and fenofibrate 145 mg once daily). She did not had any ascites or other organ dysfunction. Later cesarean delivery was planned performed under spinal anesthesia in view of previous bad obstetric history, previous LSCS, scar tenderness, acute pancreatitis, and severe hyperlipidemia. She was discharged on low fat diet, nutritional supplements and fibrates. She was lost to follow-up.

To conclude pregnancy does represents a unique opportunity for the detection of subclinical dyslipidemia. All pregnant women with family history of hypertension, dysglycemia, dyslipidemia, coronary artery disease, previous LSCS or bad obstetric history and features of metabolic syndrome should be evaluated at earliest for hyperlipidemia.

Consent: Done

## **References:**

- 1.Hadden DR, McLaughlin C. Normal and abnormal maternal metabolism during pregnancy. *Semin Fetal Neonatal Med* 2009;14(6):401.
- 2.Vrijkotte TG, Krukziener N, Hutten BA, et al. Maternal lipid profile during early pregnancy and pregnancy complications and outcomes: the ABCD study. *J Clin Endocrinol Metab* 2012;97(11):3917-25
- 3.Belo L, Caslake M, Gaffney D, et al. Changes in LDL size and HDL concentration in normal and preeclamptic pregnancies. *Atherosclerosis* 2001;162:425-32.
- 4.Alyse S. Goldberg and Robert A. Hegele. Severe Hypertriglyceridemia in Pregnancy. *J Clin Endocrinol Metab*, August 2012, 97(8):2589–2596.
- 5.Serpytis M, Karosas V, Tamosauskas R, Dementaviciene J, Strupas K, Sileikis A, et al. Hypertriglyceridemia-induced acute pancreatitis in pregnancy. *JOP* 2012; 13: 677–680.
- 6.Yadav D, Pitchumoni CS. Issues in hyperlipidemic pancreatitis. *J Clin Gastroenterol* 2003; 36: 54–62.
- 7.Scherer J, Singh VP, Pitchumoni CS, Yadav D. Issues in hypertriglyceridemic pancreatitis: an update. *J Clin Gastroenterol* 2014; 48:195.
- 8.Zhu Y, Pan X, Zeng H, et al. A Study on the Etiology, Severity, and Mortality of 3260 Patients With Acute Pancreatitis According to the Revised Atlanta Classification in Jiangxi, China Over an 8-Year Period. *Pancreas* 2017; 46:504.
- 9.Koutroumpakis E, Slivka A, Furlan A, et al. Management and outcomes of acute pancreatitis patients over the last decade: A US tertiary-center experience. *Pancreatology* 2017; 17:32.
- 10.Berglund L, Brunzell JD, Goldberg AC, et al. Evaluation and treatment of hypertriglyceridemia: an Endocrine Society clinical practice guideline. *J Clin Endocrinol Metab* 2012; 97:2969.
- 11.Eskandar O, Eckford S, Roberts TL. Severe, gestational, nonfamilial, non-genetic hypertriglyceridemia. *J Obstet Gynaecol Res* 2007; 33: 186–189.

12.Ying Hang, Yi Chen, Li-xiong Lu, Chang-qing Zhu. Acute hyperlipidemic pancreatitis in a pregnant woman. World J Emerg Med.2013;4(4):311-13.

13.Sun B, Xu DS, Jiang HC, Tai S, Cui YF, Xu J, et al. Study on combined therapy of hyperlipidemic severe acute pancreatitis. Zhonghua Wai Ke Za Zhi 2007; 45: 733–735.

14.Chuang SC, Lee KT, Wang SN, Kuo KK, Chen JS. Hypertriglyceridemia-associated acute pancreatitis with chylous ascites in pregnancy. J Formos Med Assoc 2006; 105: 583–587.

Table 1.Hematology and Biochemistry of case,infant and sibling (brother)

	Units/ Normal range	Case		Infant	Brother
Date		19.03.2018	28.11.2018	30.11.2018	01.12.2018
Hemoglobin	12-15 gm/dl	10.2	12.2		
TLC	4-10 x 10 <sup>3</sup> cells/cmm	13.0	6.2		
DLC	Neutrophil 40-80%	77	66		
	Lymphocyte 20-40%	17	26		
Platelet count	150-450 x 10 <sup>3</sup> cells/cmm	295	327		
Free T4	0.93-1.7 ng/dl		0.85		
TSH	0.27-4.2		3.940	9.430 (0.7-15.2 uIU/ml)	
AST	0-32 U/L	45	NA		
ALT	0-33 U/L	78	NA		
S.Albumin	3.2-5.0 gm/dl	1.7	2.6		
S.ALP	50-136 U/L	263	90		
LDH	81-234 U/L	213	122		
GGT	0-38 U/L	37	NA		
S.Amylase	28-100 U/L		560		
S.Lipase	13-60 U/L		720		

PT-INR	0.8-1.1	0.96	2.2		
aPTT	30-40 seconds	33.3	70		
Total Cholesterol	0-200 mg/dl		905	71	306
Triglycerides	0-200 mg/dl		6511		814
VLDL			1302.2		162.8
Direct LDL-C	0-100 mg/dl		23	37	167
HDL-C	42-88 mg/dl		36	25	36
S.Creatinine	0.7-1.2 mg/dl		0.28		

TLC:Total leucocyte count; DLC:Differential leucocyte count; Free T4:Free thyroxine; TSH:Thyroid stimulating hormone; AST:Aspartate aminotransferase; ALT:Alanine aminotransferase; S.ALP:Serum alkaline phosphatase; LDH:Lactic dehydrogenase; GGT:Gamma Glutamyl transferase  
PT-INR:Prothrombin time-international normalized rotia; aPTT:Activated partial thromboplastin time; VLDL:Very low density lipoproteins; LDL-C:Low density lipoprotein cholesterol; HDL-C:High density lipoprotein cholesterol.

Table 2:SerumLipoprotein Electrophoresis dated 02.12.2018

Test	Results	Normal range (unit)
Alpha Lipoprotein (HDL)	13.7	22.3 - 53.3 %
Pre-beta Lipoprotein (VLDL)	62.1	4.4 - 23.1 %
Beta Lipoprotein (LDL)	24.2	38.6 – 69.4
Lipoprotein (A)	< 2%	Not established

Note:Lipoprotein analysis show increased pre beta lipoprotein. Lipoprotein A is below detection limits.Chylomicrons present.

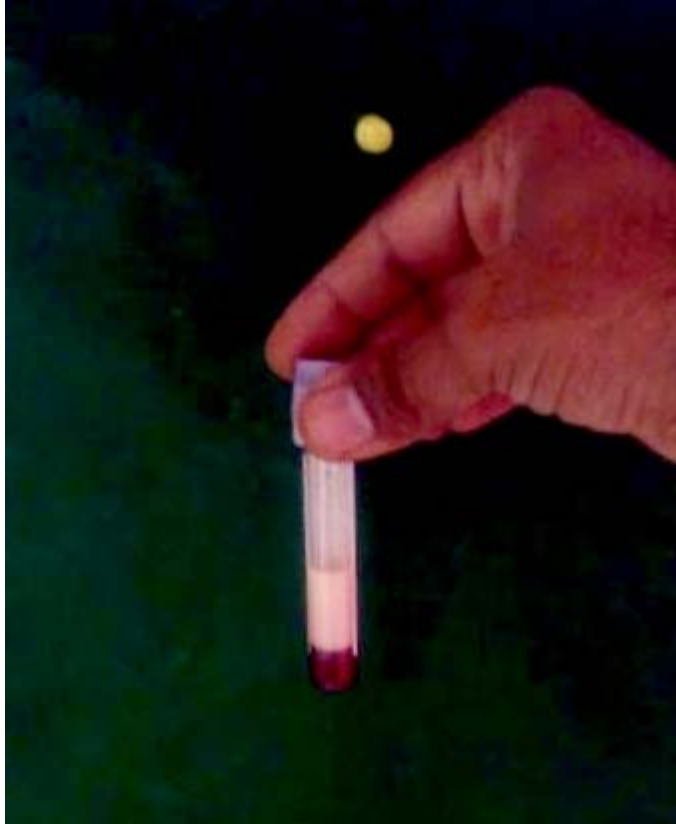

Figure1:Lipemic serum with a milky white appearance.



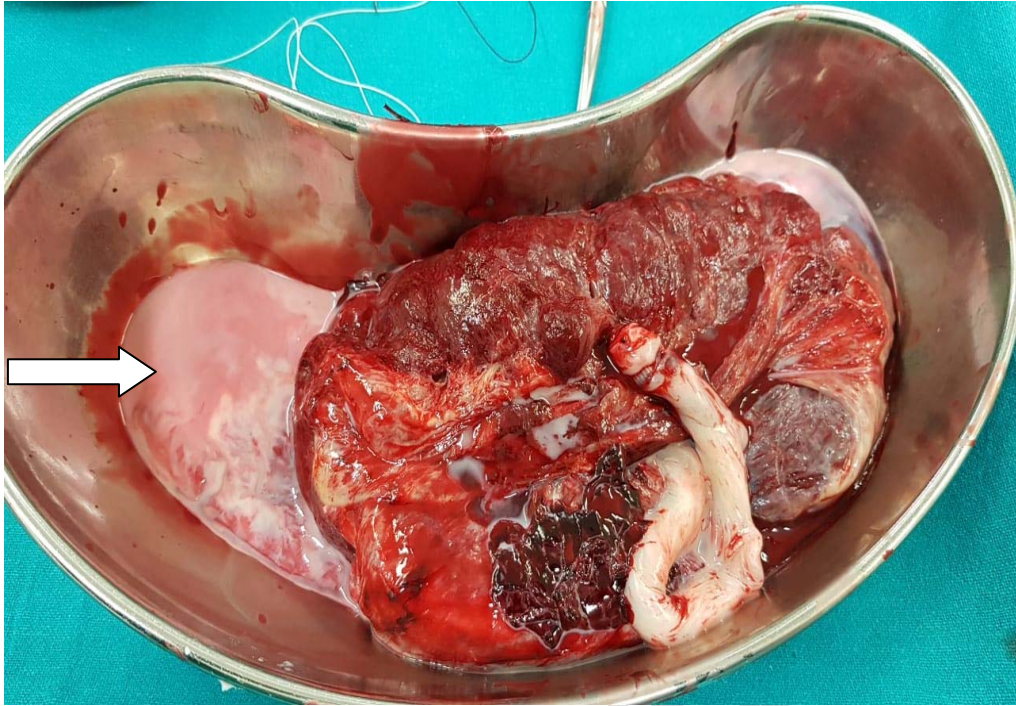


Figure 2: Placenta with lipemic blood (arrow) in kidney tray

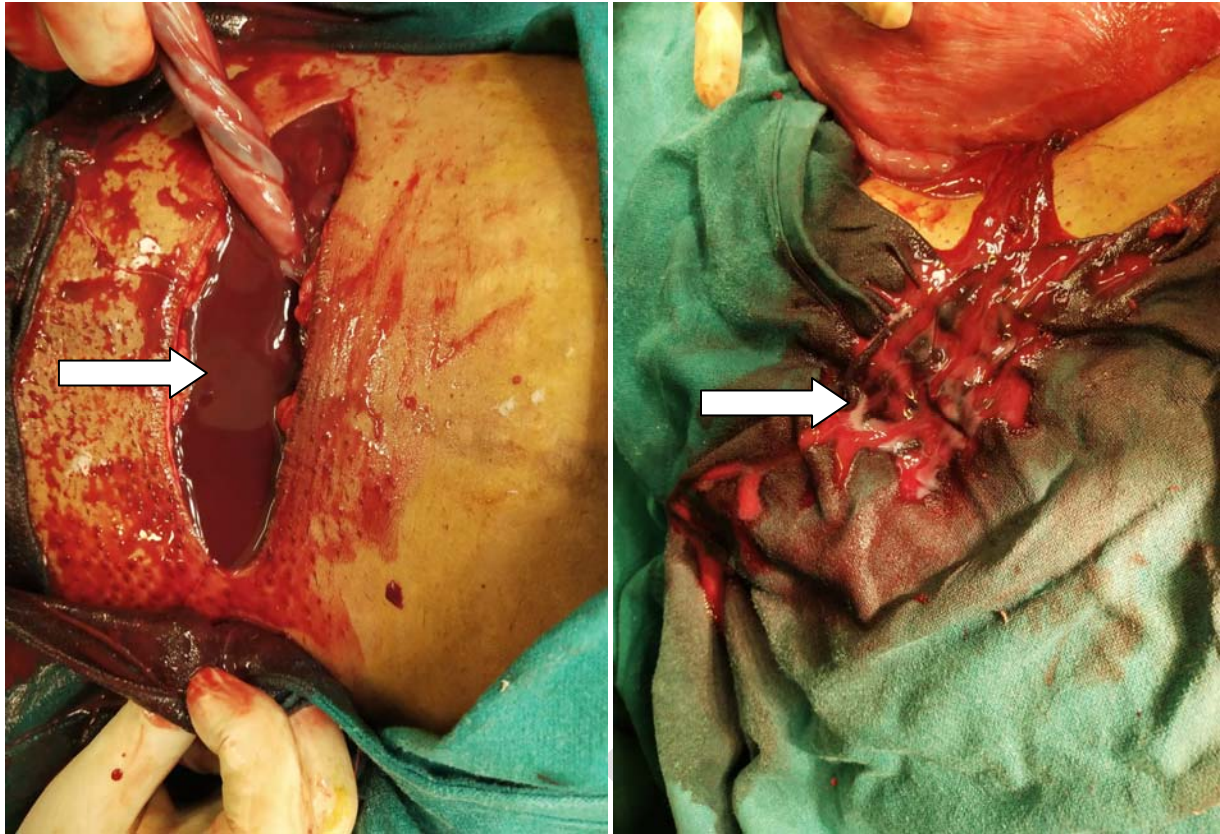


Figure 3 A and B: Blood showing lipemia (arrows)