

## **Investigation of Hepatoprotective and Antioxidant Activity of *Celosia argentea* Against Tissue Injury Caused by Rifampicin Administration**

### **ABSTRACT**

This study evaluated the antioxidant and possible protective effects of *Celosia argentea* against tissue injury caused by rifampicin administration. The antioxidant property of the aqueous extract of *C. argentea* was assessed in-vitro using DPPH and ABTS assays. The results obtained revealed the free radical scavenging ability of the extract against the radicals in a concentration-dependent manner. Administration of rifampicin to rats for 28 days induced a significant increase in the activities of alanine aminotransferase (ALT), aspartate aminotransferase (AST), alkaline phosphatase (ALP), and increase cholesterol levels in the plasma, liver and kidney while HDL cholesterol was decreased. It also elevated the levels of malondialdehyde and decreased SOD activities in the liver and kidney. However, co-administration of *C. argentea* extract to rifampicin treated rats significantly reversed all these rifampicin induced changes. The levels of AST, ALT, ALP and cholesterol in the plasma, liver and kidney were decreased while HDL cholesterol level was increased. In addition, SOD activity was elevated while malondialdehyde was depressed when compared to the rifampicin treated rats. The extract of *C. argentea* was found to be rich in phenolic content and was proved to have no toxic effects on rats when administered alone to normal rats at a dose level of 400mg/kg/day. Therefore, hepatoprotective and strong antioxidant properties of *C. argentea* demonstrated in this study indicated that the extract could be used in the management of rifampicin toxicity.

**Keywords:** Tissue injury, Rifampicin, *Celosia argentea*, malondialdehyde, hepatoprotective

## **Introduction**

Tuberculosis (TB) is one of the most common problems in undeveloped and developing countries [1]. It is the ninth principal cause of death worldwide and responsible for the death of 1.7 million people in 2016 alone [2]. Although the rate of new TB infection and mortality are decreasing by about 2% and 3% per year respectively not less than 16% of TB cases resulted in death [3]. Rifampicin which is an important drug used in the treatment of tuberculosis has been reported to induced hepatotoxicity has its main side effect [4]. It is on record that about 5–10% of TB patients that received treatment suffer from hepatotoxicity complication [5].

The mechanism of hepatotoxicity effect of TB drugs has been linked to their generation of reactive oxygen species (ROS) [6]. Therefore, hepatic toxicity and hepatitis are common features of rifampicin medication and this has been reported to caused steatosis and increased apoptosis of the hepatocytes and hepatic oxidative stress [7]. Though there is no suitable drug to weaken the hepatotoxicity effect of TB drugs presently [8], herbs are believed to possess potential hepatoprotective agents [9]. These plant extracts are known to improved antioxidant status which is usually depleted during treatment with TB drugs [10, 11]. Many synthetic antioxidants have been shown to produce toxic or mutagenic effects [12], therefore antioxidants from natural sources will be more appropriate for the prevention of TB drugs toxicity [13].

*Celosia argentea* L. is an annual herb that belongs to the amaranthaceae family. It has fascinating red flowers and dark green leaves. It is used in traditional medicine for its diuretic, antimitotic, antidiabetic, antihypertensive, anti-inflammatory and antitumor potentials [14, 15]. Phytochemical screenings of the plant detected the presence of phenols, flavonoids, alkaloids, saponins, tannins, terpenes, glycosides, fatty acids, amino acids, carbohydrates and steroids in previous studies [16, 17, 18]. The plant has been demonstrated to possess hepatoprotective, anti-tumour, anti-diarrhoea, anti-diabetes and anti-oxidant properties in several pharmacological studies [19, 20, 21].

Therefore, based on reported scientific and traditional evidence for hepatoprotective potential of *C. argentea*, this present study was designed to investigate the protective potential of aqueous extract of *C. argentea* against rifampicin-induced hepatotoxicity.

## **MATERIALS AND METHODS**

### **Reagents**

Trichloroacetic acid (TCA), Folin-Ciocalteu reagent, 6-Hydroxy-2,5,7,8-tetramethylchroman-2-carboxylic acid (Trolox), 2,2-Diphenyl-1-picrylhydrazyl (DPPH), 2,2-azino-bis (3-ethylbenzthiazoline-6-sulfonic acid) ABTS, gallic acid, thiobarbituric acid (TBA), nicotinamide adenine dinucleotide reduced (NADH) were obtained from Sigma–Aldrich Chemical Co. Ltd. (England). Rifampicin was obtained from (Ziel Medicare Ltd, India), while Nitrobluetetrazolium (NBT) was product of Fluka (Buchs, Switzerland). All other chemicals used were of analytical grade.

## **Plant material**

The fresh leaves of *C. argentea* were collected from the research farm of Faculty of Agricultural science, Ladoko Akintola University of Technology, Ogbomosho. The identification and authentication of the plant were done by Prof A.J. Ogunkunle at Department of Pure and Applied Biology, Ladoko Akintola University of Technology, Ogbomosho, where a specimen was deposited in the herbarium. The leaves were dried at room temperature and blended to a coarse powder.

## **Preparation of aqueous extract**

The powdered leaves of *C. argentea* (200g) were extracted with distilled water (1.2litres) overnight in a Soxhlet extractor. The aqueous extract was concentrated and evaporated to dryness at 50°C with a Vacuum air dryer to obtain a flake-type extract. The concentrated dried aqueous extract was then stored at -20°C before use.

## **Animal model and experimental design**

A total of twenty-five (25) male wistar strain albino rats with body weights between 200 and 220g were used in this experiment. They were housed in the Ladoko Akintola University of Technology, (LAUTECH) animal house. They were allowed fourteen (14) days to acclimatize before the commencement of the experiment. The animals were maintained on a standard pellet diet throughout the acclimatization and administration period. The rats were divided into five groups with each group comprising of five rats. Group 1 rats were given distilled water for 28 days and taken as control, group 2 rats received 400 mg/kg body weight of *C. argentea* extract only, group 3 rats received 100 mg/kg body weight of rifampicin only, group 4 rats received 100

mg/kg body weight of rifampicin plus 200 mg/kg body weight of *C. argentea* extract and group 5 rats received 100 mg/kg body weight of rifampicin plus 400 mg/kg body weight of *C. argentea* extract. The administration period for rifampicin and *C. argentea* extract was 28 days. At the end of the *C. argentea* treatment, blood was collected from the animals into heparinised tubes by cardiac puncture under light ether anaesthesia and after an overnight fast. Liver and kidney were removed from the animals for biochemical analyses. Blood samples were centrifuged to separate plasma and red blood cells. All samples were stored at -20°C until analysed.

### **The in-vitro antioxidant assay and total phenolic content determination**

Trolox Equivalent Antioxidant Capacity assay was performed essentially as described by Re *et al.*, [22] while DPPH (2,2-Diphenyl-1-picrylhydrazyl) radical scavenging activity assay was carried out as described by Schlesier *et al.*, [23]. The content of total phenolic compounds in *C. argentea* was determined by the Folin–Ciocalteu method as described by Miliauskaite *et al.* [24]. Details of all these assays are given as reported earlier [25, 26].

### **Preparation of liver and kidney homogenates**

Prior to biochemical analyses, the liver and kidney samples were cut into small pieces and homogenized in Phosphate buffer saline (PBS) with a homogenizer to give a 10 % (w/v) liver and kidney homogenate. The homogenates were then centrifuged at 12,000 rpm for 15 min. The supernatant obtained was used for the assay of superoxide dismutase, thiobarbituric acid reactive substances (TBARS) content, and protein estimation.

### **Determination of blood lipid profiles and ALP, AST, ALT activities in Plasma**

Plasma concentrations of total cholesterol, triglycerides, alkaline phosphatase (ALP), aspartate aminotransferase (AST), and alanine aminotransferase (ALT) were determined with commercial kits (CYPRESS® Diagnostics, Langdorp, Belgium). HDL cholesterol and triglycerides were determined in plasma with the same commercial kits for total cholesterol and triglycerides after very low-density lipoproteins (VLDL) and LDL were precipitated with a heparin-MnCl<sub>2</sub> solution [27].

### **Liver and Kidney lipid profiles**

Lipids were extracted from the liver and kidney as described by Folch et al. [28]. After washing with 0.05 M KCl solution, aliquots of the lipid extracts were then used for the determination of lipid profiles. Details of these are given as reported earlier [29].

### **Determination of hepatic and renal SOD activities and MDA levels**

Hepatic and renal superoxide dismutase (SOD) activities were assayed in the tissue homogenates by the method of Kakkar, *et al.* [30] at 560 nm. One unit of enzyme activity was defined as that amount of enzyme which caused 50% inhibition of nitrobluetetrazolium reduction/mg protein. The SOD activity was expressed as per mg of protein and the tissue protein was estimated according to the method of Lowry *et al.*, [31], using bovine serum albumin (BSA) as a standard. The extent of lipid peroxidation was estimated as the concentration of thiobarbituric acid-reactive product malondialdehyde (MDA), using the method of Draper and Hadley, [32].

### **Statistical Analysis**

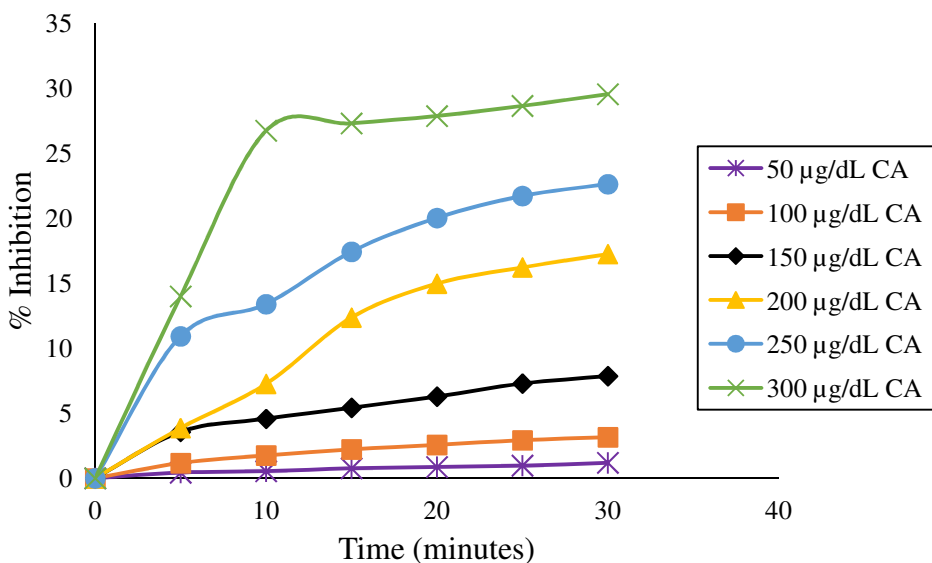
Results are expressed as mean  $\pm$  S.E.M. The levels of homogeneity among the groups were assessed using One-way Analysis of Variance (ANOVA) followed by Tukey's test. All analyses

were done using Graph Pad Prism software Version 5.00 and p values < 0.05 were considered statistically significant

## RESULTS

### **The total phenolic compounds and in-vitro antioxidant potential**

The *C. argentea* demonstrated a concentration and time-dependent scavenging activity by quenching DPPH radicals (Figure 1) and was compared with gallic acid, as a positive control. The IC<sub>50</sub> values (defined as the concentration of test compound required to produce 50% inhibition) for DPPH scavenging by *C. argentea* and gallic acid were  $582.75 \pm 8.58$   $\mu\text{g/dL}$  and  $16.33 \pm 1.50$   $\mu\text{g/dL}$  respectively (Table 1). In the TEAC assay, the TEAC value of Trolox is 1.00. Gallic acid responded as the strongest with TEAC value of  $4.25 \pm 0.12$  while *C. argentea* responded lowest with TEAC value of  $0.45 \pm 0.09$  (Table 1 & Figure 2). The phenolic content of *C. argentea* was determined using Folin-Ciocalteu assay and was found to be  $29.57 \pm 1.23$  mg/g in Gallic acid equivalent (Table 1)



**Figure 1.** The effects of time on different concentration of aqueous extract of *C. argentea* on inhibition of DPPH radical

**Table 1.** Total phenolic content, DPPH radical scavenging value and Trolox equivalent antioxidant capacity (TEAC) of *Celosia argentea*

Sample	Total phenol <sup>a</sup>	DPPH scavenging activity (IC 50) <sup>b</sup>	Trolox antioxidant (TEAC) <sup>c</sup>	equivalent capacities
Trolox	ND	ND	1	
Gallic	ND	16.32 ± 1.50	4.25 ± 0.12	
<i>C. argentea</i>	29.57 ± 1.23	582.75 ± 8.58	0.45 ± 0.09	

Each value represents the mean ± SEM (n=3).

a Total phenolic content was expressed as mg gallic acid equivalents/g dried extract.

b Expressed as µg/mL

c Expressed as mmol/L

### Effects of the extract on blood and tissue lipids of rats



Results of plasma and tissue lipids analyses are presented in Table 2. Administration of 400 mg/kg body weight of *C. argentea* alone did not produce any significant changes in lipid parameters in all the compartment studied when compared with control animals. However, administration of rifampicin alone significantly increased plasma, hepatic and renal cholesterol concentration by 70.27 %, 100.52 % and 67.28% respectively while it reduced HDL cholesterol by 64.41 % when compared with the control animals. Administration of rifampicin also resulted in non-significant changes in plasma, HDL, hepatic and renal triglycerides and phospholipids concentrations when compared with the control animals. However, co-administration of 200 mg/kg and 400 mg/kg body weight of *C. argentea* extract to rifampicin treated rats resulted in reduction of plasma cholesterol concentration by 27.15 % and 31.64 % respectively, reduction in hepatic cholesterol concentration by 33.25 % and 36.36 % respectively and reduction in renal cholesterol concentration by 33.06 % and 37.74 % respectively while HDL cholesterol concentration were increased by 88.49 % and 116.10 % respectively when compared with the rats treated with rifampicin only.

**Table 2:** Effects of aqueous leaf extract of *C. argentea* on blood, hepatic and renal lipids in rats.

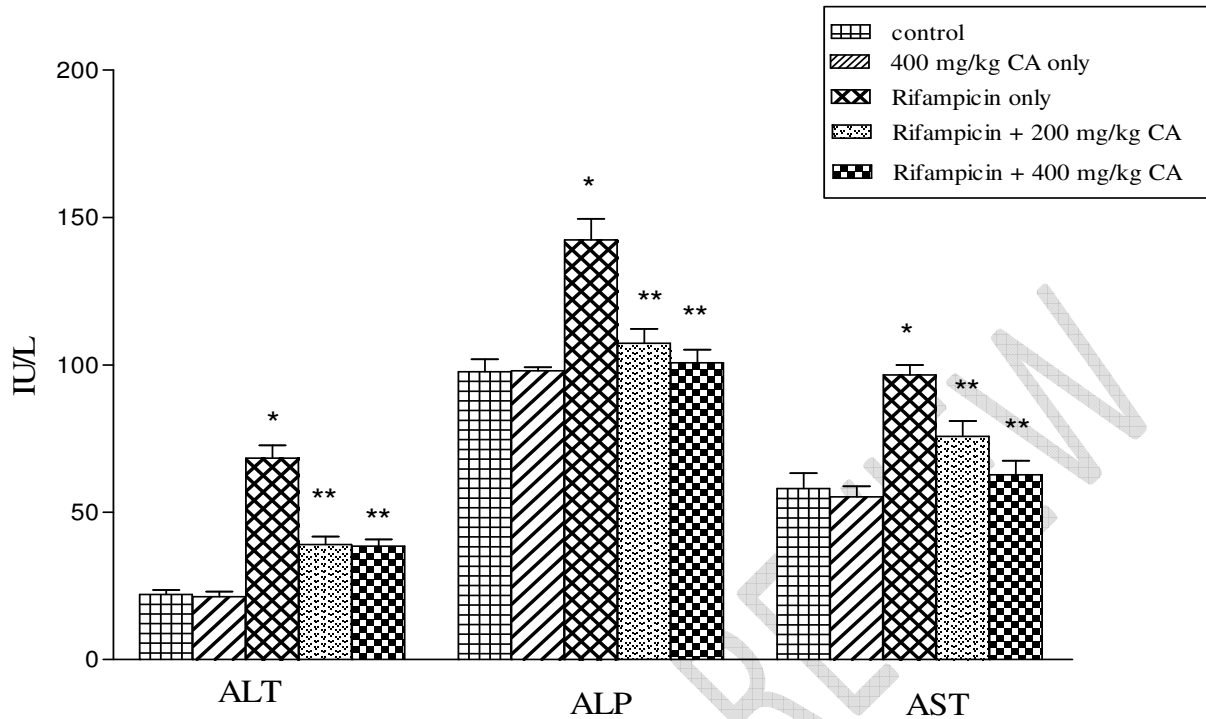
Parameters (mg/dL)	Control	400 mg/kg CA	Rifampicin	Rifampicin + 200 mg/kg CA	Rifampicin + 400 mg/kg CA
Plasma cholesterol	54.39 ± 2.75	57.92 ± 1.78	92.61 ± 3.63*	67.47 ± 2.10**	63.31 ± 2.52**
Plasma triglyceride	99.47 ± 3.29	104.62 ± 3.95	123.83 ± 4.53	96.21 ± 3.01	108.94 ± 3.72
HDL cholesterol	37.35 ± 1.93	36.15 ± 2.1	13.29 ± 0.75*	25.05 ± 2.11**	28.72 ± 1.73**
HDL triglyceride	57.66 ± 2.82	55.38 ± 3.51	58.95 ± 3.71	52.42 ± 2.23	74.48 ± 4.32
Hepatic cholesterol	1.92 ± 0.25	2.02 ± 0.31	3.85 ± 0.42*	2.57 ± 0.21**	2.45 ± 0.17**
Hepatic triglyceride	2.75 ± 0.31	2.91 ± 0.27	3.34 ± 0.28	3.12 ± 0.44	2.83 ± 0.22
Hepatic phospholipid	18.38 ± 1.54	20.47 ± 1.27	23.78 ± 0.97	19.33 ± 1.01	17.06 ± 0.82
Renal cholesterol	2.17 ± 0.28	2.14 ± 0.12	3.63 ± 0.33*	2.43 ± 0.14**	2.26 ± 0.25**
Renal triglyceride	2.15 ± 0.24	2.32 ± 0.18	2.54 ± 0.22	1.88 ± 0.17	2.52 ± 0.27

Renal phospholipid	47.45 ± 3.63	45.24 ± 2.12	35.96 ± 1.75	40.25 ± 2.15	41.08 ± 2.48
--------------------	--------------	--------------	--------------	--------------	--------------

Each value represents the Mean of 5 rats. \*Groups 2 and 3 (*C. argentea* and rifampicin treated rat respectively) compared with group 1 (control rats). \*\* Groups 4 and 5 (*C. argentea* treated rats) compared with group 3 (rifampicin treated rats)

### **Effect of extract on activities of ALT, ALP and AST**

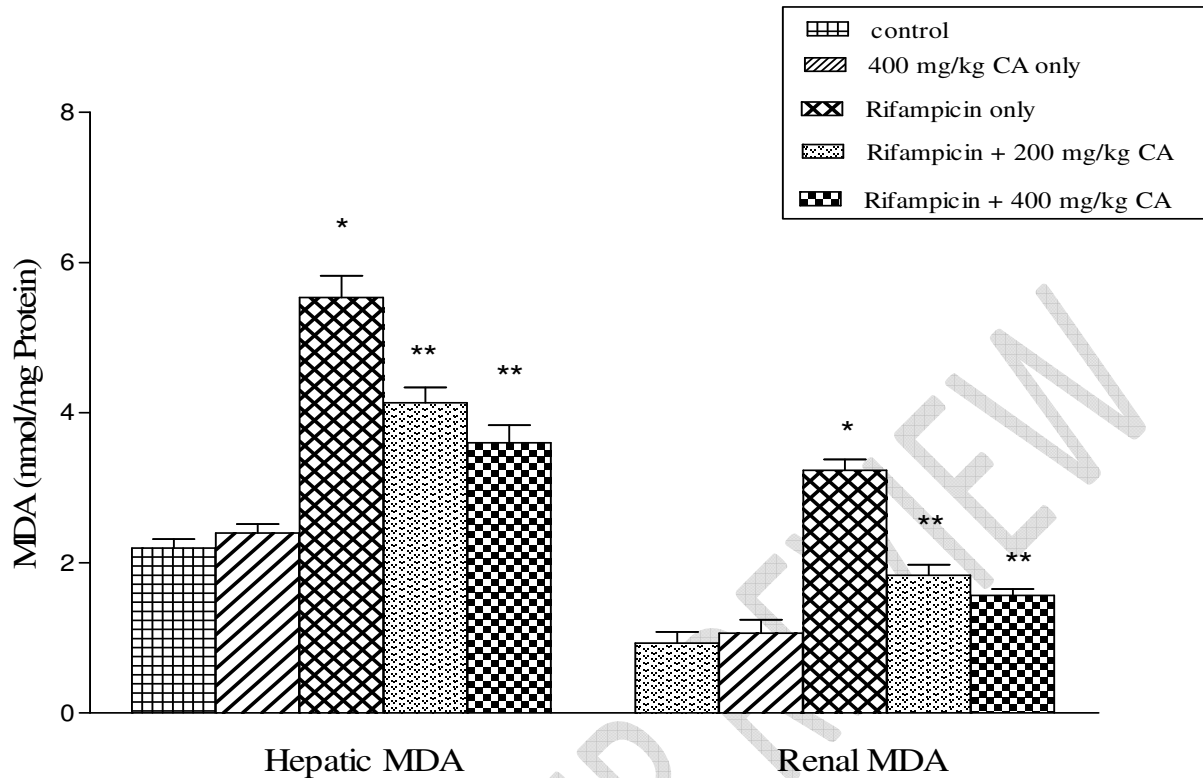
Administration of rifampicin only significantly increased enzymatic activity of ALT, ALP and AST by 209.03 %, 45.69 % and 66.34 % respectively when compared with the normal rats while administration of 400 mg/kg body weight of *C. argentea* alone did not produce any significant changes in the enzyme's activities. However, co-administration of 200 mg/kg and 400 mg/kg body weight of *C. argentea* extract to rifampicin treated rats caused reduction in plasma ALT activity by 42.88 % and 43.68 % respectively, reduction in plasma ALP activity by 24.60 % and 29.23 % respectively and reduction in plasma AST activity by 21.50 % and 34.98 % respectively, when compared with the rats treated with Rifampicin only.



**Figure 2.** Effect of aqueous extract of *Celosia argentea* on activities of ALT, ALP and AST in rifampicin-treated rats. Values are mean  $\pm$  SEM (n=5). \*Groups 2 and 3 (*C. argentea* and rifampicin treated rat respectively) compared with group 1 (control rats). \*\* Groups 4 and 5 (*C. argentea* treated rats) compared with group 3 (rifampicin treated rats)

#### **Effect of *Celosia argentea* extract on hepatic and renal malonaldehyde levels**

Hepatic and renal MDA levels of rats treated with rifampicin only were significantly increased by 151.36 % and 246.41 % respectively when compared with the normal rats while administration of 400 mg/kg body weight of *C. argentea* alone did not produce any significant change in MDA levels. However, co-administration of 200 mg/kg and 400 mg/kg body weight of *C. argentea* extract to rifampicin treated rats caused reduction in hepatic MDA level by 25.30 % and 34.94 % respectively, and reduction in renal MDA level by 43.30 % and 51.53 % respectively when compared with the rats treated with rifampicin only.

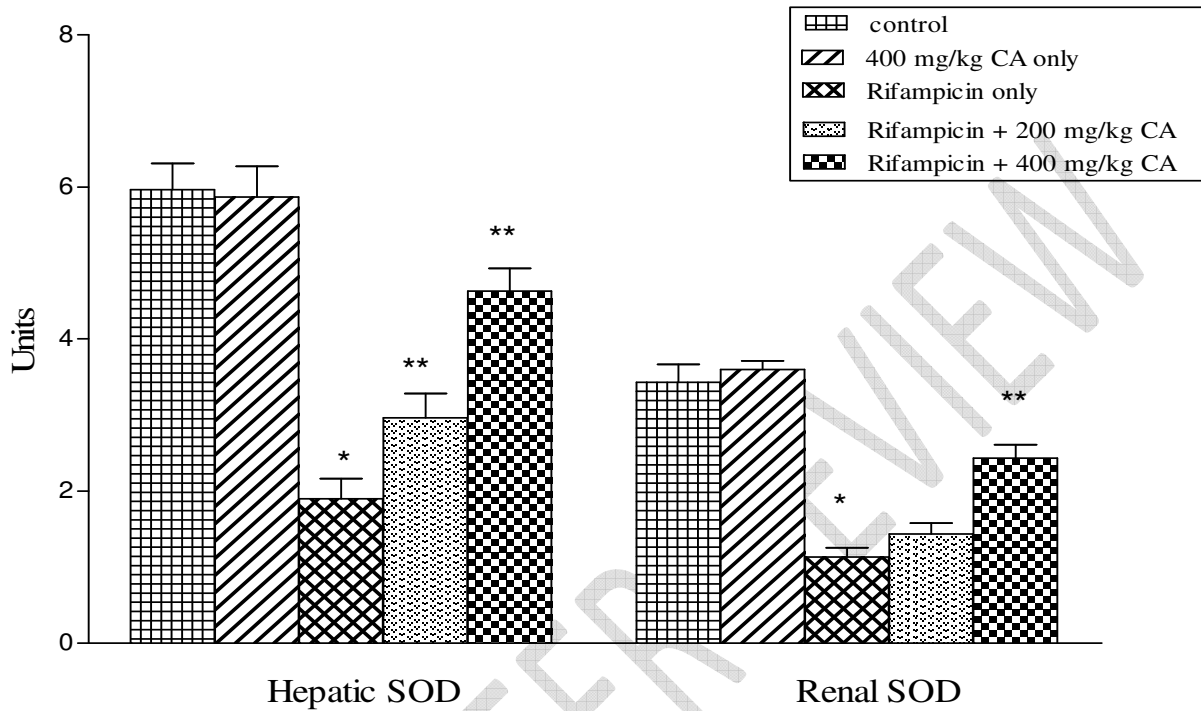


**Figure 3.** Effect of aqueous extract of *Celosia argentea* on MDA level of rifampicin treated rats. Values are mean  $\pm$  SEM (n=5). \*Groups 2 and 3 (*C. argentea* and rifampicin treated rat respectively) compared with group 1 (control rats). \*\* Groups 4 and 5 (*C. argentea* treated rats) compared with group 3 (rifampicin treated rats)

#### **Effect of *Celosia argentea* Extract on hepatic and renal SOD activity**

Hepatic and renal SOD levels of rats treated with rifampicin only were significantly reduced by 68.15 % and 67.00 % respectively when compared with the normal rats while administration of 400 mg/kg of *C. argentea* alone did not produce any significant change in SOD levels. However, co-administration of 200 mg/kg and 400 mg/kg body weight of *C. argentea* extract to rifampicin treated rats caused increased in hepatic SOD level was by 56.16 % and 143.84 % respectively,

and increased in renal SOD level 26.48 % and 114.74 % respectively when compared with the rats treated with rifampicin only.



**Figure 4.** Effect of aqueous extract of *C. argentea* on SOD activity of rifampicin treated rats. Values are mean  $\pm$  SEM (n=5). \*Groups 2 and 3 (*C. argentea* and rifampicin treated rat respectively) compared with group 1 (control rats). \*\* Groups 4 and 5 (*C. argentea* treated rats) compared with group 3 (rifampicin treated rats)

## DISCUSSION

Rifampicin a synthetic drug used for TB treatment is known for causing hepatic injury [7]. Rifampicin is a known inducer of many metabolizing enzymes; some metabolites produce through these reactions are toxic and their accumulation would result in induction of liver injury or immune responses [33]. Rifampicin could also cause accumulation of ROS as a result of

mitochondrial toxicity [34]. The liver injury caused by chemicals or infectious agents if not treated may progress to liver fibrosis, cirrhosis and liver failure [7]. It has been suggested in previous studies that traditional herbs and micronutrients may help in the prevention of liver injury [25, 26]. In recent time, one plant that has been subjected to several studies for its medicinal values is *C. argentea*. The current investigation was undertaken to evaluate the possible protective effect of *C. argentea* against rifampicin-induced hepatotoxicity and oxidative stress in rats.

The ABTS•+ and DPPH radical scavenging assay are among the common methods used to evaluate the total antioxidant activity of vegetables or other plants [25, 26]. In the present study, *C. argentea* showed DPPH radical scavenging activity which is attributed to its hydrogen donating ability. The extract also showed a strong ABTS radical scavenging ability in a concentration-dependent manner suggesting that *C. argentea* extract has strong antioxidant potential.

Rats treated with rifampicin in this study developed hepatic damage as revealed by an increase in the activities of ALT, ALP and AST which is in agreement with a previous study [1]. The increased activities of these liver enzymes in the blood is evidence of liver cell damage and loss of functional integrity [35]. There was a reduction in the elevated levels of these enzymes in rats co-administered with *C. argentea* extract and rifampicin when compared to the rifampicin group only which is an indication of the stabilization of plasma membrane as well as repair of liver damage caused by rifampicin. This observation is in agreement with the commonly accepted

view that serum levels of transaminases return to normal with the healing of hepatic parenchyma and the regeneration of hepatocytes [36].

Rifampicin administration significantly increases plasma cholesterol level and decrease HDL cholesterol level when compared with the control group a strong indication of disturbances in cholesterol metabolism, a result that is in agreement with similar studies of [8,37]. Administration of rifampicin also leads to the significant accumulation of cholesterol in the hepatic and renal tissues which is in support of a previous study [38]. In all the compartment, there was a reduction in cholesterol levels of rats co-administered with rifampicin and *C. argentea* extract when compared with rifampicin group only. Although it is not clear how *C. argentea* leaf extract reduced the levels of cholesterol, it may be due to its ability to modulate cholesterol metabolism by the liver or lipoprotein lipase activity [39]. The chemical constituents in *C. argentea* leaf extracts probably downregulate cholesterol biosynthesis or inactivate the enzymatic pathways or both.

Enhanced lipid peroxidation expressed in terms of MDA contents was observed in rifampicin-treated rats in our study which indicates the damage to the hepatic and renal cells this is in agreement with a previous study [3]. Rifampicin is a strong inducer of several metabolizing enzymes thereby resulting in increased accumulation of metabolites, the metabolites can initiate peroxidative damage to lipid membranes and other poly-unsaturated fatty acid-rich structures like endoplasmic reticulum through free radical-mediated reactions [8]. The induced lipid peroxides activated significant upsurge in MDA-like products with a resulting loss in cellular integrity and destruction of liver and kidney tissues. There was a significant reduction in MDA

levels of rats simultaneously treated with *C. argentea* extract and rifampicin when compared to the rifampicin group only, suggesting that the extract inhibit lipid peroxidation and its propagation in the liver and kidney.

The activity of antioxidant enzyme SOD was significantly decreased in hepatic and renal tissues of rifampicin treated rats in this study. The decreased activity of SOD in the liver and kidney tissues of rifampicin treated rats may be due to increased utilisation of the enzyme against reactive oxygen species [40]. However, co-administration of rats with *C. argentea* extract and rifampicin reversed the reduction in SOD levels when compared to the rifampicin group only, which demonstrates that *C. argentea* leaf extract protects the liver and kidney from oxidative damage.

Our present study revealed that *C. argentea* contains a considerable amount of phenolic compounds and exhibited strong free radical scavenging property. A number of researchers have reported that phenolic compounds in plants extract have antioxidant properties in various experimental models [41, 42]. Therefore, the ability of *C. argentea* to protect the rats against rifampicin induced liver and kidney damaged may be attributed to the presence of phenolic compounds in the extract. The phenolic substances are known to possess the ability to reduce oxidative damage and acts as an antioxidant. They can trap the free radicals directly or scavenge them through a series of coupled reactions with antioxidant enzymes [43]. The hepatoprotective effects of *C. argentea* demonstrated in this study could be exploited in alleviating xenobiotic-induced hepatotoxicity and nephrotoxicity. This finding justifies the use of *C. argentea* in traditional medicine, in the prevention of free radical-mediated diseases.



## Conclusion

The results obtained in this study gave credence to hepatoprotective effects of *C. argentea* and its use in ethnomedicine. The regular consumption of *C. argentea* by patients undergoing TB treatment might ameliorate the hepatotoxic effect associated with rifampicin treatment. The hepatoprotective effect of *C. argentea* demonstrated in this work is due to its antioxidant effects.

## REFERENCES

1. Bais B, Saiju P. Ameliorative effect of *Leucas cephalotes* extract on isoniazid and rifampicin induced hepatotoxicity. *Asian Pacific Journal of Tropical Biomedicine*. 2014;4(2):S633-S638
2. World Health Organization. Global tuberculosis report 2015. (2015) [2017-0802]. [http://apps.who.int/iris/bitstream/10665/191102/1/9789241565059\\_eng.pdf](http://apps.who.int/iris/bitstream/10665/191102/1/9789241565059_eng.pdf).
3. Nwidu LL, Teme RE. Hot aqueous leaf extract of *Lasianthera africana* (Icacinaceae) attenuates rifampicin-isoniazid-induced hepatotoxicity. *Journal of Integrative Medicine*. 2018;16:263–272.
4. Mahashur AA, Prabhudesai PP. Hepatitis and antitubercular therapy. *Journal of the Association of Physicians of India*. 1991; 39: 595-596.
5. Tostmann A, Boeree MJ, Aarnoutse RE, de Lange WC, van der Ven AJ, Dekhuijzen R. Antituberculosis drug-induced hepatotoxicity: concise up-to-date review. *Journal of Gastroenterology and Hepatology*. 2008;23(2):192–202
6. Aruoma OI. Methodological considerations for characterizing potential antioxidant actions of bioactive components in food plants. *Mutation Research*. 2003;523–524:9–20.
7. Zhang B, Sun S, Shen L, Zu X, Chen Y, Hao J, et al. DNA methylation in the rat livers induced by low dosage isoniazid treatment. *Environmental Toxicology and Pharmacology* 2011; 32: 486-490.

8. Abd El-Raheem AMA, Abdel-Wahhab KG, AbdelWahhab MM, Morsy FA, Soliman SME, Abdel-Tawab MA. Protective effect of some natural extracts against isoniazid induced hepatotoxicity in adult male rats. *Current Science International*. 2015;4 (3):409–22.
9. Shehab NG, Abu-Gharbieh E, Bayoumi FA. Impact of phenolic composition on hepatoprotective and antioxidant effects of four desert medicinal plants. *BMC Complementary and Alternative Medicine*. 2015;15:401.
10. Martin SJ, Baskaran UL, Vedi M, Sabina EP. Attenuation of anti-tuberculosis therapy induced hepatotoxicity by *Spirulina fusiformis*, a candidate food supplement. *Toxicology Mechanisms and Methods* 2014;24(8):584–92.
11. Rana SV, Pal R, Vaiphei K, Ola RP, Singh K. Hepatoprotection by carotenoids in isoniazid-rifampicin induced hepatic injury in rats. *Biochemistry and Cell Biology*. 2010;88 (5):819–34.
12. Radulovic´ N, Stankov-Jovanovic´ V, Stojanovic´ G, Šmelcerovic´ A, Spiteller M, Asakawa Y. Screening of in vitro antimicrobial and antioxidant activity of nine *Hypericum* species from the Balkans. *Food Chemistry*. 2007;103(1):15–21.
13. Baskaran UL, Sabina EP. The food supplement coenzyme Q10 and suppression of antitubercular drug-induced hepatic injury in rats: the role of antioxidant defense system, anti-inflammatory cytokine IL-10. *Cell Biology and Toxicology*. 2015;31 (4–5):211–219.
14. Ghule S, Prakash T, Kotresha D, Roopa K, Surendra V, Divakar G. Antidiabetic activity of *Celosia argentea* root in streptozotocin-induced diabetic rats. *International Journal of Green Pharmacy*. 2010;4:206–211.
15. Wu, Q., Wang, Y., Guo, M., 2011. Triterpenoid saponins from the seeds of *Celosia argentea* and their anti-inflammatory and antitumor activities. *Chemical and Pharmaceutical Bulletin*. 2011;59:666–671.
16. Ghorpade P, Siddiqui A, Patil MJ, Rub RA. Pharmacognostic and phytochemical evaluation of *Celosia argentea*. *Pharmacognosy Journal*. 2012;4:7–15.

17. Okpako E, Ajibesin KK. Antimicrobial activity of *Celosia argentea* L. amaranthaceae. American Journal of Research Communication. 2015;3:123–133.
18. Tang Y, Xin H-I, Guo M.-L. Review on the research of the phytochemistry and pharmacological activities of *Celosia argentea*. Brazilian Journal of Pharmacognosy. 2016;26:787–796.
19. Xue Q, Sun ZL, Guo ML, Wang Y, Zhang G. 2011. Two new compounds from Semen Celosiae and their protective effects against CCl<sub>4</sub>-induced hepatotoxicity. Natural Product Research. 2011;25:772–780.
20. Wu QB, Wang Y, Liang L, Jiang Q, Guo ML, Zhang JJ. Novel triterpenoidsaponins from the seeds of *Celosia argentea* L. Natural Product Research. 2013;27:1353–1360.
21. Molehin OR, Adefegha SA, Oboh G, Saliu JA, Athayde ML, Boligon AA. 2014. Comparative study on the phenolic content, antioxidant properties and HPLC fingerprinting of three varieties of *Celosia* species. Journal of Food Biochemistry. 2014;38:575–583.
22. Re R, Pellegrini N, Proteggente A, Pannala A, Yang M, Rice- Evans C. Antioxidant activity applying an improved ABTS radical cation decolorization assay. Free Radical Biology and Medicine. 1999;26(9–10):1231–1237.
23. Schlesier K, Harwat M, Böhm V, Bitsch R. Assessment of antioxidant activity by using different *in vitro* methods. Free Radical Research. 2002;36(2):177-187.
24. Miliauskas G, Venskutonis P, van Beek T. Screening of radical scavenging activity of some medicinal and aromatic plant extracts. Food Chemistry. 2004;85:231-237.
25. Owoade AO, Aborisade AB, Adetutu A, Olorunnisola OS. Evaluation of the Effectiveness of *Telfairia occidentalis* Leave Extracts in the Amelioration of Carbon Tetrachloride Induced Liver Injuries and Oxidative Damage in Rats. Journal of Advances in Medical and Pharmaceutical Sciences. 2016;10(2):1-11.

26. Owoade AO, Adetutu A, Aborisade AB. Protective effects of Moringa Oleifera leaves against oxidative stress in diabetic rats. *World Journal of Pharmaceutical Sciences*. 2017;5(11):64-71.
27. Gidez LI, Miller GJ, Burstein M, Slagle S, Eder HA. Separation and quantitation of subclasses of human plasma high density lipoproteins by a simple precipitation procedure. *Journal of Lipid Research*. 1982;23:1206–1223.
28. Folch J, Lees M, Sloane Stanley GH. A simple method for the isolation and purification of total lipides from animal tissues. *Journal of Biology Chemistry*. 1957;226:497–509.
29. Owoade AO, Airaodion AI, Adetutu A, Akinyomi, OD. Levofloxacin-induced dyslipidemia in male albino rats *Asian Journal of Pharmacy and Pharmacology*. 2018;4(5): 620-629.
30. Kakkar P, Dos B, Viswnathan PN. A modified spectrophotometric assay of superoxide dismutase. *Indian Journal of Biochemistry*. 1984;21:130-132.
31. Lowry OH et al. Protein measurement with the Folin phenol reagent. *Journal of Biological Chemistry*. 1951;193:265– 275.
32. Draper HH, Hadley M. Malondialdehyde determination as index of lipid peroxidation, *Methods Enzymology*. 1990;186:421–431.
33. Anderson MS, Cote J, Liu Y, Stypinski D, Auger P, Hohnstein A, et al. Effects of rifampicin, a potent inducer of drug metabolizing enzymes and an inhibitor of OATP1B1/3 transport, on the single dose pharmacokinetics of anacetrapib. *Journal of Clinical Pharmacology*. 2013;53(7):746–52.
34. Elmorsy E, Attalla SM, Fikry E, Kocon A, Turner R, Christie D, et al. Adverse effects of antituberculosis drugs on HepG2 cell bioenergetics. *Human and Experimental Toxicology*. 2016;36(6):616–25.
35. Rajesh MG, Latha MS. Preliminary evaluation of the antihepatotoxic effect of Kamilari, a polyherbal formulation. *Journal of Ethnopharmacology*. 2004;91:99-104.

36. Jaishree V, Badami S. Antioxidant and hepatoprotective effect of swertiamarin from *Enicostemma axillare* against D-galactosamine induced acute liver damage in rats. *Journal of Ethnopharmacology*. 2010;130:103–106.
37. Jyothi B, Mohanalakshmi S, Anitha K. Protective effect of *Mirabilis jalapa* leaves on anti-tubercular drugs induced hepatotoxicity. *Asian Journal of Pharmaceutical and Clinical Research*. 2013;6(3):221–214.
38. Pal R, Rana SV, Vaiphei K, Singh K. Isoniazid-rifampicin induced lipid changes in rats. *Clinica Chimica Acta*. 2008;389(1–2):55–60.
39. Ichikawa T, Liang J, Kitajima S, Koike T, Wang X, Sun H, et al. Macrophage derived lipoprotein lipase increases aortic atherosclerosis in cholesterol-fed Tg rabbits. *Atherosclerosis*. 2005;179(1):87–95.
40. Singh RP, Khanna R, Kaw JL, Khanna SK, Das M. Comparative effect of benzanthrone and 3-bromobenzanthrone on hepatic xenobiotics metabolism and antioxidative defense system in guinea pigs. *Molecular Toxicology*. 2003;77:94-99.
41. Guo H, Sun J, He H, Yu GC, Du J. Antihepatotoxic effect of corn peptides against bacillus calmette-guerin/lipopolysaccharide-induced liver injury in mice. *Food and Chemical Toxicology*. 2009;47:2431–2435.
42. Harish R, Shivanandappa T. Antioxidant activity and hepatoprotective potential of *Phyllanthus niruri*. *Food Chem*. 2008;95:180–185.
43. Halliwell B, Gutteridge JMC. Oxidative stress: Adaptation, damage, repair and death. In: Halliwell B, Gutteridge JMC, Eds. *Free Radicals in Biology and Medicine*, 3rd Edition, Oxford University Press, Oxford. 1999;246-350.