

Sonographic features predictive of thyroid nodule malignancy in a Nigerian Population

ABSTRACT (ARIAL, BOLD, 11 FONT, LEFT ALIGNED, CAPS)

Aims: To determine the ultrasound malignancy score (UMS) and identify the ultrasound (US) features of thyroid nodule (TN) associated with malignancy, in our study population, using fine-needle aspiration cytology (FNAC) as the gold standard.

Study design: A prospective cross-sectional observational study.

Place and Duration of Study: Departments of Radiology and Morbid Anatomy and Forensic Medicine, Obafemi Awolowo University Teaching Hospital Complex, Ile Ife, Nigeria, between June 2016 and May 2017.

Methodology: We studied 110 thyroid nodules in 110 adult subjects (97males and 13males). Neck USS to evaluate and score 7 sonographic features of the nodules for their malignant potential as well as simultaneous USG-FNAC was done. The findings were compared and data was analyzed using Statistical Package for Social Science (SPSS) version 20.

Results: Findings of ultrasound guided – fine needle aspiration cytology (USG-FNAC) showed that of the 110 thyroid nodules studied, 107(97.3%) were benign while 3(2.7%) were malignant. Receiver operating characteristic curve showed that at sensitivity and specificity of 66.7% and 88.8% respectively giving UMS of 4.5. All the 3 nodules that were malignant on USG-FNAC had micro calcification and irregular margins on ultrasound ($p=0.05$).

Conclusion: Using USG-FNAC as the gold standard, thyroid nodules with UMS of 4.5 are likely to be malignant. Ill-defined margins and micro calcifications on ultrasound are suggestive of malignancy in thyroid nodules.

Keywords: [Thyroid Nodules, Malignancy, Ultrasound, USG - FNAC.]

1. INTRODUCTION (ARIAL, BOLD, 11 FONT, LEFT ALIGNED, CAPS)

Nodules within the thyroid gland are common and they are mostly benign^{1, 2}. Nevertheless each nodule has to be accurately identified as benign or malignant^{3, 4}. High resolution Ultrasound (USS) is the most sensitive and globally accepted imaging modality for the initial evaluation of thyroid nodules (TN). USS is non-invasive, widely available, less expensive and it does not use ionizing radiation⁴. However the usefulness of USS in the evaluation of TN is often limited due to the considerable overlap between the sonographic features of benign and malignant TN⁵. For this reason fine needle aspiration for cytology (FNAC) has become a popular procedure in differentiating between benign and malignant TN.

FNAC is considered the method of choice to diagnose thyroid cancer though it is invasive and more expensive³. Given the high prevalence of TN, and the resources required, performing FNAC for every TN discovered will be prohibitive⁶. FNAC is further limited by the possibility of inadequate sampling. The development of accurate and reliable USS based criteria to predict malignancy will reduce the need for FNAC⁷. For this reason some studies have proposed ultrasound based TN malignancy score as a tool for risk classification such that only the TN that is suspicious for malignancy will be subjected to FNAC^{3, 7}.

An ultrasound based tool for risk classification is essential in resource poor environments, especially in places where most healthcare financing is out of the individual patient's pocket such as ours. To be effective this tool has to be simple reliable and easily reproducible³. To the best of our knowledge such a tool is yet to be developed among Nigerians with TN. Therefore the aim of this study is to determine the Ultrasound Malignancy Score (derived from seven sonographic features of TN) and identify the USS features of TN that are associated with malignancy in our study population using FNAC as the gold standard.

2. MATERIAL AND METHODS / EXPERIMENTAL DETAILS / METHODOLOGY (ARIAL, BOLD, 11 FONT, LEFT ALIGNED, CAPS)

This is a prospective, cross-sectional, observational study carried out at the Radiology and Morbid Anatomy departments of a tertiary hospital in South West Nigeria following approval by the institutional Ethical and Research committee.

We consecutively selected and studied 110 consenting adults aged 18 to 80 years referred for ultrasound evaluation of thyroid nodules. Subjects with non-nodular goitre, those on thyroid therapy and those who did not consent were excluded from the study.

The research project was explained to each patient and a written consent was obtained. Demographic data, family history of thyroid disease and history of head and neck irradiation in childhood were recorded.

Ultrasound examinations were performed with Mindray DC-7 (Shenzhen, China) using a linear transducer probe with frequency of 7-12 MHz. In patients with multiple nodules the nodule with sonographic features most suggestive of malignancy was chosen as the index nodule. B-mode and Doppler ultrasound was performed to evaluate the following features on the nodule: echogenicity, calcification, shape, size, internal content, margin and vascularity.

Table 1. A table showing various ultrasound findings of thyroid nodule and the scores.¹⁴

Ultrasound features	Ultrasound findings	Score
Echogenicity	Hypoechoic	1
	Hyperechoic/Isoechoic	0
Calcification	Micro calcification	1
	Macro calcification	0
Shape	Taller than wider	1
	Wider than taller	0
Size	≥10mm	1

	<10mm	0
Internal content	Solid	1
	Cystic/Spongiform	0
Margin	Ill-defined	1
	Smooth	0
Vascularity	Markedly Intra-nodular vascularity	1
	Markedly Peri-nodular vascularity	0

1: Features suggestive of malignancy 0: Features suggestive of benignity

The features were recorded and graded as shown in Table 1.

All ultrasound examinations were performed by a senior registrar in Radiology (ORO) and a consultant Radiologist (CMA). Immediately after USS evaluation of the thyroid, FNA was performed using the freehand biopsy technique. A 23-25 gauge needle attached to a 5ml syringe was introduced into the thyroid nodule with real time ultrasound monitoring of the needle tip. The aspirated sample was placed on a glass slide, smeared and fixed in 95% alcohol by the consultant Pathologist (AOK) who also read and interpreted the slides according to the Bethesda system for reporting thyroid cytopathology.

The sonographic features of the thyroid nodules and other characteristics of each subject were recorded in a proforma. These were entered into the Excel spread sheet and transferred to Statistical Package for Social Science (SPSS) version 20 for analysis. The USS findings for each patient were categorized and scored as done in previous study¹⁴ (Table 1)

Socio-demographic, clinical and sonographic findings of study subjects were presented as relative frequencies. Bivariate analysis was carried out to compare ultrasound findings and USG-FNAC in differentiating benign from malignant thyroid nodules. Chi-square and corresponding *p* values were used to compare categorical variables. Using USG-FNAC as the standard, Receiver operating characteristic curve (ROCC) was used to determine a cut-off point for making a diagnosis of benign or malignant nodule with the malignant nodule score. The sensitivity, specificity and predictive values of the diagnostic outcome of ultrasound in differentiating benign and malignant thyroid nodules were also calculated. *P* value of < .05 was regarded as statistically significant.

Description of Sonographic features

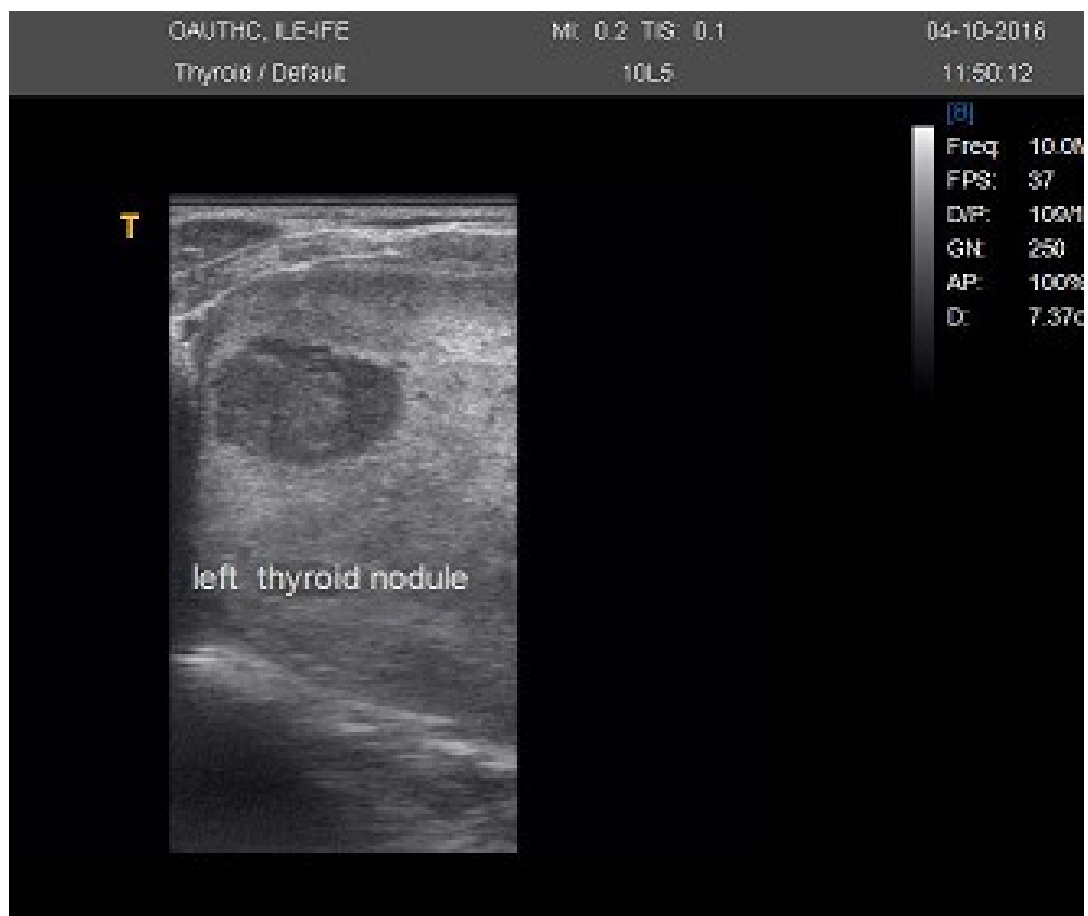


Figure 1: Longitudinal plane B mode ultrasound scan of the thyroid gland showing an oval shaped, smoothly marginated, wider than tall hypoechoic nodule.

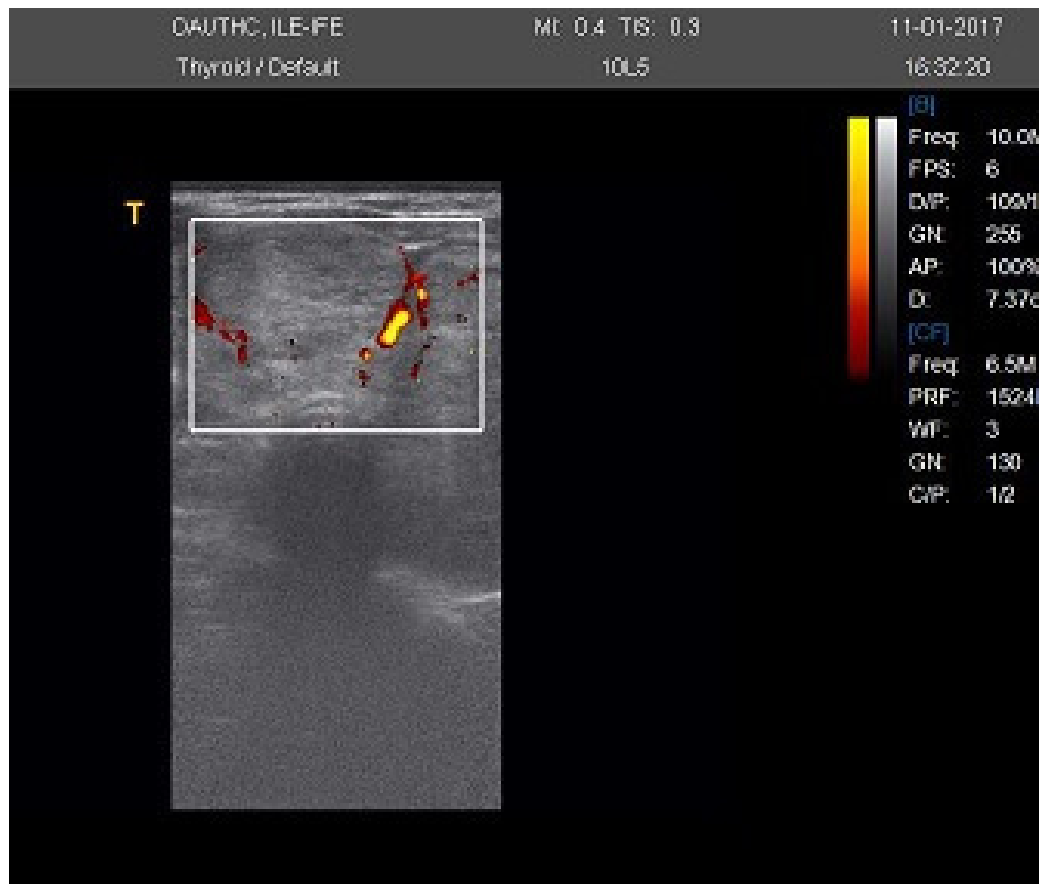


Figure 2: Transverse plane B mode and colour Doppler USS showing a smoothly marginated, wider than tall, isoechoic, predominantly solid nodule with perinodular vascularity.

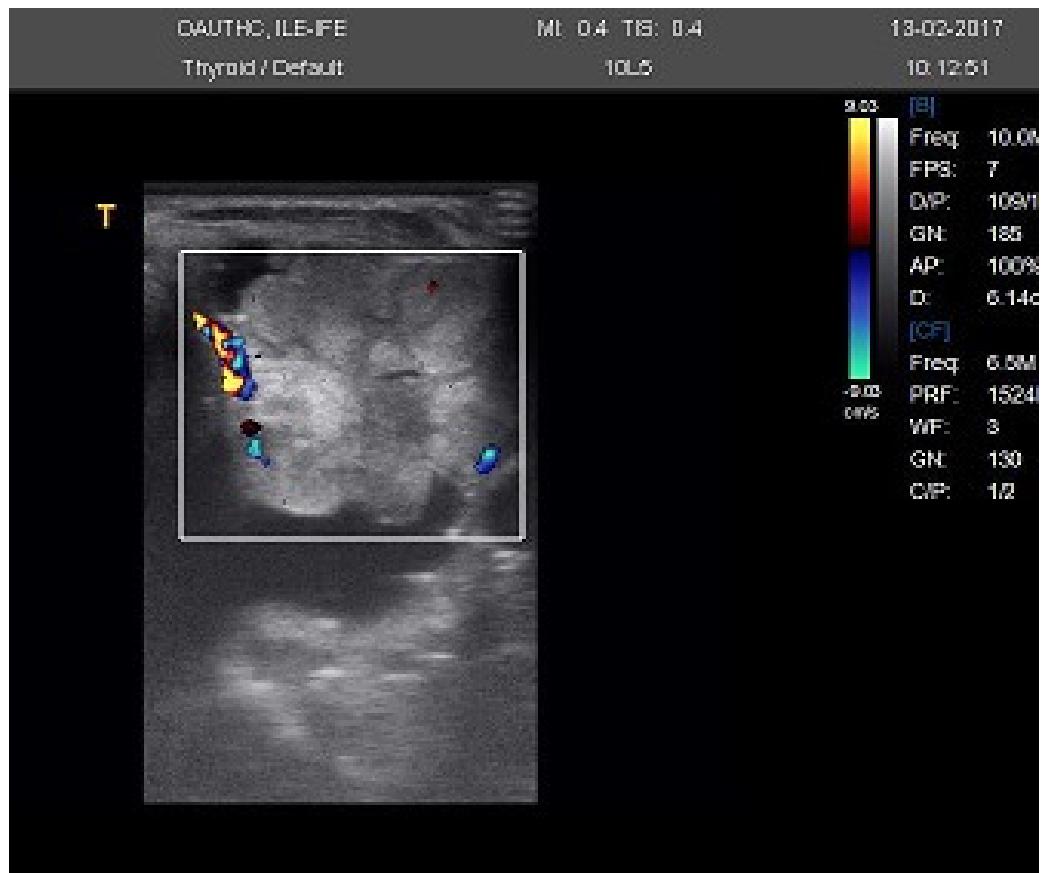


Figure 3: Transverse plane, B mode and colour Doppler USS showing an ill-defined, irregularly margined, taller than wide, predominantly solid hyperechoic nodule with perinodular vascularity.

Hypo-echoic: The same or reduced echogenicity compared with strap muscles (Figure1). **Hyper-echoic:** Nodule more echogenic than thyroid parenchyma OR same echogenicity as thyroid parenchyma (Figures 2 and 3). **Micro-calcification:** Small hyperechoic punctate foci (<1mm) without posterior acoustic shadows. **Macro-calcification:** Coarse and large foci >1mm with posterior acoustic shadows. **Taller than wide:** When the anteroposterior diameter of the nodule is longer than its transverse diameter on a transverse or longitudinal plane. **Wider than tall:** When the anteroposterior diameter of the nodule is shorter than its transverse diameter on both transverse and longitudinal planes (Figure 3). **Size:** Measures ≥ 10 mm on any plane or measures <10mm. **Solid:** Liquid portion less than 10% of nodule volume. (Figure1). **Cystic Spongiform:** Liquid portion $\geq 50\%$ but $\leq 90\%$ of the nodule containing clustered microcystic space separated by echogenic septa (Figure 4). **Ill-defined:** No clear demarcation of nodule from normal thyroid parenchyma. **Smooth:** There is a clear demarcation from normal thyroid parenchyma. (Figure1).

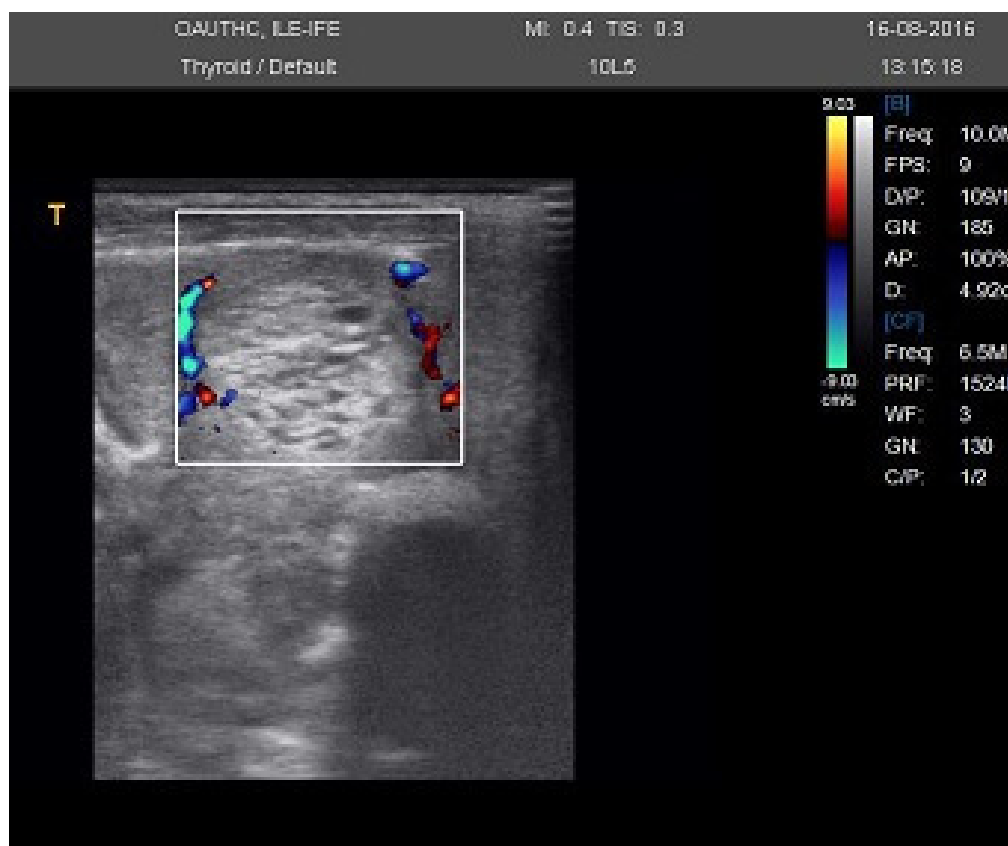


Figure 4: Transverse plane, B mode and colour Doppler USS showing a smoothly margined wider than tall hyperechoic, spongiform nodule with perinodular vascularity.

Intra-nodular vascularity: Flow predominantly within the nodule. **Peri-nodular vascularity:** Flow predominantly in the periphery of the nodule (Figure 4).

3. RESULTS AND DISCUSSION

3.1. RESULTS

3.1.1. Demographic characteristics of the study population

We performed USG-FNA of 110 thyroid nodules on 110 subjects comprising of 97(88.2%) females and 13(11.8%) males. Their age range is between 18 and 80 years with a mean of 48.3 ± 15 years. Most of the subjects with thyroid nodules in this study are between ages 51-60 years also most of them presented within 1-4 years of having the goitre.

Table II: Demographic characteristics of subjects with thyroid nodules.

Variables	Freq	%
Age group(years)		
<31	14	12.7
31-40	25	22.7

41-50	21	19.1
51-60	30	27.3
>60	20	18.2
Sex		
Female	97	88.2
Male	13	11.8
Family history of neck swelling		
No	92	83.6
Yes	18	16.4
Neck Irradiation		
NO	109	99.1
YES	1	0.9
Duration of neck swelling(Years)		
<1	11	10
1 -4	42	38.2
5-10	20	18.2
>11	12	10.9
Not known	25	22.7

The minimum duration of neck swelling was 1 week while the maximum was 30 years. Only 16.4% of them had family history of goitre. Most of the subjects 109(99.1%) never had neck x-ray prior to development of goitre. (Table II)

3.1.2 USG-FNAC findings in thyroid nodules

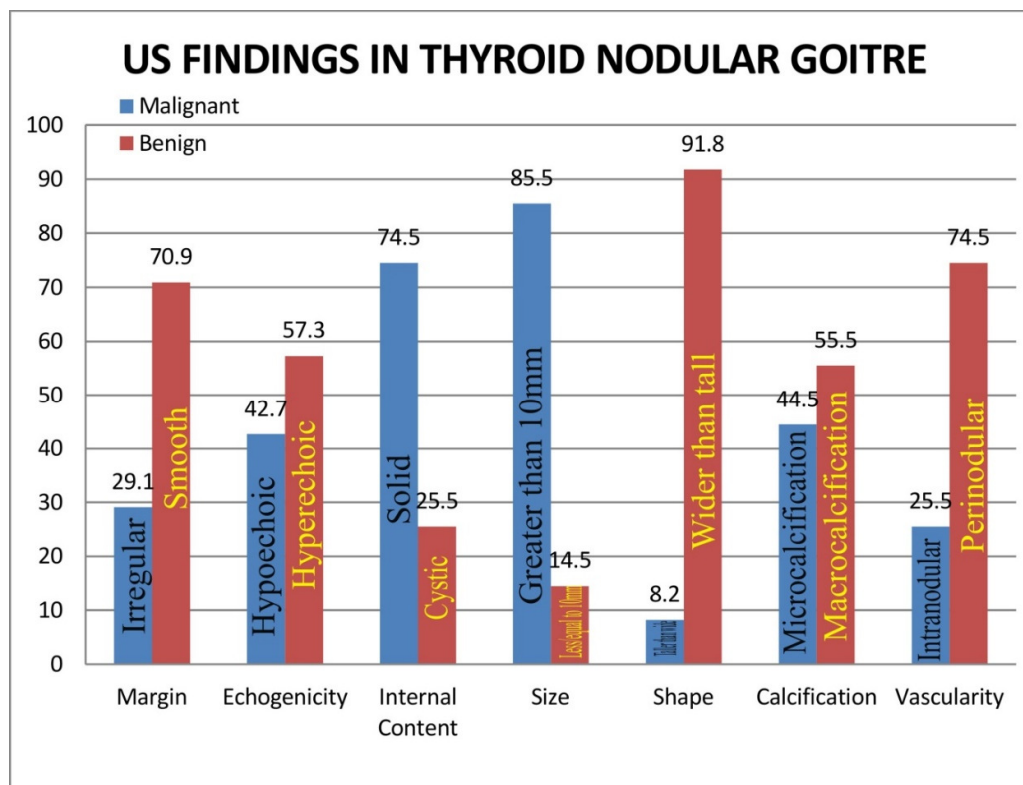


Figure 5: Bar chart showing frequency of specific B mode and colour Doppler ultrasonographic findings that suggest benignity and malignancy in subjects with thyroid nodules.

The findings are displayed in Figure 5. Of all studied subjects only 3 (2.7%) had malignant thyroid nodules.

3.1.3 Association between demographic characteristics and USG-FNAC findings in thyroid nodules.

Table III: Association between demographic characteristics and ultrasound guided fine-needle aspiration cytology findings in thyroid nodules.

Variables	USGFNAC				P value
	Benign		Malignant		
	Freq	%	Freq	%	
Age group					
<31 years	14	100.0	0	0.0	
31-40 years	25	100.0	0	0.0	.443
41-50 years	20	95.2	1	4.8	
51-60 years	28	93.3	2	6.7	

>60 years	20	100.0	0	0.0	
Family history of neck swelling					
NO	89	96.7	3	3.3	.437
YES	18	100.0	0	0.0	
Total	107	97.3	3	2.7	
Sex					
Female	96	99.0	1	1.0	.003
Male	11	84.6	2	15.4	
History of neck irradiation					
NO	106	97.2	3	2.8	.866
YES	1	100.0	0	0.0	
Duration of neck swelling					
<1 years	11	100.0	0	0.0	
1 -4 years	40	95.2	2	4.8	.733
5-10 years	20	100.0	0	0.0	
>11 years	12	100.0	0	0.0	
Don't know	24	96.0	1	4.0	

USG-FNAC findings revealed that of the 97 female subjects in this study 96(99%) and 1(1%) had benign and malignant thyroid nodules respectively. Of the 13 male subjects 11(84.6%) had benign and 2(15.4%) had malignant thyroid nodules. Gender is the only demographic feature having a statistically significant ($p = .003$) association with USG-FNAC findings. (Table III)

3.1.4 Comparison of B mode and Doppler sonographic findings with USG-FNAC findings

Table IV: Comparison of B mode and colour Doppler findings with ultrasound guided fine-needle aspiration cytology findings in thyroid nodules.

ULTRASOUND FEATURES	USGFNAC				
	Benign		Malignant		<i>p</i> value
	Freq	%	Freq	%	
Margin					
Smooth	78	72.9	0	0	
Ill- defined	29	27.1	3	100	.006
Echogenicity					
Hyperechoic	62	57.9	1	33.3	.40
Hypoechoic	45	42.1	2	66.7	
Internal Content					
Cystic	27	25.2	1	33.3	.75
Solid	80	74.8	2	66.7	
Size					
>10mm	16	15	3	0	.47
≤10mm	91	85	0	100	
Shape					
Wider than tall	98	91.6	3	100	.60
Taller than wide	9	8.4	0	0	
Calcification					
Macro-calcification	61	57	0	0	.05
Micro-calcification	46	43	3	100	
Vascularity					
Perinodular	81	75.7	1	33.3	.10
Intra-nodular	26	24.3	2	66.7	

Concordance was noted between the sonographic features and USG-FNAC findings in those thyroid nodules that had ill-defined margins ($p = .006$) and those that had micro-calcifications ($p = .05$). All other sonographic features were discordant with the USG-FNAC findings as shown on (Table IV).

3.1.5 Comparison of Ultrasound Malignancy Score (UMS) with USG- FNAC findings

Table V: Comparison of USG-FNAC and UMS

	USG-FNAC Findings		Total	
	Benign	Malignant		
US malignancy score	Benign	95(TN)	1(FN)	96
	(<4.5)	(88.8%)	(33.3%)	
	Malignant	12(FP)	2(TP)	14
	(≥4.5)	(11.2%)	(66.7%)	
		107	3	110
Total	(100%)	(100%)		

Results as presented in Table V showed that 11.2% of the nodules with malignant UMS had benign USG-FNAC findings while 33.3% of the nodules with benign UMS were malignant on USG-FNAC.

3.1.6 Comparing diagnostic accuracy assessment of UMS / other sonographic parameters with USG-FNAC (Gold standard)

For each sonographic features suggestive of malignancy, calculated diagnostic performance including sensitivity, specificity, positive predictive value (PPV), negative predictive value (NPV) and accuracy are listed in table vi. Margin and micro calcification had the highest PPV (9.4 and 6.1).

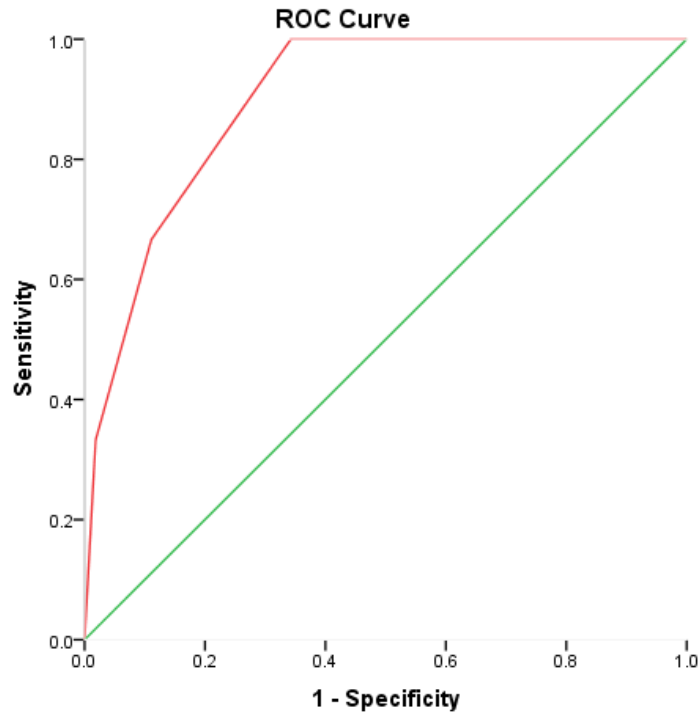
Table vi: Comparing diagnostic accuracy assessment of UMS / other sonographic parameters with USG-FNAC (Gold standard).

Variables	Sensitivity (%)	Specificity (%)	NPV (%)	PPV (%)	Accuracy (%)
USS malignancy score	88.8	66.7	98.9	14.3	88.2
Margin	100.0	72.9	100.0	9.4	73.6
Micro	100.0	57.0	100.0	6.1	58.1

calcification					
Hypoechoic	66.7	57.9	98.4	4.3	58.2
Solid internal content	66.7	25.2	96.4	2.4	26.4
Size >10mm	100.0	15.0	100.0	3.2	26.4
Shape (wider than tall)	0.0	90.7	97.0	0.0	89.1
Intranodular Vascularity	66.7	75.7	98.8	7.1	57.3

NPV- Negative predictive value; PPV- Positive predictive value

3.1.7 Receiver operating characteristic curve (ROCC) to assess the nature of thyroid nodules using ultrasonography



*Diagonal segments are produced by ties.

Figure 6: Receiver operating characteristic curve (ROCC) of malignancy score

A score of 1 was given to any of the 7 malignant USS features when present while 0 was given when absent. The sum of these scores indicates the ultrasound malignancy score (UMS) for each subject. The minimum possible score being 0 indicates no USS features suggestive of malignancy while the maximum possible score being 7 indicates that the 7 USS features were suggestive of malignancy. The best combination of sensitivity and specificity in this study is 66.7% and 88.8% from ROCC which is at a cut-off point of malignancy score of 4.5. (Figures 6)

3.2 Discussion

The prevalence of TN malignancy, in this study of 110 adults, is 2.7%. We found that thyroid nodules (TN) that exhibit ill defined margins or micro-calcifications are likely to be malignant. In addition a TN with 4 of the 7 sonographic features evaluated in this study or an ultrasound malignant score (UMS) of 4.5 derived using these 7 sonographic features is also likely to be malignant. Although TN is more prevalent among the females in this study, malignant thyroid nodules were more prevalent among male subjects.

Thyroid nodules are commoner in females than males and correspondingly thyroid cancer is more common among females⁸. Although TN is more prevalent among the females in this study, malignant thyroid nodules were more prevalent among male subjects. This may be related to relatively small sample size in this study although previous studies have also shown a higher prevalence of malignant TN among males⁹. Normally, prompt intervention is required in the male patient with a TN, because they have a worse survival and more aggressive disease at presentation, even though thyroid cancer is less common in men^{8, 10}.

All the 3 malignant TN in this study had micro-calcifications. Pathologically, micro-calcifications correspond to clusters of Psammoma bodies within the TN⁵. Our finding that micro-calcification is a strong indicator of malignancy is in agreement with previous

studies^{11, 12}. Similarly, an ill-defined margin, which suggests malignant infiltration of adjacent thyroid parenchyma, is strongly associated with thyroid nodule malignancy in this study. This is also consistent with the consensus in existing literature that an ill-defined margin is a useful marker of malignancy in TN^{5,13}.

A receiver operating characteristic curve (ROCC) was constructed with ultrasound malignancy score (UMS) using the findings from ultrasound guided fine needle aspiration cytology (USGFNAC) as the gold standard for diagnosing malignant thyroid nodules. The plot yielded a combination of specificities and sensitivities at different cut-off points of the UMS. The best combination of sensitivity and specificity in this study is 66.7% and 88.8% respectively which gives a cut-off of malignancy score 4.5. Therefore a TN with more than four sonographic features suggestive of malignancy by the UMS is likely to be malignant. (Sensitivity = 66.7%, Specificity = 88.8%). Unsal et al¹⁴ reported a malignancy score of 3 in their studied cohort with a sensitivity and specificity of 51.7% and 96.7% respectively. The lower UMS in their study is presumably due to the lower number of TN sonographic features they used to derive the score moreover, histology rather than cytology was the gold standard in their study. Another study³ that evaluated 8 sonographic features using cytology as the gold standard had a cut off malignancy of 3. Comparing these studies with ours suggest that histology is a better gold standard and when cytology used as the gold standard, more sonographic features may be required to derive the ultrasound based malignancy score.

A positive predictive value, negative predictive value and accuracy of 14.3%, 98.9% and 88.2% respectively for UMS was found in this study. In contrast, Unsal et al¹⁴ reported positive predictive value, negative predictive value and accuracy of 88.2%, 80.6% and 80.2% respectively for their UMS. The lower Positive predictive value in the index study is presumably due to high false positive values obtained. This further supports the need to compare USS features with histology (as seen in the Unsal et al¹⁴ study) rather than cytology.

Despite an UMS of 4.5 in this study, a sub-analysis of the 3 malignant nodules confirmed by cytology shows that one of the nodules had an UMS of 4 (false negative) which is less than the score required for classification as malignancy. However the 2 USS features which showed statistical significance, that is ill-defined margins and micro-calcification were present in this nodule. Furthermore, a subgroup analysis of the 12 nodules diagnosed as malignant on USS which turned out to be benign at cytology (False positives) showed that 11 (91.7%) of them had one or both of the 2 significant USS features (ill-defined margin or micro-calcification) and an UMS above 4.5. We postulate that if histology (which is superior in tissue diagnosis) rather than cytology had been our gold standard several of the nodules with UMS above 4.5 might have been confirmed to be malignant.

Three sonographic features traditionally associated with malignancy occurred in high frequencies among the malignant thyroid nodules identified in this study. The features are: size greater than 1cm (100%), hypo-echogenicity (66.7%) and solid internal content (66.7%). However there was no statistically significant association between any of these sonographic features and malignancy in the thyroid nodules we studied. This may be due to the small number of malignant TNs (3) in our study population. Although similar to our findings, Papini et al¹¹, showed that size greater than 1cm and hypo-echogenicity, despite showing high frequency, among the malignant thyroid nodules in their study, was not significantly associated with malignancy. Likewise Iannuccilli et al¹⁵ found that though most of the malignant thyroid nodules in their study were predominantly solid and this feature was not a statistically strong criterion to suggest malignancy.

Sonographic features such as echogenicity, internal contents, size, shape and vascular flow pattern of thyroid nodules had low positive predictive value for malignant thyroid nodules in our study population. Other authors have also categorized these features as

either non-specific or definitely benign. For example iso-or hyper-echogenicity with spongiform internal content are considered to be the most reliable criteria for benignity of the TN¹⁶.

The limitations of this study include the fact that it is hospital based which may imply a selection bias since only patients who presented in the teaching hospital setting were recruited for the study. In addition cytology, rather than histology which is more sensitive for tissue diagnosis, was used as a gold standard in this study.

4. CONCLUSION

Our findings suggest that on high resolution USS, thyroid nodules with ill-defined margins, microcalcification and those nodules with more than 4 of the 7 sonographic features suggesting malignancy considered in this study may be treated as malignant. We recommend that such thyroid nodules should be subjected to definitive tissue diagnosis. Furthermore a larger community based study preferably using histopathology rather than cytological correlation will further evaluate the potential of ultrasound in the evaluation of malignant thyroid nodules among in our population.

CONSENT (WHERE EVER APPLICABLE)

All authors declare that 'written informed consent was obtained from the patient (or other approved parties) for publication of this case report and accompanying images. A copy of the written consent is available for review by the Editorial office/Chief Editor/Editorial Board members of this journal."

ETHICAL APPROVAL (WHERE EVER APPLICABLE)

All authors hereby declare that all experiments have been examined and approved by the appropriate ethics committee and have therefore been performed in accordance with the ethical standards laid down in the 1964 Declaration of Helsinki.

REFERENCES

1. Olusola-Bello MA, Agunloye AM, Adeyinka AO. Ultrasound prevalence and characteristics of incidental thyroid lesions in Nigerian adults. African journal of medicine and medical sciences. 2013 Jun; 42(2):125-30. PMID: 24377197
2. McQueen AS, Bhatia KS. Thyroid nodule ultrasound: technical advances and future horizons. Insights into imaging. 2015 Apr 1; 6(2):173-88. DOI: 10.1007/s13244-015-0398-9
3. Pompili GG, Tresoldi S, Ravelli A, Primolevo A, Leo GD, Carrafiello G. Use of the ultrasound-based total malignancy score in the management of thyroid nodules. Ultrasonography. 2018 Oct; 37(4):315-322 DOI: 10.14366/usg.17063
4. Chaudhary V, Bano S. Thyroid ultrasound. Indian journal of endocrinology and metabolism. 2013 Mar-Apr; 17(2):219-227. DOI: 10.4103/2230-8210.109667; PMID: 23776892
5. Hoang JK, Lee WK, Lee M, Johnson D, Farrell S. US Features of thyroid malignancy: pearls and pitfalls. Radiographics. 2007 May - Jun; 27(3):847-60. DOI: 10.1148/rg.273065038; PMID: 17495296
6. Durr-e-Sabih KR. Thyroid Nodule Imaging, Status and Limitations. Asia Oceania Journal of Nuclear Medicine and Biology. 2015 Winter; 3(1):50-57

7. Kim DW, Park JS, In HS, Choo HJ, Ryu JH, Jung SJ. Ultrasound-based diagnostic classification for solid and partially cystic thyroid nodules. *American Journal of Neuroradiology*. 2012 Jun 1; 33(6):1144-1149. DOI: 10.3174/ajnr.A2923; PMID: 22300928
8. Rahbari R, Zhang L, Kebebew E. Thyroid cancer gender disparity. *Future Oncology*. 2010 Nov; 6(11):1771-1779. DOI: 10.2217/fon.10.127
9. Wienke JR, Chong WK, Fielding JR, Zou KH, Mittelstaedt CA. Sonographic features of benign thyroid nodules: interobserver reliability and overlap with malignancy. *Journal of Ultrasound in Medicine*. 2003 Oct 1;22(10):1027-1031. PMID: 14606557
10. Nilubol N, Zhang L, Kebebew E. Multivariate analysis of the relationship between male sex, disease-specific survival, and features of tumor aggressiveness in thyroid cancer of follicular cell origin. *Thyroid*. 2013 Jun 1; 23(6):695-702. DOI: 10.1089/thy.2012.0269; PMID: 23194434
11. Papini E, Guglielmi R, Bianchini A, Crescenzi A, Taccogna S, Nardi F, Panunzi C, Rinaldi R, Toscano V, Pacella CM. Risk of malignancy in nonpalpable thyroid nodules: predictive value of ultrasound and color-Doppler features. *The Journal of Clinical Endocrinology & Metabolism*. 2002 May; 87(5):1941-1946. DOI: 10.1210/jcem.87.5.8504; PMID: 11994321
12. Ozel A, Erturk SM, Ercan A, Yilmaz B, Basak T, Cantisani V, Basak M, Karpaz Z. The diagnostic efficiency of ultrasound in characterization for thyroid nodules: how many criteria are required to predict malignancy?. *Medical ultrasonography*. 2012 Mar ;14(1):24 - 28. PMID: 22396935
13. Anil G, Hegde A, Chong FV. Thyroid nodules: risk stratification for malignancy with ultrasound and guided biopsy. *Cancer Imaging*. 2011 Dec 28;11:209 – 223. DOI: 10.1102/1470-7330.2011.0030; PMID: 22203727
14. Unsal O, Akpınar M, Turk B, Ucak I, Ozel A, Kayaoglu S, Coskun BU. Sonographic scoring of solid thyroid nodules: effects of nodule size and suspicious cervical lymph node. *Brazilian journal of otorhinolaryngology*. 2017 Feb;83(1):73-79. DOI: 10.1016/j.bjorl.2016.01.013
15. Iannuccilli JD, Cronan JJ, Monchik JM. Risk for malignancy of thyroid nodules as assessed by sonographic criteria. *Journal of Ultrasound in Medicine*. 2004 Nov 1; 23 (11):1455-1464. DOI: 10.7863/jum.2004.23.11.1455; PMID: 15498910
16. Chaudhary V, Bano S. Thyroid ultrasound. *Indian journal of endocrinology and metabolism*. 2013 Mar;17(2):219. DOI: 10.4103/2230-8210.109667