

# **Changes in intraocular pressure and anterior chamber depth after phacoemulsification in non-glaucomatous patients**

## **ABSTRACT**

**Aims:** To evaluate changes in intraocular pressure (IOP) and anterior chamber depth (ACD) after uneventful phacoemulsification with intraocular lens (IOL) implantation.

**Study design:** Prospective interventional comparative study.

**Place and Duration of Study:** Department of Ophthalmology, Assuit University Hospital between September 2016 and October 2017 .

**Methodology:** 100 Patients with visually significant cataract (39 males (39%) and 61 females (61%). All patients underwent uneventful phacoemulsification. Intraocular pressure and ACD were measured preoperatively by using Goldmann applanation tonometer and Ultrasonography respectively , and at 1 week, 1 month, and 3 months postoperatively.

**Results:** The postoperative ACD was higher than the preoperative value by  $0.26 \pm 0.06$  mm at 1 week,  $0.45 \pm 0.06$  mm at 1 month, and  $0.59 \pm 0.08$  mm at 3 months postoperatively ( $P=0.000$ ).  $P < 0.05$  was considered to indicate a statistically significant difference. The IOP at 1 week, 1 month, and 3 months postoperatively was lower than the preoperative value by  $1.03 \pm 0.3$  mmHg,  $1.52 \pm 0.46$  mmHg, and  $2.14 \pm 0.62$  mmHg, respectively ( $P=0.001$ ). **Conclusion:** This study revealed that there was a decrease in IOP and increase in ACD after cataract extraction by phacoemulsification. Patients with ocular hypertension, open-angle glaucoma, and narrow-angle glaucoma may benefit from cataract extraction.

*Keywords: cataract, phacoemulsification, intraocular pressure, anterior chamber depth.*

## **1. INTRODUCTION**

Cataract surgery is one of the most common surgeries performed in the world. In addition to its significant impact on improvement of visual acuity, phacoemulsification also decreases the intraocular pressure (IOP) [1]. Cataract and glaucoma are ranked as the leading causes of blindness worldwide [2]. There are anatomical and physiological factors that influence IOP reduction after phacoemulsification. Pre-operative angle configuration is considered one of the main factors contributing to this variability. After lens removal, even eyes without glaucoma experience anatomical changes in the anterior chamber, and many biometrical factors are modified [3,4,5]. IOP reduction depends on anatomical factors, especially in patients with a narrow angle [6,7]. Different mechanisms that decrease IOP are as follows:

---

**1.1** Lens removal allows the posterior capsule to move posteriorly, dislodging the zonula over the ciliary body with a consequent widening of the Schlemm's canal and -increased aqueous humor drainage [8,9].

**1.2** The ultrasound radiation used in the phacoemulsification procedure is responsible for a sudden rise in the anterior chamber pressure, producing inflammatory cytokines (mostly IL-1) that stimulate metalloproteinase production and trabecular meshwork remodeling, improving aqueous humor drainage [10,11].

**1.3** Inflammation induced by cataract surgery leads to ciliary body shut-down and reduction in IOP. Anterior capsular shrinkage after capsulorhexis leads to traction on the ciliary body and decreases aqueous humor production [12].

## 2. MATERIAL AND METHODS

One hundred patients with visually significant cataract who visited the outpatient clinic in the Department of Ophthalmology, Assuit University Hospital between September 2016 and October 2017 were included in this prospective comparative study. All patients underwent cataract extraction by uneventful phacoemulsification.

**2.1 Inclusion Criterion:** Significant cataract affecting vision

**2.2 Exclusion criteria:** A history of trauma, glaucoma, or previous ocular surgery; complicated cataract; use of steroids as topical or systemic medications; and corneal opacity.

**2.3 Ethical aspects:** Consent for participation in the study was obtained from the patients and their confidentiality was maintained. Refusal to participate in the study by any patient did not affect the quality of his/her treatment.

**2.4 Pre-operative evaluation:** All the patients included in this study underwent the following clinical evaluations 1 day before the surgery:

1. Measurement of uncorrected and best corrected visual acuity.
2. Detailed ocular examination including slit lamp anterior segment and fundus examination.
3. Measurement of IOP using the Goldmann applanation tonometer AT900, [Haag-Streit 900 series slit lamp].
4. Measurement of anterior chamber depth (ACD) by A-scan (EZ SCAN™ AB5500+ SONOMED, USA).
5. Medical fitness for all patients: Complete blood count, Blood pressure, Random blood sugar.

**2.5 Surgical technique:** Cataract removal by phacoemulsification was performed under peribulbar anesthesia. Draping of the eyelids and eyelashes was done to isolate these areas from the surgical field. Two small incisions and one main incision were made through the clear cornea and viscoelastic was injected into the anterior chamber. Capsulorhexis was performed, which was continuous, curvilinear, and central. Hydro-dissection was performed to separate the nucleus and cortex from the capsule, which simplified the rotation of the nucleus .

The phaco-probe was introduced into the anterior chamber of the eye. Removal of the nucleus was performed by the divide and conquer, phaco chop (vertical or horizontal chop), or stop and chop technique. The lens cortex was removed by aspiration. Before the insertion of the intraocular lens, the capsule was filled with viscoelastic. The intraocular lens was then inserted in the capsular bag with a special injector. Viscoelastic was removed from the anterior chamber by aspiration. The incisions were sealed by stromal hydration. Finally, a subconjunctival injection of steroids and antibiotics was given to prevent infection .

**2.6 Postoperative evaluation:**

The patients were followed up at 1 week, 1 month, and 3 months postoperatively to measure the IOP and ACD, and to identify any postoperative complications.

### 3. RESULTS AND DISCUSSION

The study included 100 eyes (52 left and 48 right eyes) of 100 patients (39 males and 61 females). Seventeen patients were younger than 50 years, 29 were between 50 and 60 years, 31 were between 60 and 70 years, and 23 patients were older than 70 years. The mean age of the patients was  $60.70 \pm 10.04$  years.

Preoperative and postoperative variation of ACD:

Preoperatively, the ACD was  $3.19 \pm 0.39$  mm. It was  $3.45 \pm 0.45$  mm at 1 week postoperatively,  $3.64 \pm 0.45$  mm at 1 month postoperatively, and  $3.64 \pm 0.45$  mm at 3 months postoperatively (figure 1).

The ACD increased by  $0.26 \pm 0.06$  mm in the 1<sup>st</sup> postoperative week, by  $0.45 \pm 0.06$  mm in the 1<sup>st</sup> postoperative month, and by  $0.59 \pm 0.08$  mm by the 3<sup>rd</sup> postoperative month (table 1).

Difference between preoperative and postoperative IOP:

The mean preoperative IOP was  $15.28 \pm 3.12$  mmHg; the corresponding values at 1 week, 1 month, and 3 months postoperatively were  $14.28 \pm 2.82$  mmHg,  $13.76 \pm 2.66$  mmHg, and  $13.14 \pm 2.50$  mmHg, respectively (fig 2). The IOP decreased by  $1.03 \pm 0.3$  mmHg,  $1.52 \pm 0.46$  mmHg, and  $2.14 \pm 0.62$  mmHg in 1 week, 1 month, and 3 months postoperatively (table 2).

Correlation between IOP and ACD:

There was a statistically significant negative correlation between ACD and IOP at 1 week postoperatively ( $r = -0.222$ ;  $P = 0.027$ ) (figure 3) and 3 months postoperatively (figure 4) ( $r = -0.222$ ;  $P = 0.026$ ); however, there was no statistically significant correlation between preoperative ACD and IOP ( $r = -0.160$ ;  $P = 0.111$ ) and those at 1 month postoperatively ( $r = -0.099$ ;  $P = 0.327$ ) (table 3).

**Table (1): Comparison between preoperative and postoperative ACD.**

ACD (mm)	Preoperative (n= 100)	After 1 week (n= 100)	After 1 month (n= 100)	After 3 months (n= 100)
Mean $\pm$ SD	$3.19 \pm 0.39$	$3.45 \pm 0.45$	$3.64 \pm 0.45$	$3.78 \pm 0.47$
Range	2.5 - 4.7	2.6 - 4.7	3.0 - 4.9	3.0 - 4.9
P-value		0.000*	0.000*	0.000*

**Table (2): Comparison between preoperative and postoperative IOP:**

IOP (mmHg)	Preoperative (n= 100)	After 1 week (n= 100)	After 1 month (n= 100)	After 3 months (n= 100)
Mean $\pm$ SD	$15.28 \pm 3.12$ mmHg	$14.28 \pm 2.82$ mmHg	$13.76 \pm 2.66$ mmHg	$13.14 \pm 2.50$ mmHg
Range	13.0 - 22.0	12.0 - 19.0	11.0 - 20.0	11.0 - 19.0
P-value		0.001*	0.001*	0.000*

**Table (3): Correlation between ACD and IOP**

	IOP		ACD			
			Preoperative (mm)	1 week (mm)	1 month (mm)	3 months (mm)
IOP	Preoperative	r-value	-0.160			

	(mmHg)	P-value	0.111			
<b>1 week</b>		r-value		-0.222		
	(mmHg)	P-value		0.027*		
<b>1 month</b>		r-value			-0.099	
	(mmHg)	P-value			0.327	
<b>3 months</b>		r-value				-0.222
	(mmHg)	P-value				0.026*

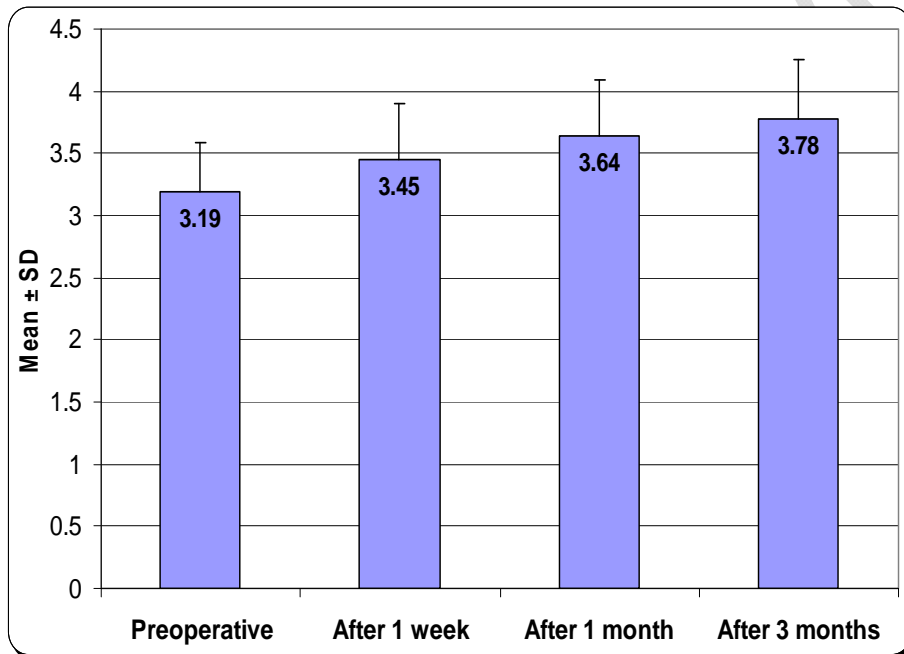


Figure (1): Difference between preoperative and postoperative ACD

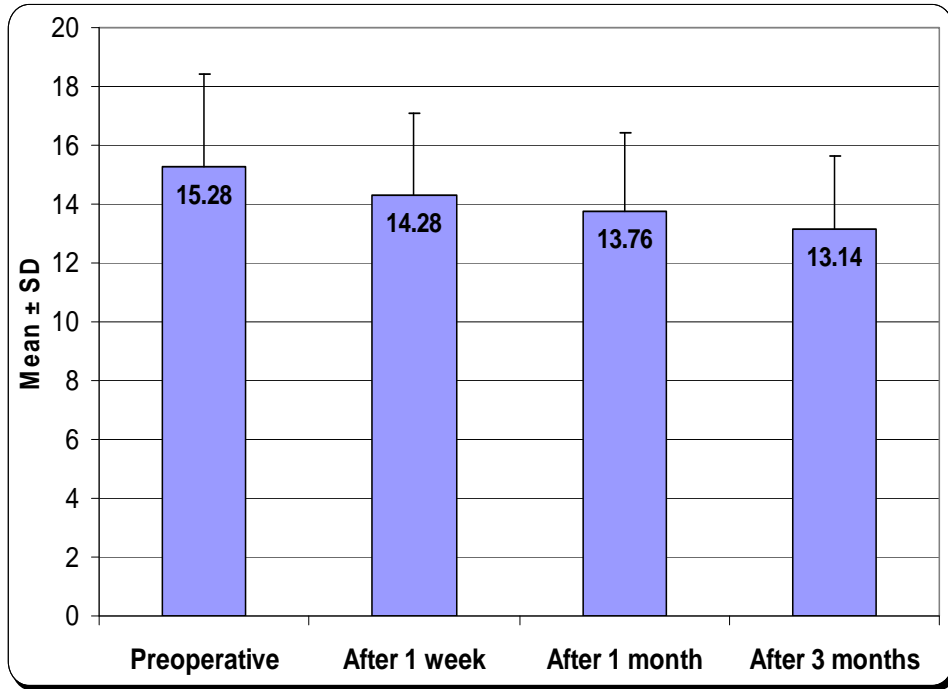


Figure (2): Comparison between preoperative and postoperative IOP

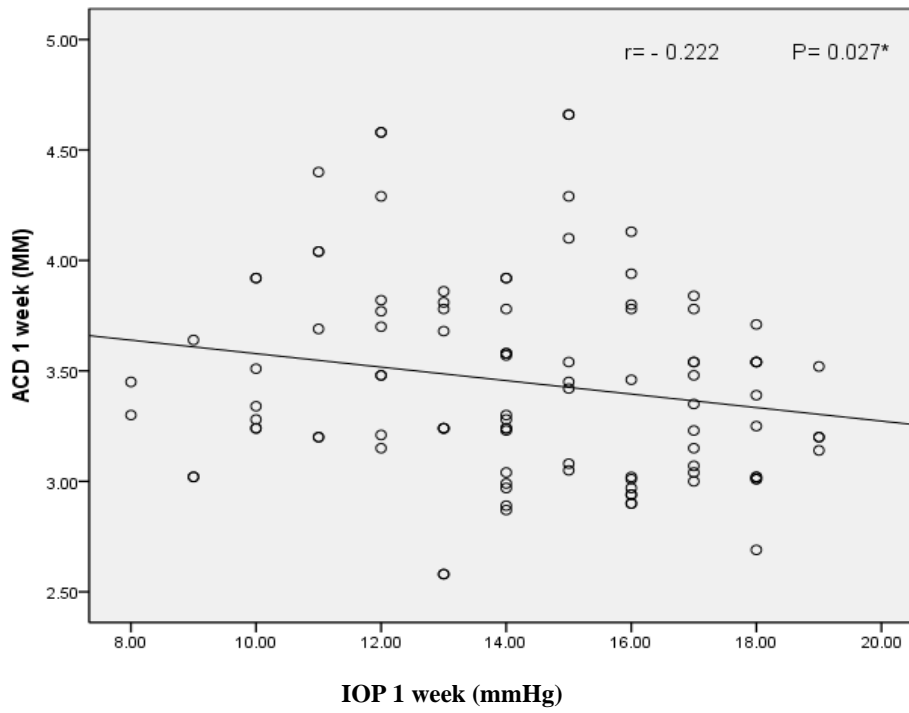
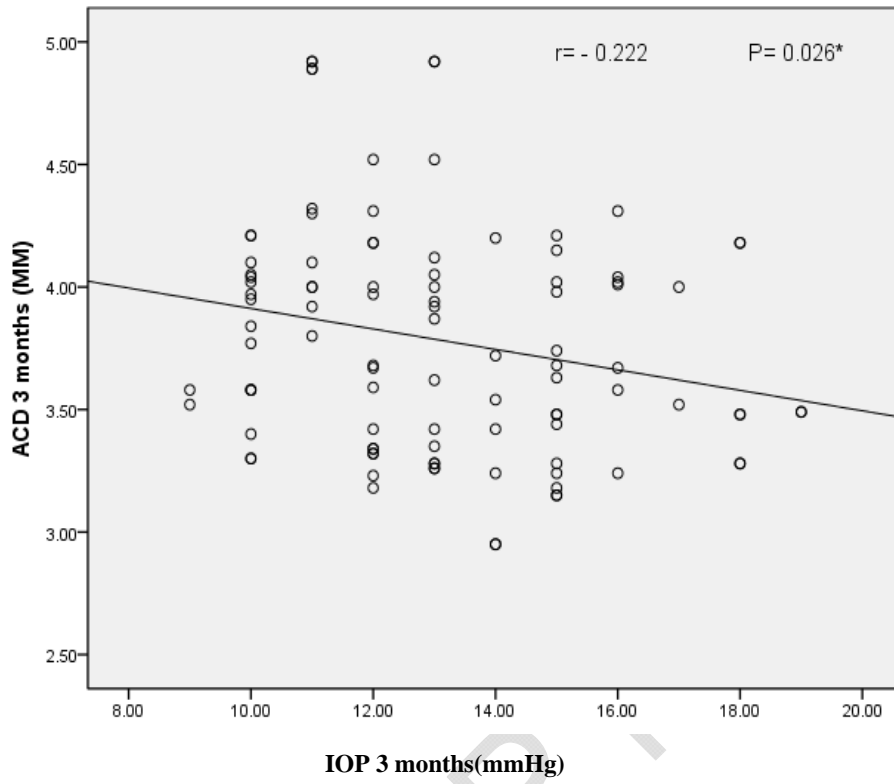


Figure (3): Correlation between ACD and IOP after one week



**Figure (4): Correlation between ACD and IOP after three months**

## Discussion

This study is one of the rare studies performed on 100 (39 males and 61 females) non-glaucomatous patients who underwent uneventful phacoemulsification surgery. They were recruited from the outpatient clinic of the Ophthalmology Department, Assiut University Hospital, between September 2016 and October 2017. The ages of the patients ranged from 40 to 82 years. IOP and ACD were measured 1 day before surgery, and at 1 week, 1 month, and 3 months postoperatively. The IOP was measured with a Goldmann applanation tonometer, and ACD with A-Scan. The present study revealed that ACD was significantly increased at 1 week, 1 month, and 3 months after uneventful phacoemulsification cataract surgery; the respective increases in ACD were 0.1 mm, 0.2-0.5 mm, and 0.2-0.5 mm, respectively. The mean ACD was  $3.19 \pm 0.39$  mm preoperatively,  $3.45 \pm 0.45$  mm at 1 week postoperatively,  $3.64 \pm 0.45$  mm at 1 month postoperatively, and  $3.78 \pm 0.47$  mm at 3 months postoperatively. The results of the study conducted by Mustafa Kamal Junejo, and associates [13] were similar to those of our study; they showed that there was a statistically significant increase in the mean ACD, from  $3.02 \pm 0.43$  mm preoperatively to  $3.81 \pm 0.46$  mm 1 month after the surgery ( $p < 0.0001$ )—an increase of  $0.73 \pm 0.58$  mm. However, when mean ACD 1 month after the surgery was compared between male ( $3.83 \pm 0.49$  mm) and female ( $3.77 \pm 0.43$  mm) groups, no statistically significant difference was observed ( $p = 0.42$ ). In our study there are statistically significant differences of ACD between male and female groups at one week, one month, and three months postoperatively ( $p = 0.037$ ,  $p = 0.015$ , and  $p = 0.013$  respectively). In Mustafa Kamal Junejo, et al.'s study, 74 patients (74 eyes in 42 males and 32 females) underwent Ultrasonography A-scan to evaluate anterior chamber configuration before, one day after, one week after and one month postoperatively; however, in our study, we evaluated patients for longer period i.e., up to three months postoperatively. We also measured central ACD. Preoperative and postoperative data was compared by using paired tests [13]. Another study that is comparable to our study is by S Moghim et al (2015), [14] which comprised 99 eyes of 99 consecutive patients who underwent cataract surgery, of which 14 eyes were excluded because of the inability to detect the scleral spur in anterior segment optical coherence tomography (AS-OCT) images. IOP and biometric parameters were measured by AS-OCT preoperatively and three months after surgery, unlike our study in which, IOP was measured by Goldman applanation tonometer and biometric parameters by A-scan. Out of the 85 patients included in the analysis, 35 were male and 50 were female with an average age of  $62.2 \pm 8.9$  (37–81) years. Forty-six patients had narrow angle glaucoma and 39 patients had open angle glaucoma; however, in our study, we excluded any glaucomatous patients. Preoperatively, the average IOP was  $17.12 \pm 2.47$  mm Hg, which dropped to  $12.20 \pm 2.69$  mm Hg at three months with an average change of  $4.95 \pm 2.26$  mm Hg ( $P < 0.001$ ) [14].

Another study that is in concordance with our study [15] showed that clear corneal phacoemulsification (CCP) was associated with a statistically significant reduction in IOP. The study was done on 273 normal patients selected for cataract extraction by phacoemulsification, however, our study included only 100 patients. IOP was measured by Goldmann applanation tonometer by the same examiner preoperatively, on the 15th day, and subsequently one, two, three and six months after surgery. Patients with the history of ocular surgery, trauma, preoperative IOP greater than 21 mmHg, on ocular medication and who developed postoperative complication were excluded from the study [15]. The study showed that the mean IOP before surgery was  $14.18 \pm 3.4$  mmHg. Patients showed a mean decrease in IOP of 2.25 mmHg (16%) compared to preoperative values. The postoperative IOP was inversely related to preoperative ACD ( $P = 0.012$ ). Changes of IOP was significantly correlated with change in ACD ( $P = 0.002$ ) [10]. However, in our study, there is significant correlation between IOP and ACD measured at one week ( $r = -0.222$ ;  $p$ -value = 0.027) and three months postoperatively ( $r = 0.222$ ;  $p$ -value = -0.026), and no statistically significant difference between IOP and ACD measured preoperatively ( $r = -0.160$ ;  $p$ -value = 0.111) and one month postoperative ( $r = -0.099$ ;  $p$ -value = 0.327) [15].

One of the studies that had comparable results to our study [16] reported that there was increase in ACD, and widening of irideo corneal angle (ICA) in non-glaucomatous eyes after uneventful phacoemulsification. The changes were statistically significant over 6 months. The study was performed on Fifty-three eyes of 49 patients and they were evaluated for 6 months postoperatively [16].

The mean preoperative ICA grade of  $2.97 \pm 0.72$  increased to  $3.55 \pm 0.48$  at 1 week and  $3.68 \pm 0.45$  at 1 month ( $P = 0.03$ ). The mean preoperative ACD of  $3.06 \pm 0.49$  mm increased to  $3.57 \pm 0.47$  mm at 4 weeks,  $3.69 \pm 0.32$  mm at 1 month, and  $3.70 \pm 0.36$  mm at 3 months ( $P = 0.012$ ) [16].

On the other hand, there were several studies that had results different from our results. These studies showed that there were no statistically significant differences between preoperative IOP and postoperative IOP. One of these studies [17] reported that no statistically significant difference in terms of changes in IOP could be attributed to phacoemulsification with posterior chamber intraocular lens type (IOP:  $p = 0.665$ ) [17]. The study was performed on 103 eyes of 103 patients without ocular co-morbidity, all of whom underwent phacoemulsification. ACD and IOP were recorded 1-2 weeks preoperatively, 8-9 weeks postoperatively and 4 weeks after stopping steroid therapy. Mean preoperative and postoperative IOP was 15.23 (2.47) mmHg and 12.68 (1.65) mmHg respectively, and this represented a mean drop of 2.55 (1.78) mmHg. The extent of IOP reduction postoperatively was directly related to preoperative IOP ( $r = 0.745$ ;  $r^2 = 56\%$ ;  $p = 0.01$ ) [17].

## 4. CONCLUSION

This study proves that there was a decrease in IOP and increase in ACD after cataract extraction by phacoemulsification with intraocular lens implantation which help in aqueous drainage by pushing back iris lens diaphragm and widening anterior chamber angle .

## CONSENT

**AWRITTEN INFORMED CONSENT WAS OBTAINED FROM ALL PATIENTS PARTICIPATED IN THE STUDY AFTER EXPLAINAING THE WHOLE PROCEDURE AND COMPLICATIONS.**

## ETHICAL APPROVAL

**ALL AUTHORS HEREBY DECLARE THAT APPROVAL WAS OBTAINED FROM THE MEDICAL RESEARCH ETHICS COMMITTEE OF THE SCIENTIFIC RESEARCH , FACULTY OF MEDICINE, ASSIUT UNIVERSITY THAT ADHERED TO THE TENTS OF THE DECLARATION OF HELSINKI.**

## REFERENCES

- 1.Quigley HA, Broman AT: The number of people with glaucoma worldwide in 2010 and 2020. Br J Ophthalmol 2006; 90: 262–267.
- 2.Pascolini D, Mariotti SP: Global estimates of visual impairment: Br J Ophthalmol 2012; 96: 614–618.
- 3.Maloney WF, Dillman DM, Nichamin LD: Supracapsular phacoemulsification: a capsule-free posterior chamber approach. J Cataract Refract Surg 1997; 23: 323–328.
- 4.Huang G, Gonzalez E, Lee R, Chen Y-C, He M, Lin SC,: Association of biometric factors with anterior chamber angle widening and intraocular pressure reduction after uneventful phacoemulsification for cataract. J Cataract Refract Surg 2012; 38: 108–116.
- 5.Shingleton BJ, Gamell LS, O'Donoghue MW, Baylus SL, King R: Long-term changes in intraocular pressure after clear corneal phacoemulsification: Normal patients versus glaucoma suspects and glaucoma patients: J Cataract Refract Surg 2005; 25: 885–890.
- 6.Kanski JJ (2007) *Clinical ophthalmology* (Sixth edition) Edinburgh: Elsevier Butterworth-Heinemann
- 7.Yang HS, Lee J, Choi S: Ocular biometric parameters associated with intraocular pressure reduction after cataract surgery in normal eyes. Am J Ophthalmol 2013; 156: 89–94.
- 8.Shrivastava A, Singh K: The effect of cataract extraction on intraocular pressure. Curr Opin Ophthalmol 2010; 21: 118–122.
- 9.Pohjalainen T, Vesti E, Uusitalo RJ, Laatikainen L: Intraocular pressure after phacoemulsification and intraocular lens implantation in nonglaucomatous eyes with and without exfoliation. J Cataract Refract Surg 2001; 27: 426–431.
- 10.Mansberger SL, Gordon MO, Jampel HD, Bhorade A, Brandt JD, Wilson B, et al: Reduction in intraocular pressure after cataract extraction: the Ocular Hypertension Treatment Study. Ophthalmology 2012; 119: 1826–1831.
- 11.Shin HC, Subrayan V, Tajunisah I: Changes in anterior chamber depth and intraocular pressure after phacoemulsification in eyes with occludable angles. J Cataract Refract Surg. 2010;36:1289–1295.
- 12.Takmaz T, Edinburgh P: Elsevier Butterworth-Heinemannter clear corneal phacoemulsification: Normal patients versus glaucoma suspects and glaucoma patients: J Sci 2013; 43: 289–293.
- 13.Junejo MK, Chaudhry TA: Anterior chamber depth changes after uneventful phacoemulsification. Pak J Ophthalmol 2016; 32(1): 30-34
14. Moghimi S, Abdi F, Latifi G, Fakhraie G, Ramezani F, He M, Lin SC: Lens parameters as predictors of intraocular pressure changes after phacoemulsification, J Eye (Lond) 2015; 29(11): 1469–1476.
- 15.Bhallil S, Andalousi IB, Chraibi F, Daoudi K, Tahri H: Changes in intraocular pressure after clear corneal phacoemulsification in normal patients. Oman J Ophthalmol- 2009-; 2(3): 111–113.
16. Altan C , Bayraktar S, Altan T, Eren H, Yilmaz O F: Anterior chamber depth, iridocorneal angle width, and intraocular pressure changes after uneventful phacoemulsification in eyes without glaucoma and with open iridocorneal angles, Journal of Cataract & Refractive Surgery , 2004 April:30(4) ; 832-838.



17. Issa SA, Pacheco J, Mahmood U, Nolan J, Beatty S: A novel index for predicting intraocular pressure reduction following cataract surgery. *Br J Ophthalmol* 2005; 89: 543–546.

**DEFINITIONS, ACRONYMS, ABBREVIATIONS**

*IOP: Intraocular pressure*

*ACD: Anterior chamber depth*

*AS-OCT: Anterior segment optical coherence tomography*

UNDER PEER REVIEW