

# Non-Traditional Route for Three Antifungal Drugs in Fungal Keratitis Treatment

## ABSTRACT

**Aims:** This study aims to evaluate the efficacy of the intrastromal route of antifungal drugs in treatment of fungal keratitis.

**Study design:** Prospective single arm interventional clinical study

**Place and Duration of Study:** Ophthalmology Department, Assiut University Hospital, between March 2016 to November 2017.

**Methodology:** Corneal scrapings for direct smears and cultures were done for eighteen eyes of 18 consecutive patients and intrastromal injections were given according to sensitivity results.

**Results:** After one month of follow up of the cases in this study, 33.3% of the cases had rapid complete cure and the rest had incomplete cure with resolution of ulcer sizes by 55.34%  $\pm$ 6.78 after one or more intrastromal injection of antifungal drugs.

**Conclusion:** Intrastromal injection of antifungal drugs in treatment of fungal keratitis shows promising results in advanced cases of fungal keratitis when combined with the topical route.

*Keywords: fungal keratitis, intrastromal injection, antifungal drugs, fluconazole, amphotericin B, voriconazole.*

## 1. INTRODUCTION

Fungal keratitis is a devastating ocular infection leading to significant visual morbidity caused by a variety of fungal species capable of colonizing ocular tissues. (1)

Trauma to the corneal epithelium (by means of e.g. vegetative matter, previous eye surgery or contact lens abuse) leads to an epithelial defect through which fungi can gain access to the corneal stroma and cause inflammation and necrosis. Consequently, the organisms can cause intraocular infection when they reach the anterior chamber and posterior segment through penetrating an intact Descemet's membrane. Further damage can be caused by mycotoxins and proteolytic enzymes. (2) Previous literature described the occurrence of fungal keratitis secondary to fungal endophthalmitis. (3)

It was found that filamentous fungi are predominant in hot climates, commonly preceded by previous agricultural trauma, while yeasts are more frequent in temperate ones. (4) Risk factors, other than geographic ones, include ocular surface disease, topical steroid use and immunocompromised patients. (5, 6)

Fungal keratitis is primarily a clinical diagnosis based on highly suggestive clinical picture including; feathery borders, raised surface, satellite lesions, presence of a gutter surrounding a white "immune ring" and a thick, cheesy and dome-shaped hypopyon. (7) Meanwhile, some cases may be confusing, and a laboratory workup is mandatory for organism specification and drug choice based on sensitivity results. Tools for laboratory diagnosis include corneal scraping for direct smear examination with special stains under microscope and specific culture media such as Sabouraud dextrose agar. Other methods include ELISA, electrophoresis and immune diffusion; all of which depend on identifying enzymes produced by the fungus. Confocal microscopy aids in fungus identification. (8)

Treating fungal keratitis is basically through medical route, where antifungal preparations are used in the form of eye drops. The most common and commercially available one is the polyene, natamycin 5%. Amphotericin B, another polyene, was used before the development of natamycin; either one of them can be used as an initial therapy. (9) Other antifungal drugs that can be prepared for topical use include fluconazole, voriconazole, miconazole, ketoconazole and posaconazole. Some studies were conducted to assess the efficacy of oral route of some antifungal drugs such as voriconazole, posaconazole and terbinafine which showed variable success against different fungal species. (2, 10, 11) Topical fluconazole via liposomes, a drug delivery system, was found to be successful especially against *Candida albicans* keratitis (12)

Though antifungal choices are vast, poor penetration and limited response to treatment are commonly encountered, that eventually lead to surgical intervention. Surgery include periodic debridement, conjunctival flap and therapeutic keratoplasty either lamellar or full-thickness. (13, 14)

Many studies concerning intrastromal injection of antifungal drugs in cases of fungal keratitis were conducted over the past years on different groups of patients using different antifungal agents and comparing the results with those of other modes of drug administration. This study aims at evaluating the efficacy of intrastromal injection of antifungal drugs on proved fungal keratitis cases as an adjuvant route of administration of the antifungal drugs.

## **2. MATERIAL AND METHODS**

Eighteen eyes of 18 consecutive patients admitted to Ophthalmology Department, Assiut University Hospital were analyzed prospectively during the period from March 2016 to November 2017.

**2.1.1. Inclusion criteria:**

1. Patients with fungal keratitis (as proved by full microbiological assessment).
2. No administration of antifungal agents within 3 days prior to participation in the study.

**2.1.2. Exclusion criteria:**

1. Non-fungal keratitis.
2. Antifungal therapy within 3 days prior to participation in the study.
3. Patient refusal to participate in the study.

**2.2. Methods:**

*All patients were subjected to the following:*

- 1- Detailed history using a predesigned questionnaire.
- 2- Examination by slit lamp bio-microscopy to measure ulcers' maximum vertical and horizontal diameters, infiltrate depth and anterior chamber examination for the presence of any hypopyon and measuring its height.
- 3- Informed consent was obtained from all cases. Patient's confidentiality was respected. Patient's refusal of participation in the study did not affect the quality of treatment they had received in the hospital.
- 4- Corneal scrapings were obtained for microbiological examination. as follows; topical anesthetic was instilled prior to corneal scraping. Then, corneal scraping was obtained by using a sterile surgical blade (no.11) by scraping the ulcer deeply at its base with caution, especially in the case of central corneal thinning.
- 5- Direct smear with wet mount potassium hydroxide procedure was done, in addition to culturing of the corneal scrapings on top of Sabouraud Dextrose agar plates, all of which were sent to Microbiology Department, Faculty of Medicine Assiut University to determine the presence of mold hyphae or budding yeast cells by examining direct smears under microscope and specifying the fungal species after incubating the culture plates up to two weeks (to exclude the presence of slow growing fungi).

**6- Antifungal Drugs preparation for intrastromal injection:**

- **Fluconazole 0.2% (2mg/ml)**

This concentration is available without the need for preparation. (each 1ml contains 2mg)

- **Amphotericin B 5 to 10 µg/0.1ml**

To reconstitute 10 µg/0.1ml

Method: Prepare 5 mg/ml (as mentioned above) – take 0.2ml solution and add to 0.8ml BSS. Now take 0.1 ml of this solution and add 0.9ml BSS to create 0.1mg/ml equivalent to 10µg/0.1ml. Use Immediately

- **Voriconazole 50 µg/0.1ml**

Method: From 1% solution Voriconazole, take 1ml, add to 19 ml ringer lactate to make 0.05mg/ml (50 µg/0.1ml).

7- Intrastromal injection (for proved cases of fungal keratitis) was performed in the operation theatre in complete aseptic conditions; the procedure was done in all patients as follows:

- Topical anesthetic was instilled.
- The drug was loaded in 30-gauge insulin syringe
- The needle penetrated the cornea obliquely at 30° - 45° with the bevel up in the mid stroma at the clear cornea around the edge of the infiltrate
- The drug was injected slowly in the stroma to induce edema, whose edge touches the edge of the infiltrate
- The injection was given in 3 to 5 divided doses (according to the size of the ulcer and infiltrate) to form a barrage around the lesion.

8- Topical natamycin 5% hourly was added to the ulcer regimen for all cases, in addition to moxifloxacin HCl 0.5% E.D. 5 times daily, cyclopentolate 1% E.D. tid, doxycycline HCl 100 mg tab bid for its anticollagenase effect.

Follow up of the patients was done on the first day, third day, one week, two weeks and one month post-injection.

More than one injection was done in selected cases on the 1<sup>st</sup> and/or 2<sup>nd</sup> weeks after the first injection based on individual circumstances such as ulcer size and response to intrastromal injection.

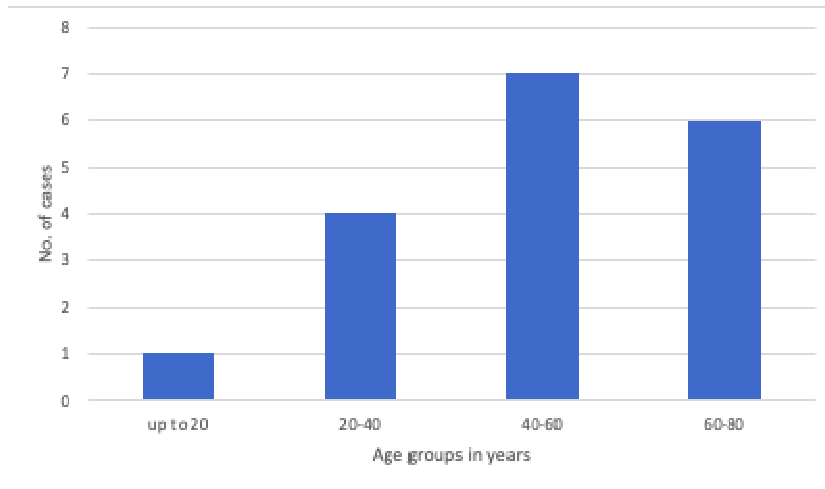
All ulcers were photographed before intervention and on the 30<sup>th</sup> day post-injection via smartphone-based digital imaging.

### **2.3. Statistical Analysis**

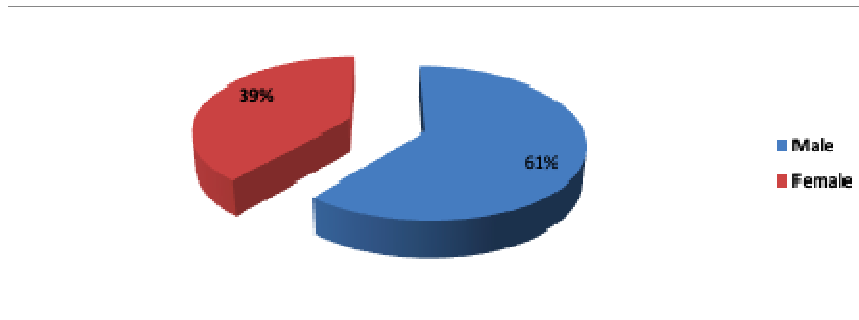
Data collected was entered on Microsoft access data base and was analyzed using the Statistical Package for Social Science (SPSS, Chicago, Version 21.0)

## **3. Results**

**Figure (1): Age distribution in study group**



**Figure (2): Gender distribution in study group**



**Table (1): Clinical data in study group**

Table (1) shows clinical data in study group, with mean of time presentation 14.10 days. As regards mean value of size of ulcer 10.72 mm<sup>2</sup>, also mean value of infiltration size was 14.34 mm<sup>2</sup> and mean value of depth of keratitis was 58%.

Item	Descriptive “n=18”
1- Time of presentation(days)	14.10±8.23
2- Ulcer size(mm <sup>2</sup> )	10.72±2.63
3- Infiltration size(mm <sup>2</sup> )	14.34±3.14
4- Depth of keratitis (%)	58±3

**Figure (3): Causative risk factors in study group.**

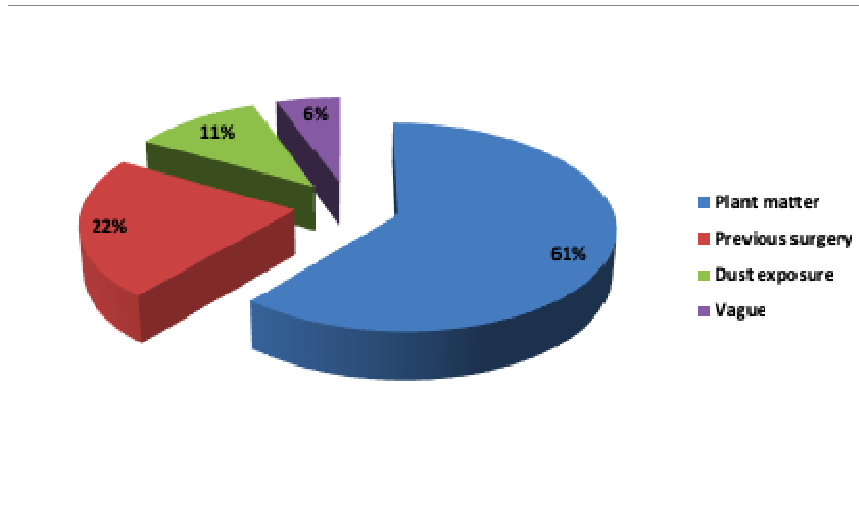


Figure (4): Culture results in study group

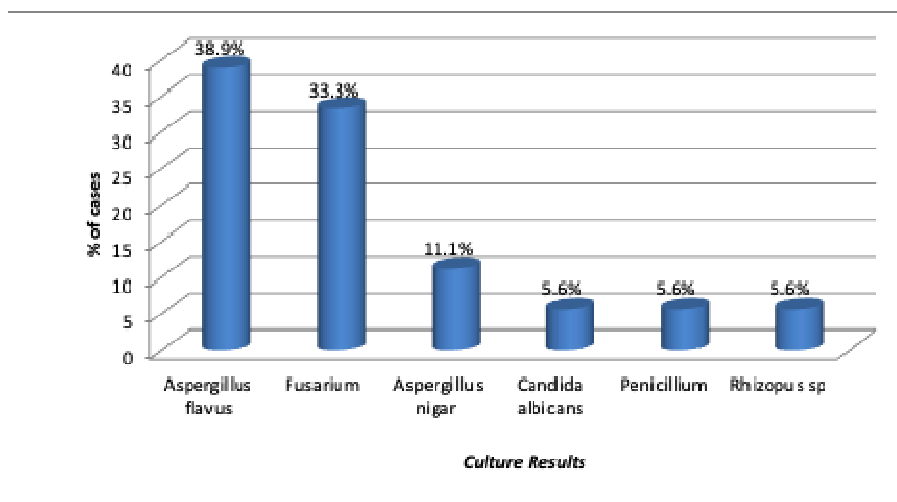
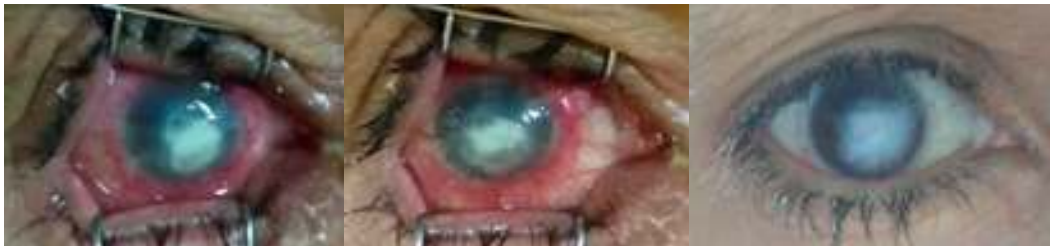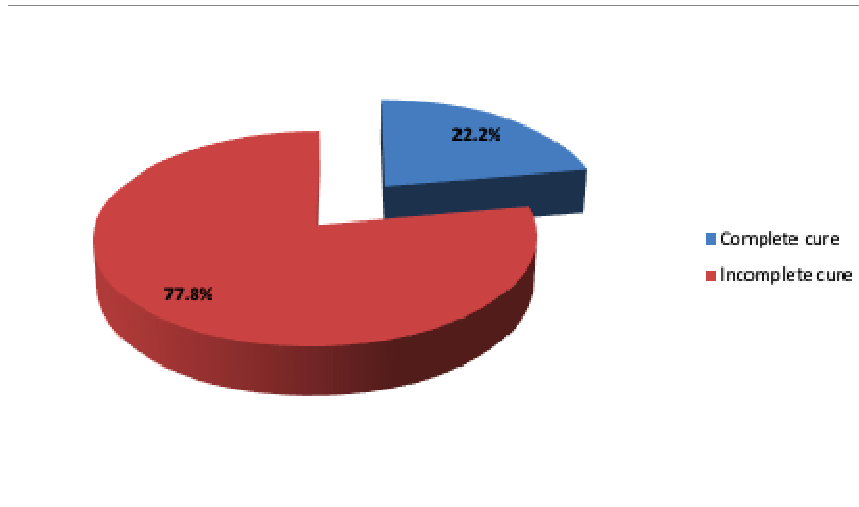
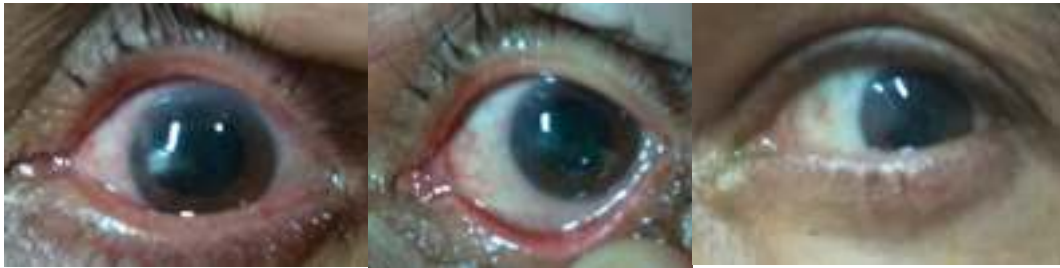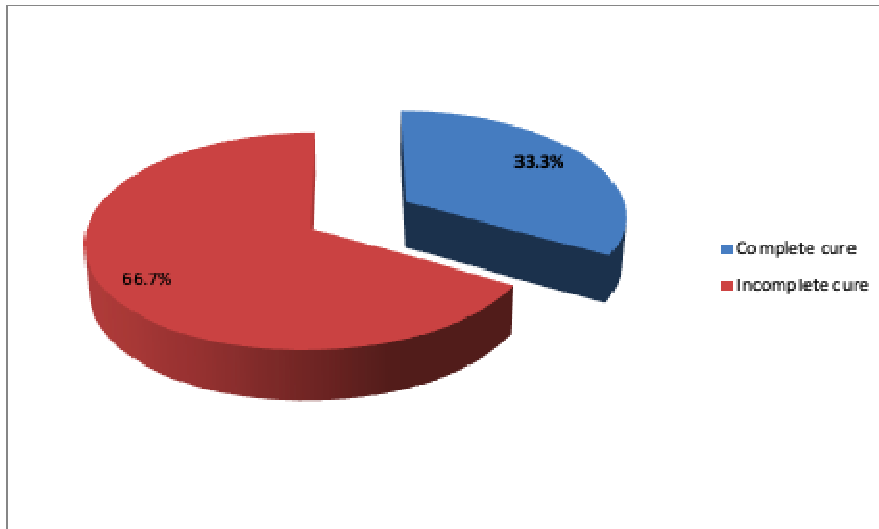


Figure (5): Outcome in study group (after first injection).

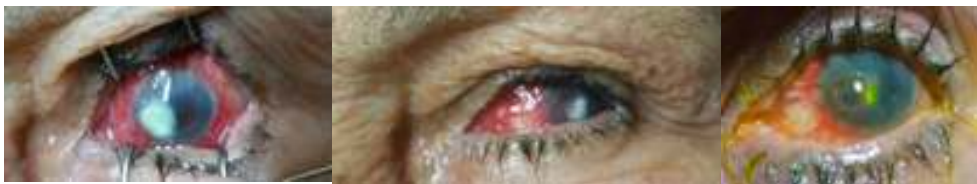

**Figure (6):** shows corneal ulcer before scraping for smearing and culturing *on the left*, corneal ulcer after scraping *in the middle* and outcome after one week of one injection of fluconazole 0.2% resulting in complete cure with dense corneal opacity *on the right*.

**Figure (7):** Outcome in study group (after second injection)



**Figure (8):** shows corneal ulcer before intrastromal injection *on the left*, resulting in incomplete cure after one week of first injection as shown *in the middle* and complete cure after 3 days of second injection *on the right*.



**Figure (9):** shows corneal ulcer before intrastromal injection *on the left*, incomplete cure after two weeks of first injection *in the middle*, incomplete cure with a resultant descemetocoele after one week of the second injection *on the right*.

N. B. Of the two cases that were injected thrice, none of them showed complete cure after the third injection.

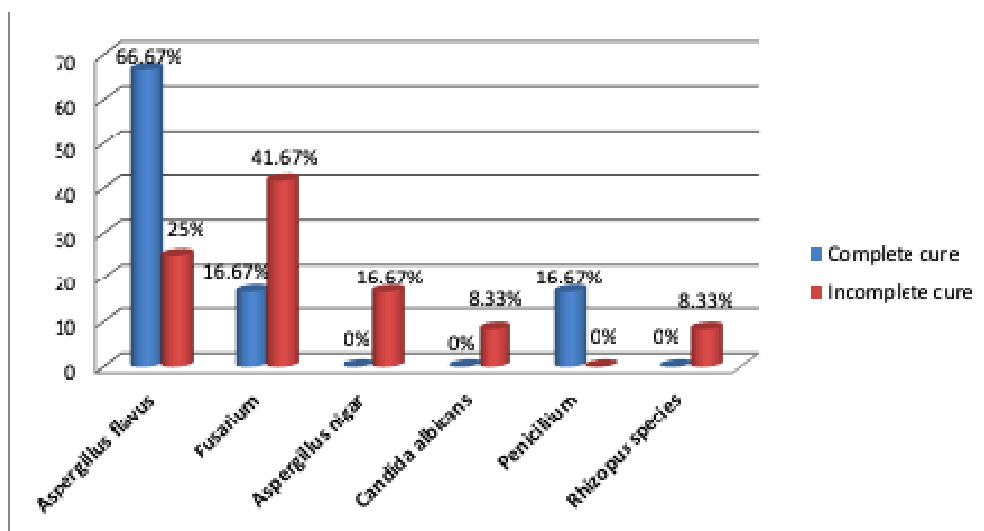
**Table (2): Relation between clinical data & Outcome in study group**

Table (2) shows relation between clinical data & Outcome in study group. There was significant difference ( $P= .05$ ) between patients who had complete cure & incomplete cure with age, time of presentation, ulcer size and depth of keratitis. Also, there was highly significant difference ( $P<0.000$ ) as regards percent of ulcer size change. Regarding to infiltration size, there was non-significant difference ( $P=0.483$ ).

Item	Complete Cure "n=6"	Incomplete cure "n=12"	P-value
1- Age	34.02±16.22	56.35±13.90	$P= .04^*$
2-Time presentation	9.25±4.57	15.48±8.63	$P= .03^*$
3-Ulcer size	4.27±3.05	10.80±3.16	$P= .01^*$
4-Infiltration size	9.04±6.58	15.85±3.59	$P= .483$
5-Depth of keratitis	0.45±0.02	0.62±0.04	$P= .04^*$
6- Percent change of ulcer size	--	55.34±6.78	$P< 0.000^{***}$

**Figure 10: Percent of cases with complete cure and incomplete cure for each fungal species in this study**

Figure (10) shows relation between Culture & Outcome in study group. There was non-significant difference with  $P$ -value = .275 between type of culture and outcome of patients.



According to in vitro sensitivity results, Fluconazole 0.2% was used in 15 cases, Amphotericin B 5-10  $\mu\text{g}/0.1$  ml was used in 2 cases and Voriconazole 50  $\mu\text{g}/0.1$  ml was used in one case.

**Descemetocoele** was noted in two cases after injection, these cases were caused by Candida albicans and Fusarium, both cases showed deep infiltrate up to two-thirds of the corneal thickness.

**Perforation** was noted in one case that showed central thinning prior to intervention. Aspergillus niger was isolated from gentle corneal scraping, that was injected twice with 0.2% Fluconazole. Three days after the second injection, central perforation 0.5 mm in diameter with shallow AC was noted, that was managed by tissue adhesive (Histoacryl glue).

#### 4. Discussion

Fungal keratitis is a vision-threatening infectious disease. In general, the available choices of antifungal drugs are less than those of antibacterial drugs; besides, they have poorer tissue penetration. Therefore, the prognosis of fungal keratitis tends to be worse than bacterial keratitis as according to *Niki, et al.* (15)

Regarding the time needed for the healing of ulcers *in this study*, and following up for one month after intrastromal injection, there was change in ulcer size and infiltration size with percentage 55.34% in 12 patients who had incomplete cure and complete cure (100%) of ulcer in 6 patients. Five out of 6 cases of the complete cure showed rapid healing within one week. This agrees with *Niki, et al.*, (15) who reported that one week after injection, corneal ulcers had healed and corneal infiltrates decreased. Also, this agrees with *Xinying You, et al.* (16) who reported that the healing time was 3–16 days ( $5.1 \pm 3.1$ ), and in 28 cases, the time was less than 7 days (51.9%) with four cases being 3 days in 54 eyes treated with lamellar keratectomy followed by intrastromal injection of fluconazole 0.2%.

Comparing patients with complete cure vs. patients with incomplete cure regarding time of presentation in this study, there was significant difference ( $P < 0.05$ ) being lower in time of presentation in patients who had complete cure 9.25 days vs. 15.48 days in those with incomplete cure. This agrees with *Maja Pauk-Gulić, et al.*, (17), who used topical and intrastromal injection of voriconazole combined with systemic fluconazole in treatment of fungal keratitis in corneal grafts.

All cases were followed up to one month after intrastromal injection, with 22.2% of cases showed complete cure and 77.7% of cases showed incomplete cure after first intrastromal injection, then 33.3% of cases showed complete cure and 66.7% of cases showed incomplete cure after second injection with no further change in outcome after third injection. However, *Yalaka Jayapal Reddy, et al.*, (18) whose follow-up time was up to 6 weeks after injection of thirty cases with voriconazole 50  $\mu\text{g}/0.1$  ml intrastromally, noting a faster reduction in corneal infiltrate size and complete resolution of ulcers with no adverse effects in 26 out of 30 cases (86.67%). Also, according to *Xinying You, et al.*, (16), when followed up for more than 90 days, 89% (41 of 46 eyes) showed improvement in UCVA and 11% were unchanged. These higher results of complete cure than this study explains that longer follow-up time is necessary for cases of fungal keratitis even with intrastromal injection.

Three antifungal drugs were used *in this study* according to in vitro sensitivity results. They included fluconazole 0.2% which was used in 83.3% ( $n=15$ ) of cases, amphotericin B 5-10  $\mu\text{g}/0.1$  ml used in 11.1% ( $n=2$ ) of cases and voriconazole 50  $\mu\text{g}/0.1$  ml in 5.56% ( $n=1$ ) of cases. However, *Sharma N, et al.*, 2013 (19) who used one agent only that was voriconazole 50  $\mu\text{g}/0.1$  ml intrastromally in comparison to topical voriconazole, concluded that intrastromal injection didn't offer any beneficial effect over topical therapy. This explains that depending on in-vitro sensitivity results may offer better way of deciding the more effective agents in intrastromal injection of antifungal drugs than using only one agent in managing all cases of fungal keratitis with different species and accordingly, different patterns of response to antifungal drugs.

*In this study*, six out of 18 cases yield *Fusarium* species, all of which were sensitive to fluconazole 0.2% according to in vitro sensitivity test. One case showed complete cure after single intrastromal injection in comparison to 5 cases that only showed incomplete cure; two of which showed decrease in ulcer size by more than 80% (88% and 89.5%), one showed regression better than 60% (66.3%) of ulcer size, and the remaining 2 cases showed regression less than 40% (9.4% and 28.5%). In other words, 3 cases of *Fusarium* keratitis

showed great response, one case with moderate response and two cases with minimal response to intrastromal injection of fluconazole 0.2%. This agrees with *Kalaiselvi G, et al.*, (20) who used voriconazole 50 µg/0.1 ml in 25 patients, where *Fusarium* species was responsible for 6 out of 7 of the failed cases, concluding that *Fusarium* keratitis showed suboptimal response to intrastromal injection of Voriconazole 50 µg/0.1 ml. Also, this agrees with *Nada, et al.*, (21) who showed failure of treatment by combination of Amphotericin B 0.02 mg/ml and topical fluconazole in 7 cases of *Fusarium* keratitis.

The following complications of this technique were found in this study in comparison to other studies as follows:

- One case (5.56%) with *Aspergillus niger* showed a small 0.5 mm central perforation 3 days after second intrastromal injection with fluconazole 0.2%, that was treated with tissue adhesive (Histoacryl glue) to seal the perforation. This agrees with *Yalaka Jayapal Reddy, et al.*, (18) who showed 2 cases (10%) experienced perforated ulcer after 2 weeks of treatment with intrastromal injection of voriconazole 50 µg/0.1 ml. Those cases underwent Keratoplasty.
- Two cases were complicated by corneal thinning (descemetocoele) after intrastromal injection. These cases showed deep infiltrate more than two-thirds of corneal thickness. This agrees with *Xinying You, et al.*, (16) who reported one case of corneal thinning with vascularization after lamellar keratectomy followed by intrastromal injection of fluconazole 0.2%.

## 5. CONCLUSION

Advanced cases of fungal keratitis show good response to intrastromal injection of antifungal drugs when combined with the traditional topical route. Earlier intervention before occurrence of corneal thinning shows even better results with less incidence of possible complications.

### **CONSENT**

A written informed consent was obtained from all patients participated in the study after explaining the whole procedure and possible complications. A copy of the written consent is available for review by the editorial board members of this journal.

### **ETHICAL APPROVAL**

All authors, hereby, declare that approval was obtained from the Medical Research Ethics Committee of the Scientific Research, Faculty of Medicine, Assiut University that adhered to the tenets of the Declaration of Helsinki.

## REFERENCES

1. UPADHYAY MP, KARMACHARYA PC, KOIRALA S, TULADHAR NR, BRYAN LE, SMOLIN G. EPIDEMIOLOGIC CHARACTERISTICS, PREDISPOSING FACTORS, AND ETIOLOGIC DIAGNOSIS OF CORNEAL ULCERATION IN NEPAL. *AM J OPHTHALMOL*. 1991 JAN 15. 111(1):92-9.
2. GHARAMAH AA, MOHARRAM AM, ISMAIL MA, ALHUSSAINI AK. BACTERIAL AND FUNGAL KERATITIS IN UPPER EGYPT: IN VITRO SCREENING OF ENZYMES, TOXINS AND ANTIFUNGAL ACTIVITY. *INDIAN JOURNAL OF OPHTHALMOLOGY* . FEBRUARY 2014; 62(2):196-203. DOI: 10.4103/0301-4738.116463.
3. SRINIVASAN M. FUNGAL KERATITIS. *CURR OPIN OPHTHALMOL*. 2004 AUG. 15(4):321-7.
4. SPIERER O, DUGAR J, MILLER D, O'BRIEN TP. COMPARATIVE ANTIFUNGAL SUSCEPTIBILITY ANALYSIS OF *CANDIDA ALBICANS* VERSUS NON-*CANDIDA ALBICANS* *CANDIDA* CORNEAL ISOLATES. *CORNEA*. 2015;34(5):576-579.
5. JURKUNAS U; BEHLAU I; COLBY K. FUNGAL KERATITIS: CHANGING PATHOGENS AND RISK FACTORS. *CORNEA*. 2009; 28(6):638-43 (ISSN: 1536-4798).
6. MA SK; SO K; CHUNG PH; TSANG HF; CHUANG SK. A MULTI-COUNTRY OUTBREAK OF FUNGAL KERATITIS ASSOCIATED WITH A BRAND OF CONTACT LENS SOLUTION: THE HONG KONG EXPERIENCE. *INT J INFECT DIS*. 2009; 13(4):443-8 (ISSN: 1878-3511).
7. DALMON C, PORCO TC, LIETMAN TM, PRANJA NV, PRANJA L, DAS MR, ET AL. THE CLINICAL DIFFERENTIATION OF BACTERIAL AND FUNGAL KERATITIS: A PHOTOGRAPHIC SURVEY. *INVEST OPHTHALMOL VIS SCI*. 2012;53(4):1787-91. PUBLISHED 2012 APR 2. DOI:10.1167/IOVS.11-8478.
8. MOHAMMAD M. KHATER, NEHAL S. SHEHAB, AND ANWAR S. EL-BADRY. "COMPARISON OF MYCOTIC KERATITIS WITH NONMYCOTIC KERATITIS: AN EPIDEMIOLOGICAL STUDY," *JOURNAL OF OPHTHALMOLOGY*, VOL. 2014, ARTICLE ID 254302, 7 PAGES, 2014. [HTTPS://DOI.ORG/10.1155/2014/254302](https://doi.org/10.1155/2014/254302).
9. ANUTARAPONGPAN O, O'BRIEN TP. (2014) UPDATE ON MANAGEMENT OF FUNGAL KERATITIS. *CLIN MICROBIAL* 3:168. DOI: 10.4172/2327-5073.1000168.
10. BUNYA VY; HAMMERSMITH KM; RAPUANO CJ; AYRES BD; COHEN EJ. TOPICAL AND ORAL VORICONAZOLE IN THE TREATMENT OF FUNGAL KERATITIS. *AM J OPHTHALMOL*. 2007; 143(1):151-3 (ISSN: 0002-9394).
11. SHI W; LI S; LIU M; JIN H; XIE L. ANTIFUNGAL CHEMOTHERAPY FOR FUNGAL KERATITIS GUIDED BY IN VIVO CONFOCAL MICROSCOPY. *GRAEFES ARCH CLIN EXP OPHTHALMOL*. 2008; 246(4):581-6 (ISSN: 0721-832X).
12. ABDEL-RHAMAN MS, SOLIMAN W, HABIB F, FATHALLA D. A NEW LONG-ACTING LIPOSOMAL TOPICAL ANTIFUNGAL FORMULA: HUMAN CLINICAL STUDY. *CORNEA*. 2012 FEB;31(2):126-9. DOI: 10.1097/ICO.0B013E318221CF12.
13. WANG JY, WANG DQ, QI XL, CHENG J, XIE LX. MODIFIED ULCER DEBRIDEMENT IN THE TREATMENT OF THE SUPERFICIAL FUNGAL INFECTION OF THE CORNEA. *INT J OPHTHALMOL*. 2018;11(2):223-229. PUBLISHED 2018 FEB 18. DOI:10.18240/IJO.2018.02.07.

14. NIZEYIMANA, H., ZHOU, D., LIU, X., PAN, X., LIU, C., LU, C., & HAO, J. (2017). CLINICAL EFFICACY OF CONJUNCTIVAL FLAP SURGERY IN THE TREATMENT OF REFRACTORY FUNGAL KERATITIS. *EXPERIMENTAL AND THERAPEUTIC MEDICINE*, 14, 1109-1113. [HTTPS://DOI.ORG/10.3892/ETM.2017.4605](https://doi.org/10.3892/ETM.2017.4605).

15. NIKI M, EGUCHI H, HAYASHI Y, MIYAMOTO T, HOTTA F, MITAMURA Y. INEFFECTIVENESS OF INTRASTROMAL VORICONAZOLE FOR FILAMENTOUS FUNGAL KERATITIS. *CLINOPHTHALMOL*. 2014; 8:1075-9. PUBLISHED 2014 JUN 5. DOI:10.2147/OPHTH.S63516.

16. XINYING YOU, JUN LI, SUXIA LI, AND WEIYUN SHI. EFFECTS OF LAMELLAR KERATECTOMY AND INTRASTROMAL INJECTION OF 0.2% FLUCONAZOLE ON FUNGAL KERATITIS. *JOURNAL OF OPHTHALMOLOGY*, VOL. 2015, ARTICLE ID 656027, 10 PAGES, 2015. [HTTPS://DOI.ORG/10.1155/2015/656027](https://doi.org/10.1155/2015/656027).

17. PAUK-GULIC M, GABRIC N, BIŠCEVIC A, PAŠALIC A, DEKARIS I. SUCCESSFUL TREATMENT OF POSTKERATOPLASTY FUNGAL KERATITIS WITH TOPICAL AND INTRASTROMAL VORICONAZOLE. *J CLIN EXP OPHTHALMOL* (2015) 6:393. DOI: 10.4172/2155-9570.1000393.

18. YALAKA JAYAPAL, GAUTHAM REDDY, RAMAPATHY. PROSPECTIVE STUDY OF EFFECTIVENESS OF INTRASTROMAL VORICONAZOLE INJECTIONS IN THE MANAGEMENT OF DEEP NON-HEALING FUNGAL CORNEAL ULCERS AS AN ADJUNCTIVE THERAPY. *JOURNAL OF EVIDENCE BASED MEDICINE AND HEALTHCARE*, VOLUME 2, NUMBER 34, 2015, PP. 5133-5133(1).

19. SHARMA N, CHACKO J, VELPANDIAN T, TITIYAL JS, SINHA R, SATPATHY G, ET-AL. COMPARATIVE EVALUATION OF TOPICAL VERSUS INTRASTROMAL VORICONAZOLE AS AN ADJUNCT TO NATAMYCIN IN RECALCITRANT FUNGAL KERATITIS. *OPHTHALMOLOGY* VOLUME 120, ISSUE 4, APRIL 2013, PAGES 677-681.

20. KALAISELVI G, NARAYANA S, KRISHNAN T, SENGUPTA S. INTRASTROMAL VORICONAZOLE FOR DEEP RECALCITRANT FUNGAL KERATITIS: A CASE SERIES. *BR J OPHTHALMOL*. 2015 FEB;99(2):195-8. DOI: 10.1136/BJOPHTHALMOL-2014-305412.

21. NADA WM, AL ASWAD MA, EL-HAIG WM. COMBINED INTRASTROMAL INJECTION OF AMPHOTERICIN B AND TOPICAL FLUCONAZOLE IN THE TREATMENT OF RESISTANT CASES OF KERATOMYCOSIS: A RETROSPECTIVE STUDY. *CLIN OPHTHALMOL*. 2017; 11:871-874. PUBLISHED 2017 MAY 5. DOI:10.2147/OPHTH.S135112.