

Original Research Article

Effects of Ranitidine (Zantac) Drug on the hormonal level, sperm head abnormality and histo-architecture of the testis of albino male mice.

Abstract

The purposes of this study are to determine the effect of Zantac (Ranitidine) drug on sexual hormones (Testosterone and Prolactin), sperm head abnormality, and histopathological activity on albino male mice testes.

Two doses of the drug were used: 1000 and 2000mg/kg , in addition to a negative control group. Each group included four mice and the drug administrated orally as (0.1 ml) per day for 14 days, and then the mice were sacrificed on the day 15 for laboratory assessment.

The result showed that the drug cause increase the percentage of sperm head abnormality which reaches to (48.3%) and (22.8%) for 2000mg/kg and 1000mg/kg respectively in comparison to control group (11.1%). The male sex hormones also affected by the drug and the level of testosterone hormone decrease to (1.07ng/ml) in 2000mg/kg and (3.42ng/ml) in 1000mg/kg, while the level of hormone in control group is (14.07ng/ml). The prolactin hormone show increase in the level at dose 2000mg/kg it's (115ng/ml) and in dose 1000mg/kg the level its (43ng/ml) these value very high compared with control group (36ng/ml) due to the effect of the drug on the hormone. The histopathological examination shows damage in the seminal duct and changes in the wall of the seminiferous tube also the spermatogenesis well be affected by the drug in which is stop and some of seminal duct show no appearance of spermatogenesis and also cause depletion to the wall of the seminal duct.

Keywords: zantac, sperm head abnormality, testosterone, prolactin, albino mice.

Introduction

A drug is any substance (other than food that provides nutritional support) that when inhaled, injected, smoked, consumed absorbed via a patch on the skin or dissolved under the tongue causes a temporary physiological (and often psychological) change in the body [1].

In pharmacology, a pharmaceutical drug, also called medication or medicine, is a chemical substance used to cure, prevent or to promote well-being [2].

Ranitidine is a member of the class of histamine H₂-receptor antagonists with antacid activity. Ranitidine is a competitive and reversible inhibitor of the action of histamine, released by enterochromaffin-like (ECL) cells, at the histamine H₂-receptors on parietal cells in the stomach, thereby inhibiting the normal and meal-stimulated secretion of stomach acid [3].

It is commonly used in the treatment of peptic ulcer disease, gastroesophageal reflux disease and Zollinger–Ellison syndrome [4].

The reproductive system is considered to be particularly vulnerable to the effects of drugs. Hypothalamic neurotransmitters are sensitive to drugs that alter their synthesis, release, or action; disruption of these pathways changes the levels or patterns of secretion of the pituitary gonadotropins. Drugs also exert a direct action on the gonadal functions of androgen production and spermatogenesis. Drugs that decrease testosterone levels produce a multitude of effects on male reproduction. Neuropharmacologic agents that either inhibit central nervous system (CNS) activities (e.g., analgesics, anesthetics, sedatives, tranquilizers) or stimulate CNS activities (e.g., antidepressants, stimulants, hallucinogens) modify the hypothalamic-pituitary control of the gonadotropins and prolactin. The changes in luteinizing hormone, follicle-stimulating hormone, and prolactin result in changes in libido, erectile dysfunction, inability to ejaculate, testicular swelling and gynecomastia. Narcotic drugs exert their primary effect on the hypothalamic-pituitary axis and their secondary effects on the gonads and sex accessory organs. Narcotics decrease gonadotropin secretion and stimulate prolactin secretion, both of which are inhibitory to male sexual function [5].

Materials and Methods

Laboratory Animals

Albino Swiss male mice (*Mus musculus*) were the laboratory animals. They supplied by the Biotechnology Research Centre (Al-Nahrain University). Their age at the start of experiments was 8-10 weeks, and their weight was 23-27 gram. They divided into groups, and each group was kept in a separate plastic cage (details of these groups are given in the section of experimental design). The animals maintained at a temperature of 23 – 25°C, relative humidity range between 30-50% and they had free excess to food (standard pellets) and water (*ad libitum*).

Experimental Design

Twelve male mice are divided into three groups (n=4 each), the control group received normal saline while the experimental group received Ranitidine. All animals were orally treated once a day for 14 days.

Assessment of testosterone Serum Level

The kit was supplied from the local market which was synthesized by (Monobind Inc. Lake forest CA 92630 , USA. Accu Bind). Before proceeding with the assay, all reagents, serum references, and control were prepared in room temperature (20-27 °C). microplates wells was format and pipette 10µL serum reference, control or specimen into the microplates well, followed by adding (50ml) of the working Testosterone Enzyme Reagent and swirled the microplate gently for 20-30 seconds to mix then 0.050 ml of Testosterone Biotin Reagent was added to all wells followed by swirling the microplate gently for 20-30 seconds to max. After that, cover and incubate the microplate for 60 minutes at room temperature and discard the contents of the microplate and added 350ul decant (tap and blot) or aspirate, Repeated two additional times for a total of three washes. Later on, 0.100 ml of working substrate solution was added to all wells and incubated at room temperature for (15) minutes. 0.050ml of stop solution was added to each well. Finally, the absorbance was detected at 450nm.

Assessment of prolactin Serum Level

Serum level of Prolactin hormone is estimated using Prolactin hormone **commercial** kit (PRL) Test System (Monobind Inc. Lake forest CA 92630, USA. Accu Bind). The microplate wells **were formatted** for each serum reference, control and patient specimen and stored at 2-8°C. (0.025 ml) of the appropriate serum reference, control or specimen added to the microplate well, then, 0.100 ml of PRL-Enzyme Reagent solution was added to all wells and swirled gently for 20-30 seconds and incubated 60 minutes at room temperature. About 350ul of wash buffer added for washing, after that, 0.100 ml of working substrate solution added to all wells and incubated at room temperature for fifteen (15) minutes. Finally, 0.050ml of stop solution was added to each well and gently mixed for 15-20 seconds and read the absorbance in each well at 450nm.

Sperm-Head Abnormality Assay

Sperm Head Abnormality (SHA) is detected as described by [6], with some modification. After animal scarification by cervical dislocation and dissected, caput and cauda epididymis removed and placed in a Petridish containing 1ml of physiological normal saline, then minced and teased carefully to release the spermatozoa. After gentle pipetting a drop of 1% Eosin solution (10:1) is added to the suspension (2-3) drop on **a clean** slide and air dried for 30 min. The percentage of head abnormality is detected under light microscopy using 100X objective.

Preparation and examination of histological sections

The left testis and epididymis (caput and cauda) of each mouse is prepared for histopathological study as described by [7]. Samples were fixed in 10% formalin for 24h, followed by dehydration with a gradual series of alcohol (30-100%) for (5) min each. Then the samples cleared in two changes of xylene before embedded in paraffin wax for sectioning. Cross sections of (5) μ m thickness are prepared and stained with hematoxylin (Harison) and eosin according to **the standard** method[8]. **Histopathological** changes are performed under **a light** microscope as compared **to the control** group.

Statistical Analysis

The statistical analysis is performed using Minitab 16 (Minitab Ltd, Coventry, UK). Differences among groups are determined by Student t-test. Data are expressed as mean and standard error and differences were considered significant at ($p \leq 0.05$).

Results and Discussion

Sperm Head Abnormality (SHA)

Different sperm-head abnormalities were observed as a result of a treatment with the different doses of the Zantac drug, which was associated with a significant increase in sperm-head abnormalities in a dose dependent manner to reach 48.3% at 2000mg/kg and 22.8% at dose 1000mg/kg in comparison with negative control (11.1%), figure (1,2).

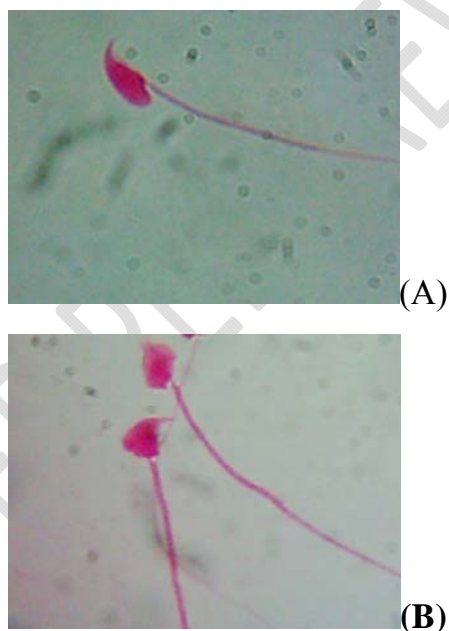


Figure 1: Sperm head morphological (a) Normal sperm form (b) Abnormal sperm head (100X).

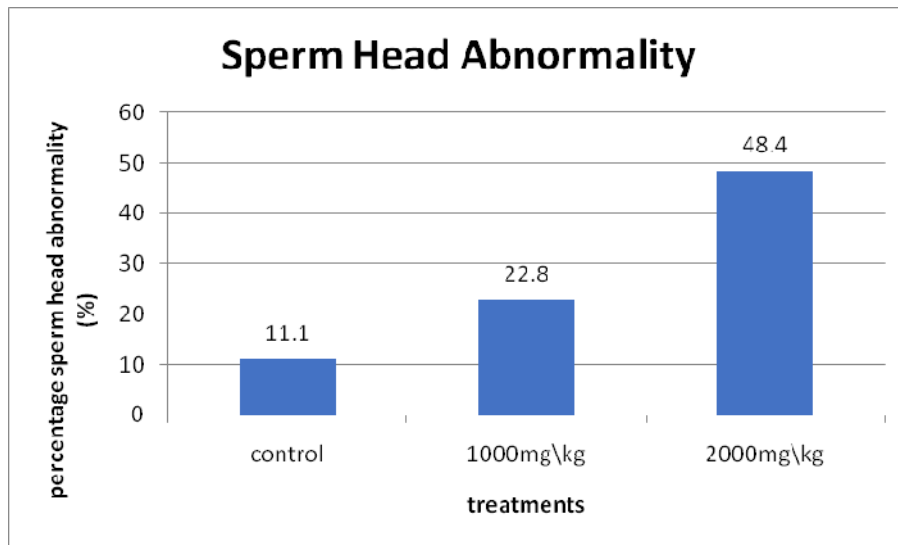


Figure 2: Figure represented sperm head abnormality depending on Zantac concentration.

Histopathological Changes of Testes

The testis tissue in the control negative mice showing normal seminiferous tubules, spermatids, and spermatogenic cells at different stages of development figure (3). The destructive changes appear more clearly that leads to absence of spermatogenesis with thin of the wall of the seminiferous tube of the testes in first treated dose (2000mg/kg) figure (4). The testes characterize by some seminal duct characterizes by the presence of complete spermatogenesis while some of them show no appearance spermatogenesis do to by generative changes which appear epithelial cells in addition to depletion of the wall of seminal duct for the group treated with (1000mg/kg) of drug figure (5).

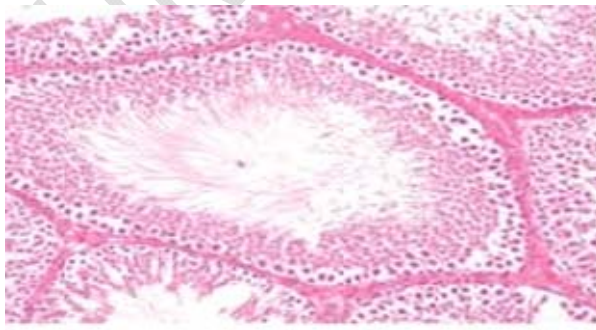


Figure 3: Section from testes of control mice.

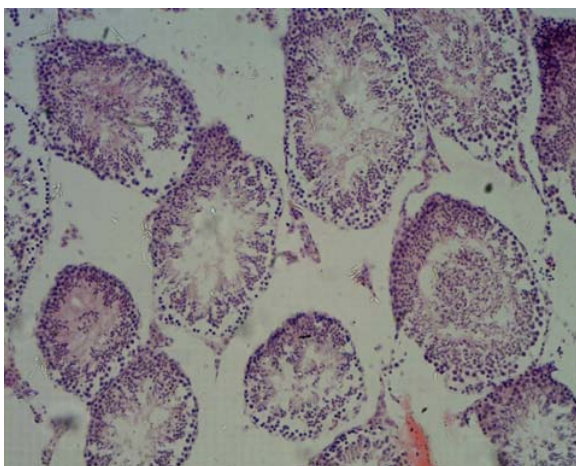


Figure 4: Section of testes tissue of first group treated with (2000mg/kg) of Zantac.

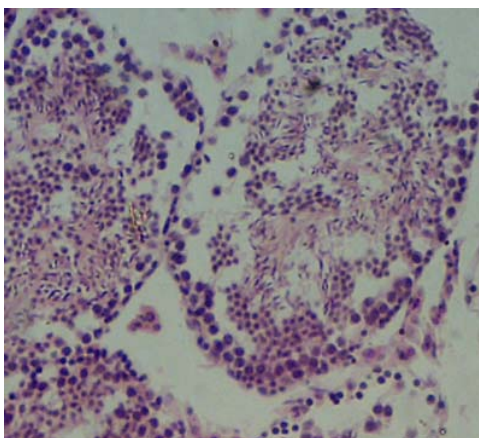


Figure 5: section of testes tissue in second group treated with (1000mg/kg) of Zantac.

Level of Testosterone

The level of male hormone (Testosterone) directly **effects** by Zantac drug. The high concentration of drug decreased the testosterone level to (1.07ng/ml) in compared with control group (14.07ng/ml) and the second concentration also affected and decrease hormone level (3.42ng/ml) but lower than high dose **respectively show in figure (6).**

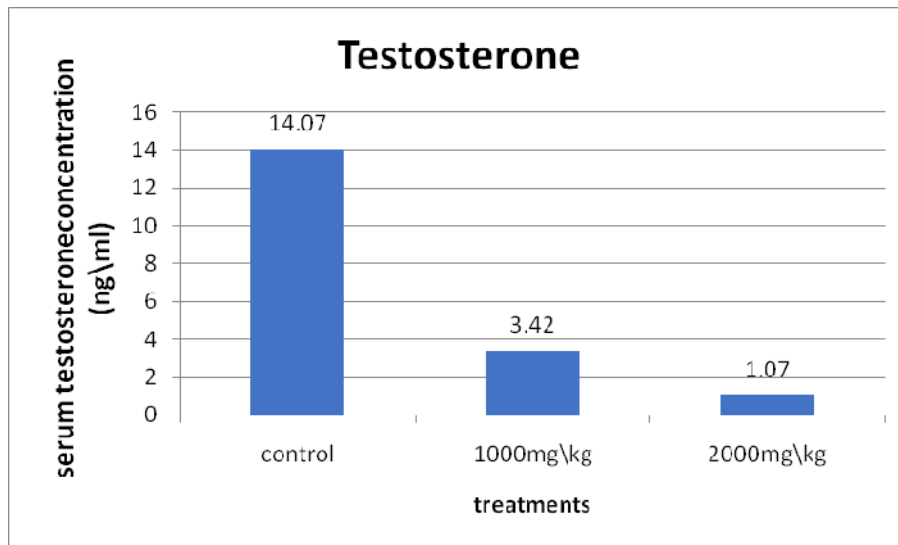


Figure 6: Figure representation the concentration of testosterone in Zantac treated albino male mice.

Level of Prolactin

The level of prolactin hormone also affected by Zantac drug. In the normal state, the prolactin hormone in the male should be at a low level. The level hormone in control group is (36ng/ml) while the level in the second group that treated with the drug (2000mg/kg) is increased to (115ng/ml) and another concentration also increase the hormone level (43ng/ml). The effect of high concentration will be more than the lower one shown in figure (7).

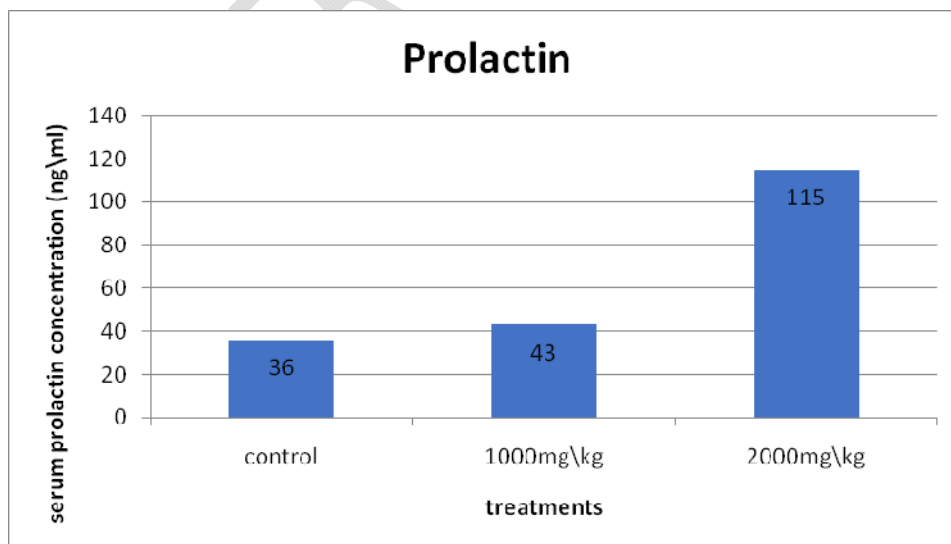


Fig (7): figure representation the concentration of prolactin in Zantac treated albino male mice.

Discussion

A number of chemicals including various environmental toxicants, **ecobacteria**, and even clinically useful drugs can cause cellular damages in different organs of the body through metabolic activation to highly reactive substances such as free radicals [9].

This study investigates Zantac induced toxicity in testis mice; study results have been shown that **Zantac is** capable of affecting seminiferous epithelium and altering **the spermatogenesis** process. The results have been indicated that Zantac induced **a significant** increase in the head abnormality associated with severe histopathological changes[10].

The presence of slaughter germinal cells and their occurrence in the epididymis and seminiferous tubule luminal are potential due to the loss of contact as consequences of disruption of cellular junctions between cells[11]. Spermatogonia are affected by the treatment by which some seminiferous tubules contained spermatogonia but don't complete and **at a low** level. Studies have been reported that spermatogonia seem to be the most resistant spermatogenic cells to toxicity, however, chronic exposure to **the chemotherapeutic** drug [12].

The successful and complete male germ cell development is depended on the balanced endocrine of hypothalamus, pituitary and the testis. **A gonadotropin-releasing** hormone secreted by the hypothalamus elicits the release of gonadotropins hormones from the pituitary gland [13]. FSH binds with receptors in the Sertoli cells and stimulates spermatogenesis. LH stimulates the production of testosterone in Leydig cells, which in turn may act on Sertoli cells and stimulates spermatogenesis [14].

The prolactin responsive mechanisms constitute the biological substrates for the pituitary-hypothalamo-gonadal feedback system in the male mammals, which relies on the gonadal steroids, testosterone and estradiol for long-loop, and prolactin for short-loop feedback mechanisms. These mechanisms would operate to contain the adverse effects of reproductive stress and ensure that serum levels of prolactin remain within the physiological range, because even mild-to-moderate hyperprolactinemia, if allowed to become chronic, affects the quality of mature spermatozoa and their fertilizing potential[15]. Hyperprolactinemia also affects reproductive behavior in spite of normal testosterone levels. Importantly, whereas the effects of acute hyperprolactinemia appear to be mediated via

testosterone inhibition, those due to moderate hyperprolactinemia would be a consequence of FSH deficits [16].

Conclusion:

Zantac (Ranitidine) like any others synthetic drugs which have a side effect, and the results of this study found that treatment of mice with zantac negatively effect on the frequency of sperm head abnormality and the level of male sex hormones

References

1. Amit, V., Bangia, A., Kamath, N., and Mohan, V. (2011). "Ranitidine-induced thrombocytopenia: Arare drug reaction". Indian J Pharmacol., 43 (1): 76–7.
2. Atanasov, A.G., Waltenberger, B., Pferschy-Wenzig E.M., Linder, T., Wawrosch, C., Uhrin, P., Temml, V., Wang, L., Schwaiger, S., Heiss, E.H., Rollinger, J.M., Schuster, D., Breuss, J.M., Bochkov, V., Mihovilovic, M.D., Kopp, B., Bauer, R., Dirsch, V.M. and Stuppner, H. (2015). Discovery and resupply of pharmacologically active plant-derived natural products., Biotechnol Adv.,33 (8): 1582–614.
3. Fedorowicz, Z., and Zuuren, E. J., (2012). "Histamine H2-receptor antagonists for urticaria". The Cochrane Database of Systematic Reviews. 3: CD008596.
4. Mallow, S., Rebuck, J.A., Osler, T., Ahern, J., Healey, M.A., Rogers F.B. (2004). "Do proton pump inhibitors increase the incidence of nosocomial pneumonia and related infectious complications when compared with histamine-2 receptor antagonists in critically ill trauma patients?". Curr Surg. 61 (5): 452–458.
5. Tuck, S.P., Francis, R.M. (2009). Testosterone, bone and osteoporosis Frontiers of Hormone Research.Front Home Research,37:123-132
6. Wyrobek, A. J. and Bruce, W. R. (1975). Chemical induction of sperm Abnormalities in mice. Proc. Natl. Acad. Sci., 72: 4425-4429.
7. Alwachi, S. N. and Husain, D. K. (2014). Research article Tamsulosin hydrochloride (flomax) effects on fertility of albino male mice. International Journal of Recent Scientific Research. 5, 2: 326-331.

8. Alwachi, S. N. and Husain, D. K. (2014). Research article Tamsulosin hydrochloride (flomax) effects on fertility of albino male mice. *International Journal of Recent Scientific Research*. 5, 2: 326-331
9. Lemike, T. L., Williams, D. H., and Foye, W. O. (2002). Principles of medicinal chemistry. 6th edition
10. Niran A. Ibraheem, Ruqaya M. Al-Ezzy, Maysaa CH. Al-Yas and Ebtehal H. Al-Naimy (2009). The effect of lactobacillus acidophilus concentrated filtrate on sperm head abnormality in albino male mice. *Journal of Al-Nahrain University Science*, 12 (4) :151-155
11. Niran A. Ibrahim, Hanady S. Al-Shmgani and Ruqaya M. I. Al-ezzy (2017). Cytarabine Induced Reproductive Histopathological Changes in Albino Male Mice. *Journal of Biotechnology Research Center*, 11 (1):6-12.
12. Howell, S. J. and Shalet, S. M. (2001). Testicular function following chemotherapy. *European society of human reproduction and embryology. Human Reproduction Update*, 7(4): 363–369,
13. Lucas, B.K., Ormandy, C.J., Binart, N., Bridges, R.S., and Kelly, P.A. (1998). Null mutation of the prolactin receptor gene produces a defect in maternal behavior. *Endocrinology*. 139(10):4102-2107.
14. Al-Hadidyai, A.A.A. (2003). Estimation of testosterone and some biochemical parameters in infertile women's serum. Thesis supplement to Microbiology Department, Medicinal College, Mosul.
15. Bassil, N., Alkaade, S., and Morley, J.E. (2009). The benefits and risks of testosterone replacement therapy. *Indian J Urol*. 30(1): 2–7.
16. Aleem, M., Choudhari, J., Padwal, V., Balasinor, N., Parte, P., and Gill-Sharma M.K. (2005). Hyperprolactinemia affects spermiogenesis in adult male rats. *J Endocrinol Invest*. 28(1):39-48.