

Original Research Article

Efficacy of Combined Root Extract of *Curcuma longa* and Leaf Extract of *Moringa oleifera* in the Prevention of Peptic Ulcer in Albino Rats

Comment [h1]: Crude extract?

ABSTRACT

Aim: This study is aimed at investigating the prophylactic efficacy of combined root extract of *Curcuma longa* and *Moringa oleifera* leaf extract against indomethacin-induced ulcer in albino rats.

Comment [h2]: Type of extract

Place and Duration of Study: This research was carried out in Ibadan Nigeria between November 2017 and February, 2018.

Methods: Fifty (50) healthy male albino rats with body weights between 150 and 200 g were used for this study. They were randomly divided into ten groups of five rats each. Group I was exposed to omeprazole for seven days, group II was exposed to *Moringa oleifera* leaf solution for seven days, group III was exposed to *Curcuma longa* solution for seven days, group IV was exposed to *Curcuma longa* + *Moringa oleifera* leaf solution for seven days and group V was exposed to distilled water for seven days. This group served as the control group. Groups VI, VII, VIII, IX and X were treated similarly as groups I, II, III, IV and V respectively but were treated for fourteen days. At the end of the administration, the animals were deprived of food for 18 hours and 50 mg/kg of indomethacin was administered orally (p.o) to the rats. After 8 hours of indomethacin administration, the animals were sacrificed by chloroform anesthesia and the stomach removed and opened along the greater curvature, rinsed with copious volume of normal saline and pinned on a board.

Comment [h3]: Group I was administered/given omeprazole (dose)..... The extract dose?

Comment [h4]: fasted

Comment [h5]: be consistent, use rats or animals

Comment [h6]: why?

Results: Animals treated with combined extracts of *Curcuma longa* + *Moringa oleifera* leaf showed significantly increased ulcer inhibition (71.64%, 75.57%) when compared with those of *Curcuma longa* (44.10%, 46.53%) and *Moringa oleifera* leaf (53.43%, 57.58) respectively but showed no significant different when compared with that of omeprazole (72.60%, 74.29%), the reference drug after 7 and 14 days pre-treatment respectively.

Conclusion: The combined extract has a greater prophylactic efficacy against indomethacin-induced ulcer than individual extracts and gave similar result as omeprazole. The combine extract of *Curcuma longa* + *Moringa oleifera* leaf should be used in cases of ulceration instead of omeprazole which is produced from chemicals.

Comment [h7]: The combine extract.....could be used as a prophylaxis against peptic ulcer disease

Keywords: Combined extracts of *Curcuma longa* + *Moringa oleifera* leaf, indomethacin-induced ulcer, prophylactic efficacy, omeprazole

1. INTRODUCTION

Peptic Ulcer Disease (PUD) also known as peptic ulcer or stomach ulcer is a break in the lining of the stomach, first part of the small intestine, or occasionally the lower esophagus [1]. Peptic ulcer disease comprises

heterogeneous disorders, which manifest as a break in the lining of the gastrointestinal mucosa bathed by acid and pepsin. Based on site of attack, peptic ulcer may be classified as oesophageal, duodenal, or gastric. Peptic ulcer disease (PUD) is one of the most common human ailments, affecting approximately 50 % of

Comment [h8]: delete

the world population. The life time for developing a peptic ulcer is approximately 10 % [2]. In western countries, the percentage of people with *Helicobacter pylori* infections roughly matches age (i.e., 20 % at age 20, 30 % at age 30, 80 %

at age 80). Prevalence is higher in developing countries where it is estimated at about 70 % of the population, whereas developed countries show a maximum of 40 % ratio [3].

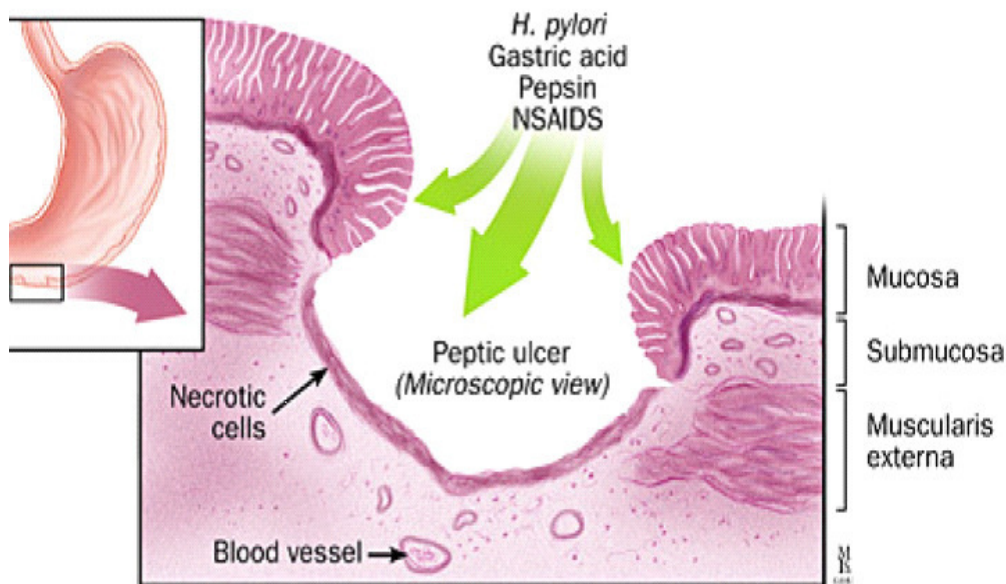


Figure 1: Pathogenesis of Peptic Ulcer [3]

It is generally recognized that peptic ulcer is caused by a lack of equilibrium between the gastric aggressive factors and the mucosal defensive factors [4]. Although several orthodox pharmaceutical drugs have been employed in the management of peptic ulcers e.g. antacids, anti-cholinergic drugs, histamine H₂-receptor antagonists, antihistaminics and more recently, proton-pump inhibitors. Most of these drugs, however, produce several adverse reactions, like arrhythmias, impotence, gynecomastia and hematopoietic changes [5]. In recent years, there has been growing interest in alternative therapies especially from plant sources due to their perceived lower side effects, ease of accessibility and affordability [6].

Curcuma longa commonly referred to as turmeric is a rhizomatous herbaceous perennial plant of the ginger family, Zingiberaceae [7]. *Curcuma longa* has been used in traditional remedy for a wide range of ailments, including wound healing, urinary and gastrointestinal tract infections, and liver ailments [8]. Curcumin has

been defined as the most active component in *Curcuma longa* and has been shown to have considerable gastroprotective, anti-ulcerogenic and therapeutic effect in gastric ulcer disease [8]. It has been reported to heal peptic ulcer [9].

Moringa oleifera Lam. is the most widely cultivated species of the mono-generic family Moringaceae, which includes 13 species of trees and shrubs distributed in sub Himalayan ranges of India, Sri Lanka, North-eastern and South-western Africa, Madagascar and Arabia. Moringa is also native to parts of West Africa particularly Nigeria [10]. The whole *Moringa oleifera* plant is used in the treatment of psychosis, eye diseases, fever and as an aphrodisiac, the aqueous extracts of roots and barks were found to be effective in preventing implantation [11]. The Moringa tree is a multifunction plant. It has been cultivated in tropical regions all over the world for the following characteristics: high protein, vitamins, mineral and carbohydrate content of entire plants; high value of nutrition for both humans

Comment [h9]: antihistamines?

Comment [h10]: Use/purposes

and livestock; high oil content (42%) of the seed which is edible, and with medicinal uses; the coagulant of seeds could be used for wastewater treatment [10].

Different parts of the *Moringa oleifera* (Mo) tree have been established as being good sources of unique glucosinolates, flavonoids and phenolic acids [12, 13], carotenoids [14], tocopherols [15], polyunsaturated fatty acids (PUFAs) [16], highly bioavailable minerals [17], and folate [18]. Among glucosinolates, 4-O-(α -L-rhamnopyranosyloxy)-benzylglucosinolate (glucomoringin) is the most predominant in the stem, leaves, flowers, pods and seeds of *M. oleifera* [12]. Although in the roots, benzyl glucosinolate (glucotropaeolin) is the most prominent. The highest content of glucosinolate is found in the leaves and seeds. The enzymatic catabolism of glucosinolates by the endogenous plant enzyme myrosinase produces isothiocyanates, nitrites, and thiocarbamates that are known for strong hypotensive (blood pressure lowering) and spasmolytic (muscle relaxant) effects [19]. In the leaves, the amount of quercetin and kaempferol was found to be in the range of 0.07–1.26 and 0.05–0.67 %, respectively. The potent antioxidant activity of *Moringa* is attributed to the high concentration of these polyphenols. Medicinally, the antioxidant, wound healing, hypotensive, and diuretic effects of this plant have been reported [20, 21].

Previous studies have reported the antioxidant [22], anti-inflammatory [23] and pharmacological [12] properties of *M. oleifera*. Furthermore, Awodele *et al.*, [24] worked on the toxicological evaluation of the aqueous extract of *Moringa oleifera* Lam (Moringaceae). Oyedepo *et al.*, [25] evaluated the anti-hyperlipidemic effect of aqueous leaves extract of *Moringa oleifera*, while Choudhary *et al.*, [26] assessed the antiulcer potential of *Moringa oleifera* root bark extract in rats. *Moringa oleifera* leaf has been reported to be potent in the treatment of peptic ulcer [27]. Both *Curcuma longa* and *Moringa oleifera* leaf has been used independently to prevent peptic ulcer [28, 29]. This study is aimed at investigating the efficacy of the combination of both plants in the prevention of peptic ulcer.

2. METHODOLOGY

2.1. Chemicals

Omeprazole (Cipla) and indomethacin (Sun) were of analytical grade.

2.2. Plant Preparation

Moringa oleifera leaf was harvested from the Institute of Agricultural Research and Training, Ibadan and was identified by a botanist. The leaves were removed from the stem and washed thoroughly with running water to remove contaminants. They were dried at room temperature until they were completely dried. They were milled into powder and stored in a plastic container before use.

Turmeric root extract in the form of powder, was purchased from Foodco, Bodija, Ibadan. It was weighed accordingly and administered in aqueous solution.

2.3. Animal Treatment

Fifty (50) healthy male albino rats with body weights between 150 and 200 g were used for this study. They were purchased from 'Imrat animal house' of the University College Hospital, Ibadan and were housed in Educational Advancement Centre animal house.

They were allowed 14 days to acclimatize before the commencement of treatment. The animals were maintained on a standard pellet diet throughout the acclimatization and treatment period. They were randomly divided into ten groups of five rats each. Group I was exposed to omeprazole for seven days, group II was exposed to *Moringa oleifera* leaf solution for seven days, group III was exposed to *Curcuma longa* solution for seven days, group IV was exposed to *Curcuma longa* + *Moringa oleifera* leaf solution for seven days and group V was exposed to distilled water for seven days. This group served as the control group. Groups VI, VII, VIII, IX and X were treated similarly as groups I, II, III, IV and V respectively but were treated for fourteen days.

A 0.8 mg/ml solution of omeprazole was prepared daily and the animals in groups I and VI were allowed to drink *ad libitum*. A 0.8 g/ml solution of *Moringa oleifera* leaf was prepared daily and the animals in groups II and VII were allowed to drink *ad libitum*. This was done because people feed on *Moringa* without attention to dosage. A 0.8 g/ml solution of *Curcuma longa* was prepared daily and the animals in groups III and VIII were allowed to

Comment [h12]: Re-write clearly

Comment [h13]: The leaves were completely dried at room temperature, milled into powder and stored in a plastic container.

Comment [h14]: You bought the 'root extract' or powdered turmeric root?

Comment [h15]: Explain

Comment [h16]: Fifty (50).....weighing between 150 and 200g purchased from.....were sed for this study.

Comment [h17]: administered

Comment [h18]: how much was given

Comment [h19]: administered root extract (HOW MUCH WAS GIVEN?)

Comment [h20]: Technically you have two treatment groups, Group A treated for 7 days and Group B treated for 14 days

Comment [h11]: Drugs

drink *ad libitum*. This was done because people also feed on tumeric without attention to dosage. A 0.8 g/ml solution of *Curcuma longa* + *Moringa oleifera* (1:1) was prepared daily and the animals in groups IV and IX were allowed to drink *ad libitum* while groups V and X drank distilled water throughout the period of administration. All the animal treatments were carried out in accordance with the principles of laboratory animal care of the National Institute of Nutrition (NIN) guide for Laboratory Animal Welfare.

At the end of the administration, the animals were deprived of food for 18 hours and 50 mg/kg of indomethacin was administered orally (p.o) to the rats. After 8 hours of indomethacin administration, the animals were sacrificed by chloroform anesthesia and the stomach removed and opened along the greater curvature, rinsed with copious volume of normal saline and pinned on a board.

2.4. Parameters Measured

2.4.1. Ulcer Index

Ulcer index was measured. The ulcers scores were given based on their intensity as follows

Normal stomach.....	0.0
Red coloration.....	0.5
Spot ulcer.....	1.0
Hemorrhagic streak.....	1.5
Ulcers.....	2.0

Table 1: Effect of different Treatments on Indomethacin-Induced Ulcer with the Values of Gastric Ulcer Index and Percentage Ulcer Inhibition after 7days' Pre-treatment

Treatments	Ulcer Index (mm)	% Ulcer Inhibition
Control	60.83 ± 6.29 ^a	0.00 ^a
Omeprazole	16.67 ± 2.89 ^b	72.60 ^b
<i>Curcuma longa</i>	34.00 ± 3.61 ^c	44.10 ^c

Perforation..... 3.0

Measurement of gastric ulcerations was done by first dissecting the stomachs along their greater curvature and fixing on a board [30]. Examination was carried out macroscopically with a hand lens (x 2). The ulcer indices (UI) of the control and treated groups were calculated using the method of [31].

$$\text{Ulcer index (mm)} = \frac{\text{Number of ulcers (A) x Size of ulcers (B)}}{\text{Magnification power of the lens used (x 2)}}$$

2.5. Percentage Ulcer Inhibition

Percentage ulcer inhibition was calculated relative to control as follows:

$$\% \text{ Ulcer Inhibition (\% U.I.)} = \left(1 - \frac{U_t}{U_c}\right) \times 100$$

Where U_t and U_c represent the ulcer index of the treated and control groups respectively.

2.6. Statistical Analysis

Data were subjected to analysis using the Statistical Package for Social Sciences (SPSS), version 21.0. Results were presented as Mean ± Standard deviations. Student's t-test was used for comparison of the mean. Difference between means were considered to be significant at $p < 0.05$.

3. RESULT

Indomethacin induced gastric ulcer in 42 out of 50 (84.00 %) rats used in this study.

Comment [h21]: State the dosage and reason first. This was administered to the rats in group A and B for 7 and 14 days respectively.

Comment [h22]: fasted

Comment [h23]: ...for?

<i>Moringa oleifera</i>	28.33 ± 2.89 ^a	53.43 ^a
<i>Curcuma longa</i> + <i>Moringa oleifera</i>	17.25 ± 1.23 ^b	71.64 ^b

Results are presented as mean ± standard deviation where n=5. Values with different superscript along the same column are said to be significant at p<0.05.

Comment [h24]: delete

Table 2: Effect of Different Treatment on Indomethacin-Induced Ulcer with the Values of Gastric Ulcer Index and Percentage Ulcer Inhibition after 14 Days' Pre-treatment

Treatments	Ulcer Index (mm)	% Ulcer Inhibition
Control	64.83 ± 4.19 ^a	0.00 ^a
Omeprazole	16.67 ± 2.08 ^b	74.29 ^b
<i>Curcuma longa</i>	34.67 ± 5.03 ^c	46.53 ^c
<i>Moringa oleifera</i>	28.33 ± 2.89 ^c	57.58 ^d
<i>Curcuma longa</i> + <i>Moringa oleifera</i>	15.84 ± 2.06 ^c	75.57 ^b

Results are presented as mean ± standard deviation where n=5. Values with different superscript along the same column are said to be significant at p<0.05.

Comment [h25]: delete

4. DISCUSSION

Peptic ulcer is a common illness in internal medicine which affects a considerable number of people worldwide [32]. Although, many products are available for the treatment of gastric ulcers (e.g., antacids and antihistaminic), most of these drugs produce several adverse effects, such as arrhythmias, impotence, gynecomastia, and hematopoietic changes [33]. The extracts of many herbal plants have been shown to produce promising results for the treatment of gastric ulcers with fewer or negligible side effects [34]. Almost all parts of the *Moringa oleifera* plant have been reported to have medicinal values for the treatment of various ailments, such as gastrointestinal disorders, tumors, diabetes, hypertension, renal disorders, bacterial and fungal diseases, and fever [29, 35, 36]. *Curcuma longa* on the other hand has been used in traditional remedy for a

wide range of ailments, including wound healing, urinary and gastrointestinal tract infections, and liver ailments [8]. Curcumin has been defined as the most active component in *Curcuma longa* and has been shown to have considerable gastroprotective, anti-ulcerogenic and therapeutic effect in gastric ulcer disease [8]. It has been reported to heal peptic ulcer [9]. Airaodion *et al.* [28] has also reported its prophylactic efficacy against Indomethacin-Induced Ulcer in Male Wistar Rats. In lieu of this, this present study was performed to investigate the combined effect of *Moringa oleifera* and *Curcuma longa* in the prevention of indomethacin-induced peptic ulcer in albino rats.

Comment [h26]: delete

Comment [h27]: antihistamines?

Comment [h28]: Literature review

In this study, indomethacin produced a marked increase in gastric lesions and damaged the stomach mucosal layer of the experimental rats. Ulcer produced in this model was seen as black sores. The stomachs of rats in the control

(distilled water-treated) group showed higher inductions of gastric ulcers due to increased levels of gastric juice in the rat's stomachs. *Moringa oleifera* leaf used in this study exhibited anti-ulcerogenic effect against indomethacin-induced gastric ulcers with percentage ulcer inhibition that were significantly lower than those obtained for omeprazole, the reference anti-ulcer drug used (Tables 1 and 2). Prolonged use of indomethacin and other non-steroidal anti-inflammatory drugs are associated with gastrointestinal bleeding and ulceration. The ulcer formation can occur either by direct mucosal injury which involves the breaking of the mucosal barrier and exposure of the underlying tissue to the corrosive action of excess acid and pepsin or by a decrease in endogenous gastric prostaglandin production and release through COX-1 and COX-2 inhibition [37]. These naturally occurring prostaglandins are important for the production of gastric bicarbonate and mucous which are key components of the stomach protective barrier and in the maintenance of submucosal blood flow.

Most non-steroidal anti-inflammatory drugs including indomethacin, used in the control of inflammation have been reported to cause gastric erosions and abdominal ulcers after prolonged use. Reduction of the indomethacin-induced ulcers shown by *Moringa* could be attributed to the high flavonoid content and antioxidant potential of *Moringa oleifera* leaf. Several plants has been reported to be of medicinal value including healing and prevention of ulceration due to their flavonoid content and antioxidant potential [38, 39]. Phytochemical analyses of *Moringa* leaf showed that it is rich in flavonoids [12, 13], this could be the active constituent exerting the anti-ulcerogenic effect. Halliwell *et al.*, [40] proposed that the antioxidant and other protective effects of plant flavonoids could occur before absorption, within the gastrointestinal tract and could account for the ability of flavonoid-rich foods to protect against gastric and colon ulcers.

Similarly, there was a significant decrease in the measured gastric ulcer index in the stomach of omeprazole-treated animals when compared with the control and *Curcuma longa* treated animals. The aqueous crude extract of *Curcuma longa* exhibited anti-ulcerogenic effect against indomethacin-induced gastric ulcer as there was a percentage ulcer inhibition of 43.84% and

46.53% in the rats pre-treated for 7 and 14 days respectively when compared with the control groups (Tables 1 and 2). The gastroprotective effect exhibited by *Curcuma longa* crude root extract may be attributed to the presence of flavonoids and polyphenolic compounds which include curcumin and other curcuminoids [41].

Many studies have examined the anti-ulcerogenic activities of plants containing flavonoids [28, 29, 42, 43]. Plants containing flavonoids were found to be effective in preventing this kind of lesion mainly because of their anti-inflammatory activity and anti-oxidant properties. They protect the gastric mucosa against a variety of ulcerogenic agents and oxidation processes which are involved in the mechanisms of several gastric disorders, including ulcerogenesis in different mammalian species [28, 29, 42, 44]. *Curcuma longa* crude root extract has also been reported to exert its anti-ulcer activity by increasing the synthesis of endogenous prostaglandins, which in turn promote mucus secretion and enhance the mucosal barrier against the actions of various damaging agents [8].

Moringa oleifera crude leaf extract-treated rats showed significant protection (53.43%) against gastric ulceration caused by indomethacin compared to the ulcers produced in the control group after seven days' treatment ($p < 0.05$). Omeprazole treated rats showed significant protection (72.6%) against gastric ulceration caused by indomethacin administration compared to the ulcers produced in the control group after seven days' treatment ($p < 0.05$). Although, the protective effect of omeprazole and *Moringa* against indomethacin-induced ulcer were significant for both seven and fourteen days treatment respectively, the values of percentage Ulcer inhibition of omeprazole-treated animals (72.60 %, 74.29 %) were significantly higher than those of *Moringa*-treated animals (53.43%, 57.58 %) after seven and fourteen days respectively. This might be due to the fact that high percentage of *Moringa* active components did not dissolve in water used in the preparation. According to Verma *et al.*, [27], an ethanolic extract of *M. oleifera* leaf has been reported to have potential for the treatment of gastric lesions.

Similarly, a significant decrease was observed in the percentage ulcer inhibition of animals treated with aqueous crude root extract of *Curcuma longa* (46.53% and 43.84%) when compared

Comment [h32]: repetition

Comment [h29]: mucus

Comment [h30]: repetition

Comment [h31]: aqueous crude leaf extract of

Comment [h33]: delete

with those of omeprazole-treated animals (74.29% and 72.60%) after 7 and 14 days respectively. This might be attributed to poor solubility of curcumin in water as well as its poor bioavailability, whereas omeprazole is a standard ulcer drug in which its active ingredient is well extracted. Study by Ravindranath and Chandrasekhra [45] revealed that only a trace amount of curcumin was present in the stomach and intestine of the rats. In view of poor availability of curcumin, it is unlikely that substantial concentration of curcumin occur in the body after ingestion.

Animals treated with combined crude root extracts of *Curcuma longa* + *Moringa oleifera* crude leaf extract showed significantly increased ulcer inhibition (71.64%, 75.57%) when compared with those of *Curcuma longa* (44.10%, 46.53%) and *Moringa oleifera* leaf (53.43%, 57.58) respectively but showed no significant different when compared with that of omeprazole (72.60%, 74.29%), the reference drug after 7 and 14 days pre-treatment respectively. This could be that the active ingredients in both plants combined their anti-ulcerogenic effect in the prevention of indomethacin-induced ulcers. This implies that the combined extract has a greater prophylactic efficacy against indomethacin-induced ulcer than individual extracts. The mechanism of action of the combined extract of *Curcuma longa* + *Moringa oleifera* leaf is synergetic as the effect is greater than the effect of each of the extract but less than the sum of the effect of the two individual extracts. Since the combined extract of *Curcuma longa* + *Moringa oleifera* leaf gave similar result with those of omeprazole group (the standard drug used in the treatment of ulcer) at both 7 and 14 days respectively, and omeprazole being a drug produced from chemicals, the combine extract of *Curcuma longa* + *Moringa oleifera* leaf should be used in cases of ulceration instead of omeprazole. Although, the histopathology of animal organs were not determined in this study, the liver of animals treated with omeprazole especially for 14 days showed some black colouration This shows the level of toxicity of omeprazole. Toxicity of different drugs has been reported [46].

When seven and fourteen days' animals given similar treatment were compared at $p < 0.05$, there was no significant difference in the protection against gastric ulceration caused by

indomethacin induction. Therefore, further treatment with *Curcuma longa*, *Moringa oleifera* leaf, *Curcuma longa* + *Moringa oleifera* leaf and omeprazole respectively does not guarantee greater protection as far as the treatment is ongoing before ulcer induction.

5. CONCLUSION

The results of this study indicate that the combined crude root extract of *Curcuma longa* + *Moringa oleifera* crude leaf extract is a better way of preventing peptic ulcer than using the plants individually. Again, the study revealed that the combined extract of *Curcuma longa* + *Moringa oleifera* leaf produced similar result with omeprazole but with negligible side effect. Thus, the combined extract of *Curcuma longa* + *Moringa oleifera* leaf should be used in the prevention of peptic ulcer and possibly replace omeprazole in the treatment of ulcer.

REFERENCES

1. Najm WI. Peptic Ulcer Disease. *Primary Care*. 2011;38 (3):383-394.
2. Snowden FM. Emerging and reemerging diseases: Historical perspective. *Immunol Rev*. 2008;225(1):9-26.
3. Brown LM. *Helicobacter pylori*: Epidemiology and routes of transmission. *Epidemiol Rev*. 2000;22(2):283-297.
4. Rao CV, Sairam K, Goel RK. Experimental evaluation of *Boccapomonniereaon* rat gastric ulceration and secretion. *Indian Journal of Physiology and Pharmacology*. 2000;44(4):435-441.
5. Ariyoshi I, Toshiharu A, Sugimura F, Abe M, Matsuo Y, Honda T. Recurrence during maintenance therapy with histamine H2 receptors antagonist in cases of gastric ulcers. *Nikon University J Med*. 1986;28:69-74.
6. Ramesh SM. Plants as source of drugs. *Toxicol*. 2001;39(5):603-613.
7. Priyadarsini KI. The chemistry of curcumin: from extraction to therapeutic agent. *Molecules*. 2014;19(12):91-112.
8. Kim DC, Kim SH, Kim D, Kim MJ. *Curcuma longa* extract protects against gastric ulcers by blocking H₂ histamine receptors. *Biol Pharm Bull.*; 2005;28:2220-2224.
9. Tuorkey M, Karolin K. Anti-ulcer activity of curcumin on experimental gastric ulcer in rats and its effect on oxidative stress/antioxidant, IL-6 and enzyme

Comment [h36]: There was no significant difference between group A and B, thus prolonged pretreatment may not be required.

Comment [h37]: Is more effective in peptic ulcer prophylaxis and should be preferred over omeprazole.

Comment [h34]: this could be due to synergistic effect of...

Comment [h35]: you have not done this. Delete.

- activities. *Biomed Environ Sci.*; 2009;22:488–495.
10. Monica PH, Sharma B, Sarkar C, Singh C. Kinetics of drumstick leaves (*Moringa oleifera*) during convective drying. *African Journal of Plant Science.* 2010;4(10): 391-400.
 11. Patel RK, Manish MP, Nilesh RK, Kirit RV, Patel RK. In vitro hepatoprotective activity of *Moringa oleifera* Lam. Leave on isolated rat hepatocytes. *Int. j. ph. sci.* 2010;2(1):457-463.
 12. Amaglo NK, Bennett RN, Lo-Curto RB, Rosa EA, Lo TV, Giuffrid A, Lo CA, Crea F, Timpo GM. Profiling selected phytochemicals and nutrients in different tissues of the multipurpose tree *Moringa oleifera* Lam grown in Ghana. *Food Chemistry.* 2010;122:1047–1054.
 13. Coppin JP, Xu Y, Chen Q. Determination of flavonoids by LC/MS and anti-inflammatory activity in *Moringa oleifera*. *Journal Functional Foods.* 2013;5:1892–1899.
 14. Saini RK, Shetty NP, Giridhar P. Carotenoid content in vegetative and reproductive parts of commercially grown *Moringa oleifera* Lam. cultivars from India by LC–APCI–MS. *Eur Food Res Technol.* 2014;238:971–978.
 15. Saini RK, Shetty NP, Prakash M, Giridhar P. Effect of dehydration methods on retention of carotenoids, tocopherols, ascorbic acid and antioxidant activity in *Moringa oleifera* leaves and preparation of a RTE product. *J Food Sci Technol.* 2014;51:2176–2182
 16. Saini RK, Shetty NP, Giridhar P. GC-FID/MS analysis of fatty acids in Indian cultivars of *Moringa oleifera*: potential sources of PUFA. *J Am Oil Chem Soc.* 2014;91:1029–1034.
 17. Saini RK, Manoj P, Shetty NP. Dietary iron supplements and *Moringa oleifera* leaves influence the liver hepcidin messenger RNA expression and biochemical indices of iron status in rats. *Nutr Res.* 2014;34:630–638.
 18. Saini RK, Manoj P, Shetty NP. Relative bioavailability of folate from the traditional food plant *Moringa oleifera* L. as evaluated in a rat model. *J Food Sci Technol.* 2016; 53:511–520.
 19. Anwar F, Latif S., Ashraf M, Gilani AH. *Moringa oleifera*: a food plant with multiple medicinal uses. *Phytother Res PTR.* 2007;21:17–25.
 20. Faizi S, Siddiqui BS, Saleem R, Siddiqui S, Aftab K, Gilani AH. Fully acetylated carbamate and hypotensive thiocarbamate glycosides from *Moringa oleifera*. *Phytochemistry.* 1995;38(4):957-963.
 21. Guevara AP, Vargas C, Sakurai H, Fujiwara Y, Hashimoto K, Maoka T, Kozuka M, Ito Y, Tokuda H, Nishino H. An Antitumor Promoter from *Moringa oleifera*. *Mutation research.* 1999;440(2):181-188.
 22. Limon-Pacheco J, Gonsebatt ME. The role of antioxidants and antioxidant-related enzymes in protective responses to environmentally induced oxidative stress. *Mutat. Res.*, 2009; 674:137–147.
 23. Mahajan S, Mehta A. Curative effect of hydroalcoholic extract of leaves of *Moringa oleifera* lam. Against adjuvant induced established arthritis in rats. *Niger. J. Nat. Prod. Med.* 2009;13: 13–22.
 24. Awodele O, Oreagba IA, Odoma S, Silva JA, Osunkalu VO. Toxicological evaluation of the aqueous extract of *Moringa oleifera* Lam (Moringaceae). *J Ethnopharmacol.* 2012;139: 330-336.
 25. Oyedepo TA, Babarinde SO, Ajayeoba TA. Evaluation of Anti-hyperlipidemic effect of aqueous leaves extract of *Moringa oleifera* in alloxan induced diabetic rats. *International Journal of Biochemistry Research & Review.* 2003;3(3): 162-170.
 26. Choudhary MK, Bodakhe SH, Gupta SK. Assessment of the antiulcer potential of *Moringa oleifera* root-bark extract in rats. *J Acupunct Meridian Stud.* 2013;6(4):214-20.
 27. Verma VK, Singh N, Saxena P, Singh P. Anti-ulcer and antioxidant activity of *Moringa oleifera* (Lam) leaves against aspirin and ethanol induced gastric ulcers in rats. *Int Res J Pharmaceut.* 2012;2: 46-57.
 28. Airaodion AI, Obajimi OO, Ezebuiro CN, Ogbuagu U, Agunbiade AP, Oloruntoba AP, Akinmolayan JD, Adeniji AR, Airaodion EO. Prophylactic Efficacy of Aqueous Extract of *Curcuma longa* Leaf Against Indomethacin-Induced Ulcer. *International Journal of Research.* 2019;6(1):87-91.
 29. Airaodion AI, Olayeri IM, Ewa AO, Ogbuagu EO, Ogbuagu U, Akinmolayan JD, Agunbiade AP, Oloruntoba AP, Airaodion EO, Adeniji AR, Obajimi OO, Awosanya OO. Evaluation of *Moringa oleifera* Leaf Potential in the Prevention of Peptic Ulcer in Wistar Rats. *International Journal of Research.* 2019;6(2):579-584.

30. Parmar NS, Desai JK. A review of the current methodology for the evaluation of gastric and duodenal anti-ulcer agents. *Indian J Pharmacol.* 1993;25:120-135.
31. Ezike AC, Akah PA, Okoli CO, Ezeuchenne NA, Ezeugwu S. Carica papaya (paw-paw) unripe fruit may be beneficial in ulcer. *J. Med. Food.* 2009;12:1268-1273.
32. Oyagi A, Ogawa K, Kakino M, Hara H. Protective effects of a gastrointestinal agent containing Korean red ginseng on gastric ulcer models in mice. *BMC Complement Altern. Med.* 2010;10:45
33. Ariypshi I, Toshiharu A, Sugimura F, Abe M, Matsuo Y, Honda T. Recurrence during maintenance therapy with histamine H2 receptors antagonist in cases of gastric ulcers. *Nikon University J Med.* 1986;28: 69-74.
34. Pillai NR, Suganthan D, Seshari C, Santhakumari G. Antigastric ulcer activity. *Indian J Med Res.* 1978;68:169-175.
35. Morimistu Y, Hayashi K, Nakagama Y, Horio F, Uchida K, Osawa T. Antiplatelet and anticancer isothiocyanates in Japanese horseradish. *Wasabi Bio Factors.* 2000;13: 271-276.
36. Mehta J, Shukla A, Bukhariya V, Charde V. The magic remedy of *Moringa oleifera*: an overview. *Int J Biomed Adv Res.* 2011;22: 272-278.
37. Kaunitz JD, Akiba Y. Gastroduodenal mucosal defense: role of endogenous mediators. *Curr Opin Gastroenterol.* 2004; 20: 526-532.
38. Airaodion AI, Olatoyinbo PO, Ogbuagu U, Ogbuagu EO, Akinmolayan JD, Adekale OA, Awosanya OO, Agunbiade AP, Oloruntoba AP, Obajimi OO, Adeniji AR, Airaodion EO. Comparative Assessment of Phytochemical Content and Antioxidant Potential of *Azadirachta indica* and *Parquetina nigrescens* Leaves. *Asian Plant Research Journal*, 2019;2(3): 1-14.
39. Airaodion AI., Ibrahim AH, Ogbuagu U, Ogbuagu EO, Awosanya OO. Akinmolayan JD, Njoku OC, Obajimi OO, Adeniji AR, Adekale OA. Evaluation of Phytochemical Content and Antioxidant Potential of *Ocimum gratissimum* and *Telfairia occidentalis* Leaves. *Asian Journal of Research in Medical and Pharmaceutical Sciences*, 2019;7(1), 1-11. <https://doi.org/10.9734/ajrimps/2019/v7i130>
40. Halliwell B, Zhao K, Whiteman ML, Harford, WV, Barnett C, Lee E. (2000). Acute gastritis with hypochondria: Report of 35 cases with long term follow up. *Gut.* 47:467-472.
41. Abdulla MA, Ahmed KA, Bayaty FH, Masood Y. Gastroprotective effect of *Phyllanthus niruri* leaf extract against ethanol-induced gastric mucosal injury in rats. *AJPP.* 2010;4:226-230.
42. Airaodion AI, Ogbuagu U, Ogbuagu EO, Airaodion EO, Agunbiade AP, Oloruntoba AP, Mokelu IP, Ekeh SC. Investigation of Aqueous Extract of *Zingiber officinale* Root Potential in the Prevention of Peptic Ulcer in Albino Rats. *International Journal of Research and Innovation in Applied Science.* 2019;4(2):64-67.
43. Mahajan S, Mehta A. Curative effect of hydroalcoholic extract of leaves of *Moringa oleifera* lam. Against adjuvant induced established arthritis in rats. *Niger. J. Nat. Prod. Med.* 2009;13: 13-22.
44. Verma VK, Singh N, Saxena P, Singh P. Anti-ulcer and antioxidant activity of *Moringa oleifera* (Lam) leaves against aspirin and ethanol induced gastric ulcers in rats. *Int Res J Pharmaceut.* 2012;2: 46-57.
45. Ravindrath V, Chandrasekhra N. Metabolism of curcumin – studies with (3H) curcumin. *Toxicology.* 1981;22:337-344.
46. Owode AO, Airaodion AI, Adetutu A, Akinyomi OD. Levofloxacin induced dyslipidemia in male albino rats. *Asian Journal of Pharmacy and Pharmacology.* 2018;4(5): 620-629.