

First report in Sudan: The pathology of pulmonary papillary carcinoma in lungs of dromedary camels affected with pneumonia

Abstract:

Aims: To isolate and identify the bacteria associated with tumors and study the pathology of lung tissue affected with tumors in dromedary camels in Sudan.

Study Design: 45 lung samples of camels slaughtered at Tambool abattoir, Al-Gazeera state in Sudan of age ranging between 10-15 years, were subjected to bacteriological and pathological studies using standard methods .

Place of Study: This study was undertaken in the Departments of Bacteriology and Pathology, Central Veterinary Research Laboratories, Ministry of Animal Resources and Fisheries, Khartoum during 2015.

Methodology: The isolates were characterized using different techniques: conventional, Api kits and automated system Vitek 2 Compact. In histopathological method portions of Lungs tissues were fixed in 10% formalin, processed by standard method for paraffin wax embedding, 5 micron sections were cut and stained with hematoxylin and eosin (H and E).

Results: Four out of 45 lung samples (8.9%) were diagnosed as pulmonary papillary carcinoma. The most striking changes were complete obliteration of lungs tissues architecture, which were replaced with papillary fibrovascular projections with complex secondary and tertiary branches. The cells lined projections were found in clumps with indefinite polders and mostly over lapping each other. The nucleoli of this cells showed atypia with vesicular nucleoli forming empty glass appearance, with dark nucleoli, psammome bodies were identified in all cases and were often associated with the papillary component, either within fibrovascular cores or lining epithelium, infiltration of mononuclear cells, haemorrhage, necrosed detached tumor cells, and odema was detected in the affected lungs.

In this study Strep suis (S. suis), Bacillus sp and Staph aureus (S. aureus)

were isolated from lungs affected with papillary carcinoma, the isolation of these bacteria may have an importance in the future studies to determine the relationship between bacteria and such tumor.

Conclusion: the current study considered to be the first report for occurrence of pulmonary papillary carcinoma in dromedary camel in Sudan. Previous study done by Katja et al, 2017 declare that the infection of Gram positive bacteria might directly stimulate the tumor growth in lung cancer

Key words: *Bacteria, Carcinoma, Dromedary, Camel, Tumor, Sudan*

1. Introduction

Tumors are classified as either benign or malignant, according to their appearance and behavior. Tumor nomenclature is based on histological and behavior patterns. Histology provides information about the type of cell from which the tumor has arisen, whereas behavior provides information as to whether the cell is benign or malignant [1]. Benign tumors are usually well differentiated, localized that do not invade the surrounding tissues or metastasize to other organs. Metastasis is the process whereby malignant cells spread from their site of origin (a primary tumor) to distant sites and grow into secondary tumors. Malignant tumors are capable of invasion and spread to distant organs. This distinction is crucial in the clinic because metastatic disease is associated with significant morbidity and mortality. Malignant neoplasms can show a range of differentiations [1].

Main routes of metastasis

There are four main routes of metastasis, these are: local invasion which is the most common pattern of spread of malignant tumors by direct growth into adjacent tissues, lymphatic spread by forming secondary tumors in lymph nodes, blood-borne (haematogenous) spread in which the cells enter the bloodstream and form secondary tumors in organs perfused by blood that has drained from a tumor and transcoelomic spread in pleural, pericardial and peritoneal cavities [1].

Metastatic lung tumors are the most common and they result from displacement of malignant cells from a primary site to lymph vessels or veins, reaching the pulmonary circulation and lung tissue [2].

The development of cancer is associated with several genetic and environmental factors. Furthermore there has been an association between the development of cancer and bacterial and viral infections for decades. Several viruses can integrate into the human genome and directly initiate tumourigenesis, such as human papillomavirus (HPV) in cervical cancer and herpesvirus in Kaposi's sarcoma [3,4]. In other cases, the development of cancer is indirect, such as with *Helicobacter pylori*, which contributes to both gastric cancer and mucosa-associated lymphoid tissue (MALT) lymphoma due to chronic inflammation caused by the bacteria [5,6].

Numerous studies have reported different indigenous bacterial species being isolated from infected lesions in patients [7,8]. As early as 1868 Bush reported 2 patients with sarcoma that had been infected with *Streptococcus* spp [2]

2. Material and methods

45 pneumonic lungs samples were collected from Tambool abattoir, Al-Gazeera state in Sudan, for bacteriological and pathological studied using standard methods.

2.1 Identification of bacterial isolates:

Different procedures were used to identify the isolates using conventional, Api kits and full automated system, Vitek 2 Compact.

2.2 Characterization of the isolates using API kits:

For isolate with the Api kits, the organisms were sub-cultured on blood agar plates, each separately and after incubation for 24 hours at 37°C, for staph and strep, colonies from each fresh culture, were emulsified in Api medium and adjusted visually to 0.5 and 4 respectively MacFarland opacity tube that was prepared by adding 0.05 of 1.0% barium chloride to 9.95 of 1.0% sulfuric acid according to the type of kit.

2.3 Characterization by the Vitek 2 compact:

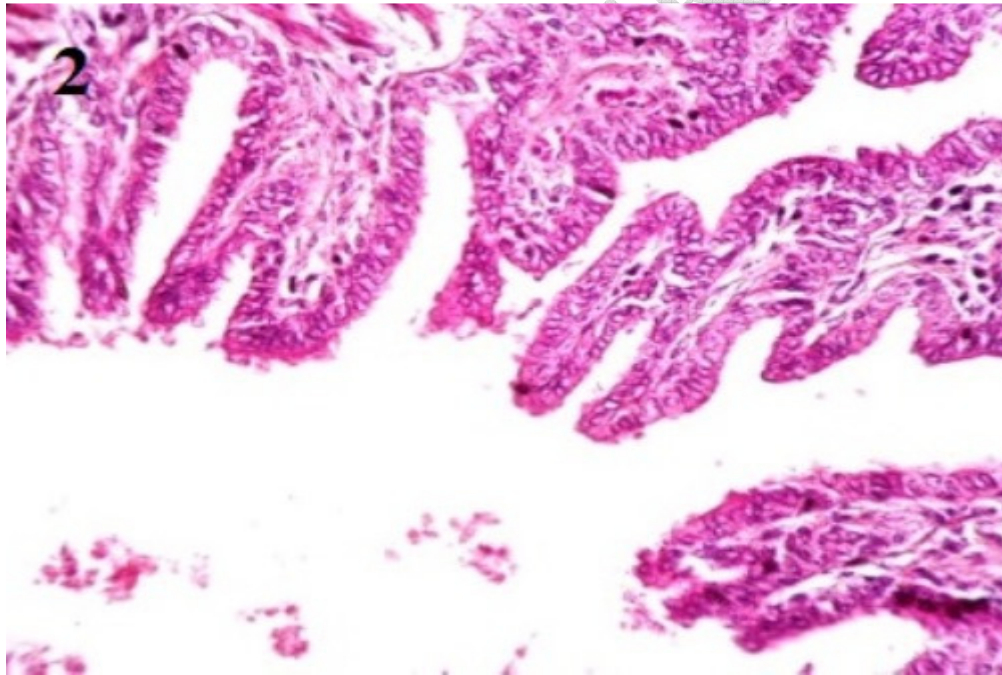
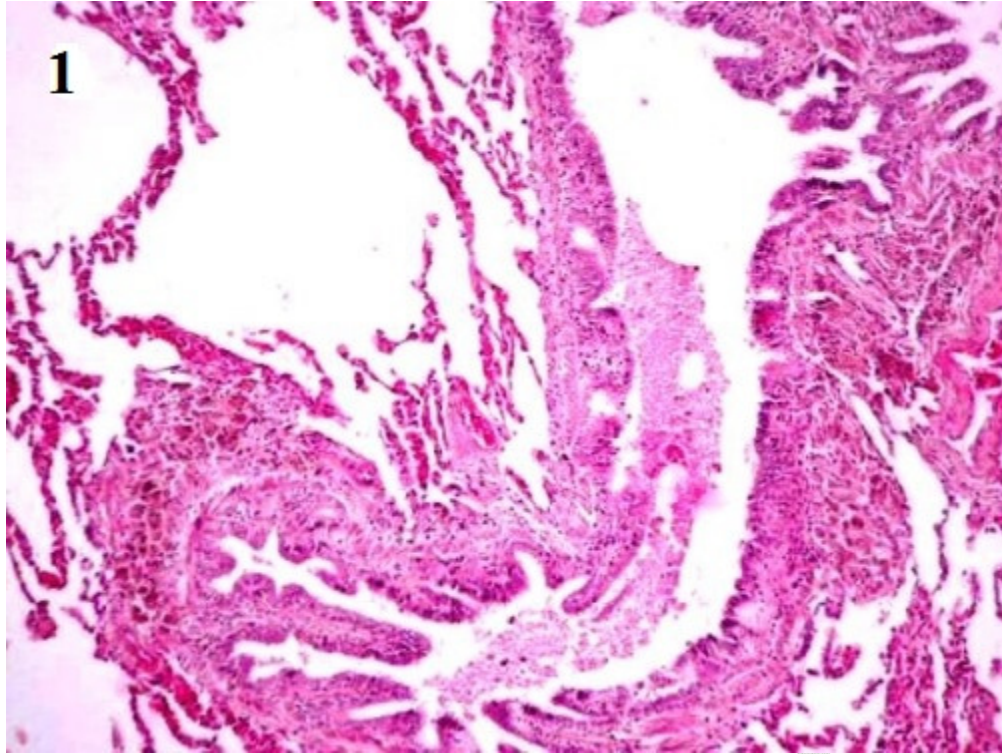
The card for each Gram positive bacteria was automatically filled by a vacuum device, sealed and inserted into the Vitek 2 reader – incubator module (incubation temperature 35.5°C) and subjected to a kinetic colorimetric measurement every 15 min. Data were analyzed using Vitek 2 database version 4.01. All cards used were automatically discarded into a waste container. Final identification results were available in approximately 8 hours or less.

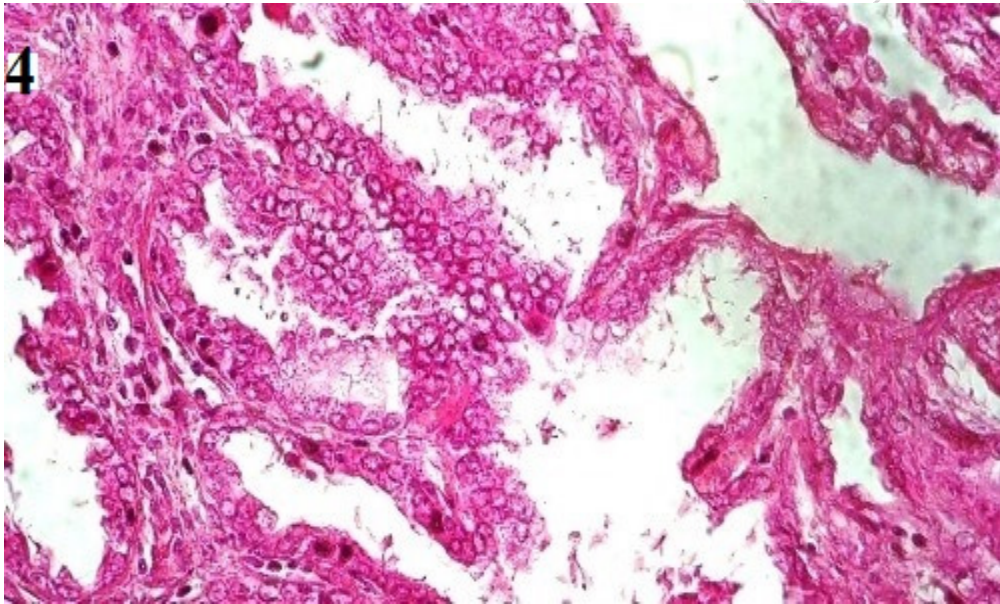
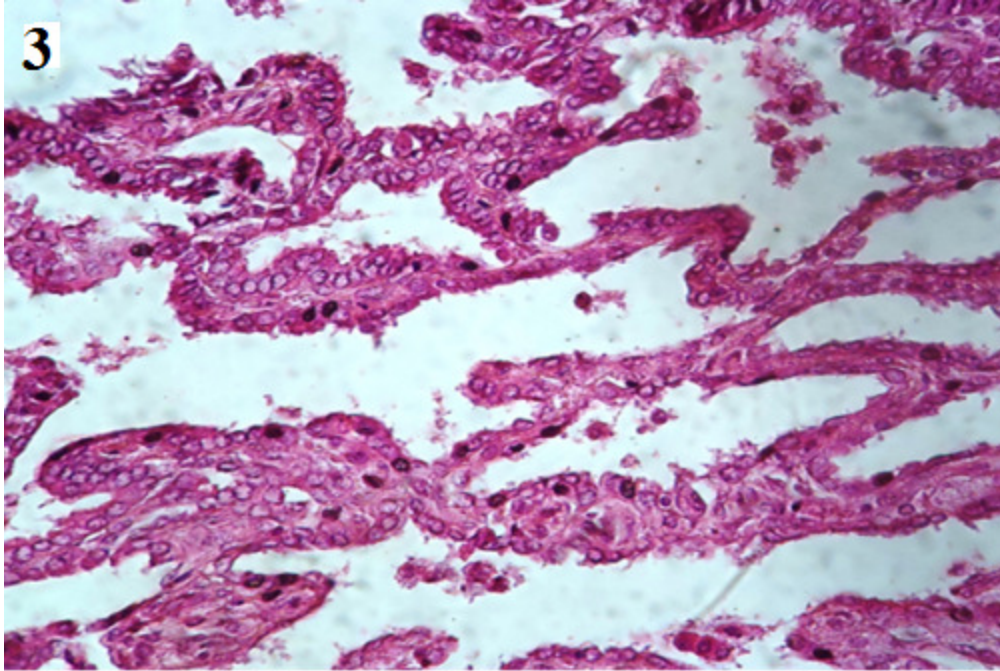
2.4 Histopathological Method:

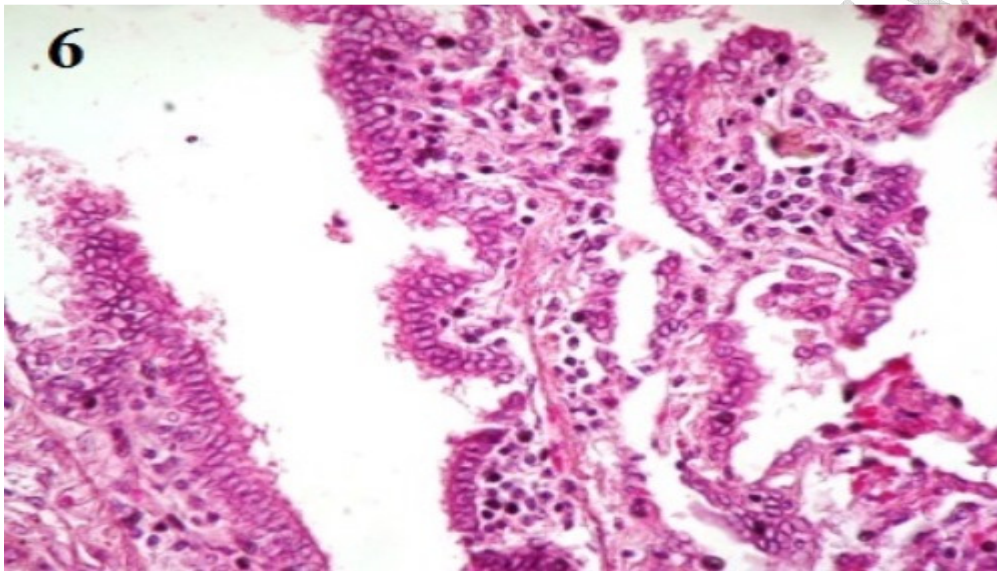
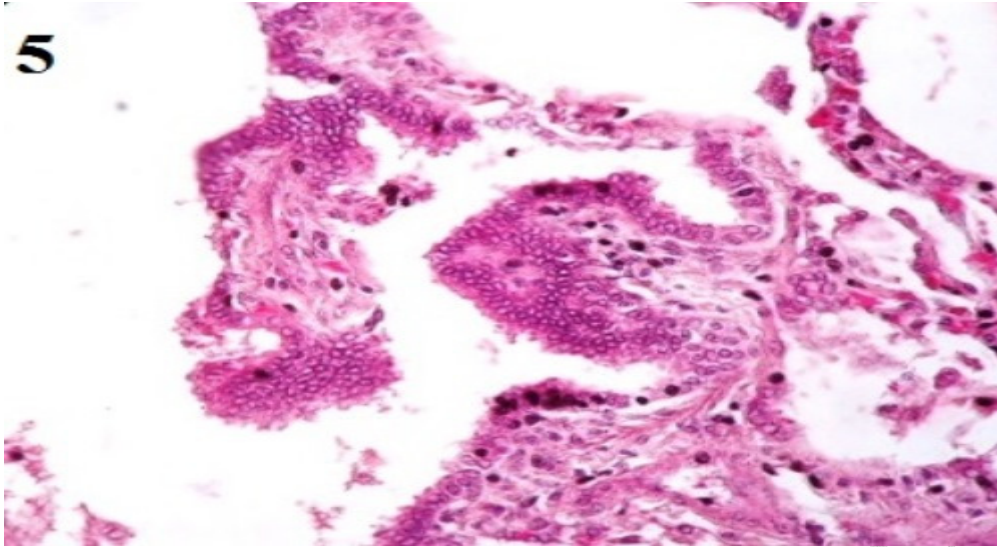
Tissue specimens collected for histopathological examination were fixed in 10% formalin solution, processed by standard paraffin embedding technique; microtomy of the embedded tissue to 5-6 micron thick sections was carried out. The sections were placed onto glass slides, dried and stained with hematoxylin and eosin (H&E).

3. Results and discussion

45 pneumonic lungs samples were collected as mention before, various types of bacteria were isolated and different histopathological lesions were noticed but four out of 45 lung samples (8.9%) were diagnosed as pulmonary papillary carcinoma from which *S.aurius*, *S.suis* and *bacillus* sp were isolated.







1- complete destruction of normal lung architecture, large papillary projection with complex branching.

2- fibrovascular cores papillary projection with primary and secondary branches.

3 atalactases, dark chromatin (nuclear atypia) in some areas, detachment of neoplastic cells floating between tumor branches.

4- necrosis, rupture of alveolar with edematous fluid.

5 Astormal infiltration of mononuclear cells, loss of arrangement, cell clumps, empty glass appearance, necrosis of tumor cell.

6-- Psammoma bodies , cuboidal and columnar neoplastic cells.

In this study, papillary carcinoma described as an unusual histopathological growth pattern characterized by complex papillary infoldings with complex branching, these agree with cesar. [9]. This report described pulmonary papillary carcinoma in female camels, which was diagnosed in Four out of 45 lung samples (8.9%) these animals were slaughtered at Tambool abattoir, at Al-Gazeera state in Sudan of age ranging between 10-15 years. To my knowledge, these are rare malignant tumors in lungs of animals, with a few documented reports in canine and feline.

Grossly, at necropsy, the animals were emaciated with multiple well defined pale yellowish spherical masses of various sizes and soft in consistency scattered in lungs were noticed, the cut surfaces were hemorrhagic.

In the current study the underlying pulmonary architecture was completely distorted and destructed, The neoplastic cells were small, cuboidal, or sometimes columnar as appear in fig 1, this similar to the description of Moulton [10] who reviewed the classification of Lung Carcinomas in the Dog and Cat. Papillary carcinoma of the lung is composed of papillary tufts containing fibrovascular cores (Fig 2).

papillary carcinoma, also characterized by vesicular chromatin and prominent nucleoli (nuclear atypia) (fig 3). In the present study, Psammoma bodies were noticed (fig 6) and they often associated with the papillary component, either within fibrovascular cores or lining epithelium as described previously by Silver etal,1997 .[11]

Astormal infiltration of mononuclear cells and necrosis (fig 4, 5) which defined by presence of aggregates of cellular necrosis, nuclear debris and neutrophils were apparently detected in my study in compair by

Elmahi, 2005 [12] who characterize adenomatous lesion in pneumonic lung of local indigenous Saudi goat.

A definitive diagnosis of cancer is frequently obtained by standard histopathology, biopsy specimens are analyzed by routine hematoxylin and eosin (H&E) staining for histopathologic evaluation. In this study, cells are scrutinized for features of malignancy, including abnormal morphology, evidence of invasion mononuclear cells as seen in fig 5 presence of abnormal mitoses, high nuclear cytoplasmic ratio, and absence of encapsulation. Malignant neoplasms are frequently poorly to moderately differentiated in fig 1 and 6 some may be so anaplastic that the cell of origin cannot be determined, these were similar to the observations of (Donald and James)[13] .

Acquired atelectasis was seen in fig 3 it occurs as **mension** by Donald in two main forms: compressive and obstructive. Compressive atelectasis has two main causes: space-occupying masses in the pleural cavity, such as abscesses and tumors, or from the transferred pressures, such as that caused by bloat, hydrothorax, hemothorax, chylothorax, and empyema. Another form of compressive atelectasis occurs when the negative pressure in the thoracic cavity is lost because of pneumothorax. This form generally has massive atelectasis and thus is also referred to as lung collapse. Obstructive (absorption) atelectasis occurs when there is a reduction in the diameter of the airways caused by mucosal edema and inflammation, or when the lumen of the airway is blocked by mucus plugs, exudate [13], microscopically the alveoli are collapsed and the alveolar walls appear parallel and close together as in (fig1).

in this study *S.suis* was isolated from pneumonic lung tissues that affected with papillary carcinoma, this was in agreement with Byron who reviewed many cases of *S. suis* infection and cancer together in human from different countries. [13]

There are several proposed factors involved in how bacteria replicate and survive within tumors. Traditionally, the main mechanism is thought to be due to the hypoxic nature of many solid tumors, which results in low oxygen levels compared with normal tissues, providing a unique growth environment for anaerobic and facultative anaerobic bacteria

[14]. Other factors contributing to bacterial replication in the tumor include the presence of bacterial nutrients within the necrotic region such as purines [15]. Furthermore, the involvement of bacterial chemotaxis towards chemo-attractant compounds present in necrotic regions (e.g. aspartate, serine, citrate, ribose or galactose) produced by quiescent cancer cells has also been suggested as a contributing factor [15].

S. aureus and *Bacillus* sp were mentioned by Joanne et al who reviewed the bacteria that were identified within patients of tumors and how they might be used in early detection of cancer (Bacteria and tumors: causative agents or opportunistic inhabitants)[2]

in study done by Katja in 2017, he demonstrated that purified Lipoteichoic acid (LTA) of *S.aureus* effectively induces growth of non-small-cell-lung-cancer (NSCLC) cell lines of adeno- and squamous cell carcinoma origin. Thus infection with gram positive bacteria may directly contribute to tumor growth in lung cancer.[16]

A case of *s.suis* infection associated with early stage colorectal carcinoma in a man who was old animal farmer was reported by Ioannis in 2006, this may explain the relationship between *S.suis* and neoplasia [17]

Detachment of tumor cells were observed clearly in the figures, this was explained by Bethan,etal 2012 in his book as he mentioned that To metastasize through vessels, neoplastic cells undergo the following sequence of events: detachment of tumor cells from neighboring cells, Invasion of the tissue basement membrane and then surrounding connective tissue, Extravasation into blood/lymphatic vessels, Evasion of the host's defense mechanisms, often by forming a tumor cell embolus with platelets or host lymphoid cells and Adherence to endothelium at a distant site[1]

4. Conclusion:

Although we cannot rule out the relationship between cancer and infection, we believe that malignancy, led to an immunosuppressed condition that facilitated the development of bacterial infection.

Pulmonary papillary carcinoma is a rare malignant neoplasm in camel.

The definitive diagnosis of this pulmonary neoplasia can be established only by a histopathological examination.

Screening for bacteria present in cancer tissues of various histological types may open up new dimensions in our understanding of this relationship, and its importance, if any. As high throughput deep sequencing technologies become more available, mining for bacterial strains adapted to survive within the tumor microenvironment will permit dedicated studies on this phenomenon, perhaps even leading to the characterization of a potential 'tumor microbiome',

References:

[1] Bethan Goodman Jones, Daniel J O'Connor, Atul Anand. Pathology Edinburgh London New York Oxford Philadelphia St Louis Sydney Toronto 2012.

[2] Joanne Cummins and Mark Tangney. Bacteria and tumours: causative agents or opportunistic inhabitants?. *Infectious Agents and Cancer* 2013, 8:11.

[3] Chang Y, et al: Identification of herpesvirus-like DNA sequences in AIDS-associated Kaposi's sarcoma. *Science* 1994, 266(5192):1865–1869.

[4] Huang YQ, et al: Transcription of human herpesvirus-like agent (HHV-8) in Kaposi's sarcoma. *J Clin Invest* 1996, 97(12):2803–2806.

[5] Cover TL, Blaser MJ: *Helicobacter pylori* in health and disease. *Gastroenterology* 2009, 136(6):1863–1873.

6. Polk DB, Peek RM Jr: Helicobacter pylori: gastric cancer and beyond. Nat Rev Cancer 2010, 10(6):403–414.

[7] Liong MT: Safety of probiotics: translocation and infection. Nutr Rev 2008, 66(4):192–202.

[8] Zhou JS, et al: Acute oral toxicity and bacterial translocation studies on potentially probiotic strains of lactic acid bacteria. Food Chem Toxicol 2000, 38(2–3):153–161.

[9] Pulmonary Adenocarcinoma The Expanding Spectrum of Histologic Variants Cesar A. Moran, MD(3) Arch Pathol Lab Med—Vol 130, July 2006

[10] J. E. MOULTONC., VON TSCHARNEaRnd R. SCHNEIDER. Classification of Lung Carcinomas in the Dog and Cat. Vet. Pathol. 18: 513-528 (1981)

[11] Silver, susan A.M.D; Askin, Frederic B.M.D. true papillary carcinoma of lung :A distinct clinicopathologic entity. the American journal of surgical pathology, 21(1)1997:43-51.

[12] Elmahi B.A. Adenomatous lesion in a pneumonic lung of a local indigenous saudi goat. Pakistan journal of biological sciences; 8(4); 2005 p542-545

[13] Donald M.M, James F.Z. PATHOLOGIC BASIS of VETERINARY DISEASE. Emerging Infectious Diseases • www.cdc.gov/eid • Vol. 20, No. 6, June 2014

[14]. Wei MQ, et al: Facultative or obligate anaerobic bacteria have the potential for multimodality therapy of solid tumours. Eur J Cancer 2007, 43(3):490–496.

[15]. Baban CK, et al: Bacteria as vectors for gene therapy of cancer. *Bioeng Bugs* 2010, 1(6):385–394.

[16] Katja Hattar¹ · Christian P. Reinert¹ · Ulf Sibelius¹ · Mira Y. Gökyildirim¹ · Florentine S. B. Subtil² · Jochen Wilhelm³ · Bastian Eul¹ · Gabriele Dahlem¹ · Friedrich Grimminger¹ · Werner Seeger^{3,4} · Ulrich Grandel^{1,5}. Lipoteichoic acids from *Staphylococcus aureus* stimulate proliferation of human non-small-cell lung cancer cells in vitro. *Cancer Immunol Immunother* (2017) 66:799–809.

[17] Ioannis A, streptococcus suis endocarditis and colon carcinoma: a case report. *clinical colorectal cancer* 6(3), 2006 p226-228

UNDER PEER REVIEW