

Recurrent Intestinal Necrosis due to polystyrene sulphonate use - a case report

Wai Tat Bernard Yung, Shun Yan Bryant Chan

Department of Surgery, No. 2 Po Ning Lane, Hang Hau, Tseung Kwan O Hospital, Hong Kong

Author's contributions

This work was carried out in collaboration between all authors. The first draft was written by Author YWTB. Author CSY reviewed and edited the draft of the manuscript. All Authors read and approved the final manuscript.

Abstract

Sodium or calcium polystyrene sulfonate (Resonium) is commonly used in hospitals to treat hyperkalaemia. Intestinal necrosis and perforation have been scarcely reported as a serious and potentially life-threatening complication following the use of this drug.^{1,2,3,4,5,6} Post-operative or end-stage renal failure patients are particularly at risk.

We present a rare case of a 79 years old lady developing recurrent bowel ulceration, necrosis and perforation under the effects of polystyrene sulfonate, with a remarkable onset of the last episode of perforation taking place 60 days after her last use of polystyrene sulfonate. Small and large bowel perforations were present. The patient underwent three laparotomy operations for resection of perforated bowel segments. As demonstrated in this case, the need for further clinical and biochemical research on the properties and safety profile of polystyrene sulfonate is evident. We advocate clinicians to be vigilant when patients present with abdominal symptoms with the context of hyperkalaemic patients undergoing medical treatment even in a delayed stage.

Keywords: Polystyrene sulfonate; Intestinal necrosis; hyperkalaemia

1. Introduction

Sodium or calcium polystyrene sulfonate (Resonium) is a cat-ion-exchange resin commonly used in hospitals to treat hyperkalaemia. Intestinal necrosis and perforation have been scarcely reported as a serious and potentially life-threatening complication following the use of this drug.^{1,2,3,4,5,6} Post-operative or end-stage renal failure patients are particularly at risk.

2. Presentation of Case:

A 79 years old lady with history of chronic renal impairment first presented with hyperkalaemia, [Serum potassium 5.7mmol/L], along with repeated vomiting and also urinary symptoms. Oral calcium polystyrene sulfonate 15g was given during hospitalization. She complained of progressive distending abdominal pain and absence of bowel opening for 2 weeks afterwards. Urgent computed tomography scan of Abdomen and Pelvis showed a 15cm long ischaemic distal jejunal segment with adjacent extraluminal gas and extensive portal venous gas [Figure 1]. Emergency laparotomy with resection and primary anastomosis of the ischaemic bowel segment was performed. Postoperatively the patient was noted to have hyperkalaemia and was prescribed 30g of oral Resonium C twice. On post-op day 7, patient developed severe metabolic acidosis with shock requiring inotropes support. Urgent computed tomography scan repeated showed pneumoperitoneum with pelvic fluid. Emergency Laparotomy revealed a 1mm perforation over terminal ileum and a 1.5 x 2cm area of patchy necrosis at hepatic flexure with evidence of impending perforation. Right hemicolectomy and partial small bowel resection was performed. Pathology report of resection specimens from both operations showed ulcers associated with crystalline material morphologically compatible with polystyrene sulphonate. The patient had an uneventful recovery and was discharged after two weeks.

The patient was readmitted three weeks later on post-op day 60, complaining of sudden onset severe abdominal pain with fever and metabolic acidosis. Computed tomography again showed

pneumoperitoneum with features of faecal peritonitis. Emergency laparotomy done showed 1.5cm small bowel perforation and two other adjacent 5mm perforation sites, small bowel resection was performed again. Pathology again showed rare crystalline material compatible with polystyrene sulphonate in small intestinal ulcers.

3. Discussion

Intestinal necrosis and perforation have been reported previously as a serious and potentially life-threatening complication following the use of polystyrene sulphonate. In 2009, the United States Food and Drug Administration (FDA) issued a warning against the concomitant use of sodium polystyrene sulfonate with sorbitol due to cases of colonic necrosis and other gastrointestinal adverse events.¹⁰

Sodium polystyrene sulfonate is a benzene, diethenyl-polymer, with ethenylbenzene, sulfonated, sodium salt. It can lower the level of potassium in our body by acting as a cation-exchange resin. When administered orally, Sodium polystyrene sulphonate (SPS) releases sodium ions in the acidic stomach, binds hydrogen ions, and exchanges hydrogen for potassium in the small and large intestine.

In its early use, SPS was administered as a suspension in water. However, concerns of constipation and fecal impaction lead to the common practice of administering it with hypertonic sorbitol, a cathartic agent. Abraham et al⁷ suggested that Sorbitol, rather than SPS resin itself, has been implicated in the development of intestinal injury.

End-stage Renal Failure may predispose patients to intestinal necrosis through changes in blood volume during dialysis, hyperreninemia, elevated prostaglandin production, and localized colonic mesenteric vasospasm.⁸

This is a rare case of a patient experiencing recurrent intestinal perforation, with a remarkable onset of the last episode of perforation taking place 60 days after her last use of polystyrene sulfonate. This patient does not have any risk factors predisposing to vascular occlusion, such as Atrial fibrillation, vasculitis, diabetes, etc. The Computed

Tomography scan of this patient also showed wide and patent mesenteric artery. Delayed intestinal transit has been suggested in postoperative patients, due to ileus or opiate use. Slow SPS transit leads to an increased risk of mucosal injury.⁹ We believe that deposition of SPS crystals may persist in bowel mucosa longer than most expected. In addition, the Resonium drug preparation used in our hospital is free of Sorbitol. Hence, Sorbitol alone cannot be blamed for the sole culprit causing intestinal injury or necrosis.

The need for further clinical and biochemical research on the properties and safety profile of Resonium is evident. We advocate clinicians to be vigilant when patients present with abdominal symptoms with the context of hyperkalaemic patients undergoing medical treatment even in a delayed stage.

4. Conclusion

Bowel necrosis and perforation is a potential complication of polystyrene sulfonate and may present in a delayed stage up to two months. Clinicians must be aware of this potential complication when prescribing Resonium for treating hyperkalaemia.

Consent

Nil

Ethical Approval

Nil

Competing Interests:

Nil

References

1. McGowan CE¹, Saha S, Chu G, Resnick MB, Moss SF. Intestinal necrosis due to sodium polystyrene sulfonate (Kayexalate) in sorbitol. South Med J. 2009 May;102(5):493-7. doi: 10.1097/SMJ.0b013e31819e8978.

2. Almulhim AS, Hall E, Mershid Al Rehaili B, Almulhim AS. Sodium polystyrene sulfonate induced intestinal necrosis; a case report. *Saudi Pharm J*. 2018 Sep;26(6):771-774. doi: 10.1016/j.jsps.2018.04.008. Epub 2018 Apr 12.
3. Trottier V, Drolet S, Morcos MW. Ileocolic perforation secondary to sodium polystyrene sulfonate in sorbitol use: a case report. *Can J Gastroenterol*. 2009 Oct;23(10):689-90.
4. Castillo-Cejas MD, de-Torres-Ramírez I, Alonso-Cotoner C. Colonic necrosis due to calcium polystyrene sulfonate (Kalimate) not suspended in sorbitol. *Rev Esp Enferm Dig*. 2013 Apr;105(4):232-4.
5. Goutorbe P, Moncriol A, Lacroix G, Bordes J, Meaudre E, Souraud JB. Intestinal Necrosis Associated with Orally Administered Calcium Polystyrene Sulfonate Without Sorbitol. *Ann Pharmacother*. 2011 Feb;45(2):e13. doi: 10.1345/aph.1M547.
6. Kao CC, Tsai YC, Chiang WC, Mao TL, Kao TW. Ileum and colon perforation following peritoneal dialysis-related peritonitis and high-dose calcium polystyrene sulfonate. *J Formos Med Assoc*. 2015 Oct;114(10):1008-10. doi: 10.1016/j.jfma.2013.02.006. Epub 2013 Apr 18.
7. Abraham SC, Bhagavan BS, Lee LA, et al. Upper gastrointestinal tract injury in patients receiving kayexalate (sodium polystyrene sulfonate) in sorbitol: clinical, endoscopic, and histopathologic findings. *Am J Surg Pathol*. 2001;25:637–644
8. Rashid A, Hamilton SR. Necrosis of the gastrointestinal tract in uremic patients as a result of sodium polystyrene sulfonate (Kayexalate) in sorbitol: an underrecognized condition. *Am J Surg Pathol*. 1997;21:60–69.
9. Gerstman BB, Kirkman R, Platt R. Intestinal necrosis associated with postoperative orally administered sodium polystyrene sulfonate in sorbitol. *Am J Kidney Dis*. 1992;20:159–161.
10. Administration, F., D., 2009. Kayexalate ® Cation-Exchange Resin.

Figures

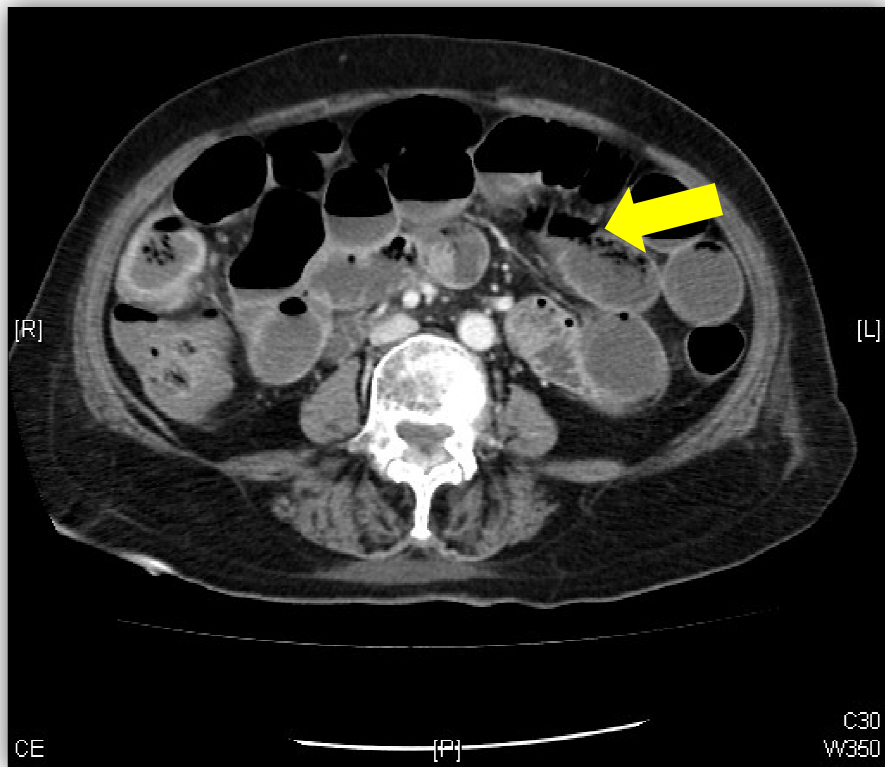


Figure 1: Computed tomography scan of Abdomen and Pelvis showing a 15cm long ischaemic distal jejunal segment with adjacent extraluminal gas

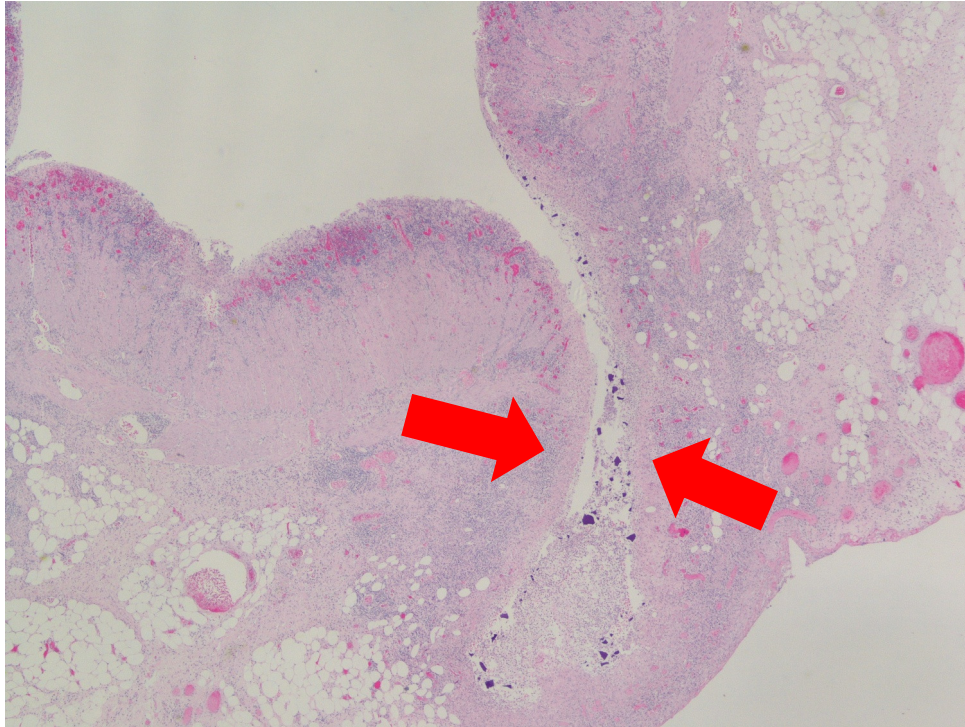


Figure 2: Multiple ulcers in colon and deep ulcer with transmural necrosis seen in histopathology

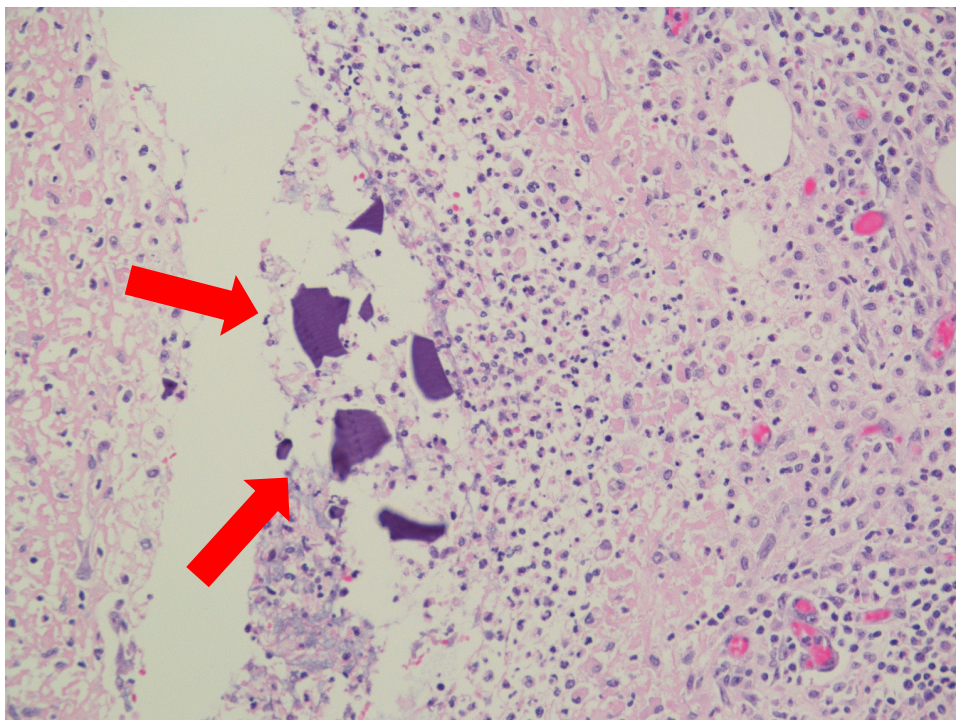


Figure 3: Purplish crystalline material overlying inflammatory exudate of ulcer floor