

Minimally Invasive Open Thyroidectomy: A safer approach in the era of minimally invasive surgery-A case series.

ABSTRACT

Complications related to the conventional thyroidectomy like the long scar in front of the neck, paraesthesia, hyperesthesia, voice changes, and dysphagia is still the matter of concern with conventional thyroidectomy (CT). Due to all these complications, minimally invasive surgery of head and neck is becoming popular nowadays. Advantages of minimally invasive thyroidectomy surgery (MITS) over CT cosmesis, less post-operative pain, shorter hospital stay and better functional outcomes (in terms of voice and swallowing). A thyroidectomy performed with incision of less than 3.5cm, without endoscope is term as the minimally invasive open Thyroidectomy (MIOT) or minimally invasive or non-endoscopic thyroidectomy (MINET). Since Dec 2011 we performed seven MIOT. All patients were female aged between 16-40 years. All seven patients had unilateral thyroid swelling and the size ranging from 3.3 × 2.8 to 4×4 cm. In the first three patients, we made an incision of 3.5 cm but thereafter we

reduced the length of the incision to 2.5 cm. Operating time was ranging from 107s to 56 mins. Except for the superficial thermal burn at the skin edge, no other complications were encountered in our series. Hospital stay was between 1 -2 days. VAS score was 1 in all patients except the first patient who sustained a thermal injury. She had a VAS score of 2. We used a simple four parameters score: Excellent, Good, Fair and poor. Except for this patient all patient has very minimal pain and good remarks for the cosmetic outcome. **With the improvement in our surgical techniques, our incision length, and duration of surgery reduced in subsequent cases.** Minimally Invasive thyroidectomy is a safe procedure and as it does not require any special equipment and training it can be done in any centers irrespective of hospital infrastructure.

Keywords: conventional thyroidectomy, long scar, postoperative pain, minimally invasive thyroid surgery, minimally invasive open thyroidectomy.

1. INTRODUCTION

As the mortality rate following thyroidectomy was 40% before 1850, the French Academy of Medicine banned thyroid surgery in 1850 [1]. Advances in surgical practice and techniques reduced the mortality rate to 0-1% [1,2] but a long scar in front of the neck, paraesthesia, hyperesthesia, voice changes [3], and dysphagia [3,4] is still the matter of concern with conventional thyroidectomy (CT). Due to all these complications, minimally invasive surgery of head and neck is becoming popular nowadays. Advantages of minimally invasive thyroidectomy surgery (MITS) over CT are

improved cosmesis, less post-operative pain, shorter hospital stay and better functional outcomes (in terms of voice and swallowing) [4,5].

A thyroidectomy performed with incision of less than 3.5cm, without endoscope is term as the minimally invasive open Thyroidectomy (MIOT) or minimally invasive or non-endoscopic thyroidectomy (MINET) [6]. Due to our hospital infrastructure limitations for video-assisted or pure endoscopic Thyroidectomy, we are still practicing MIOT and sharing our experience in seven cases with special reference to cosmesis, post-operative pain, operative time and morbidity.

2. MATERIAL AND METHODS:

Since Dec. 2011 we performed MIOT in seven cases. This trial was approved by the hospital scientific and ethical committee (File no-IEC-II/855/2011-2012). As we are shifting from CT to MIOT, we excluded patients with malignant pathology requiring neck dissection, previous neck surgeries, and Thyroiditis which are nowadays considered as relative contraindications and patients who required total or Near total Thyroidectomy. All seven patients were female between 16 to 40 years. Physical examinations in all the seven patients were suggestive of benign thyroid pathology clinically and without any cervical lymphadenopathy. All seven patients were biochemically euthyroid. Our practice is to do Ultrasonography (USG) neck before Fine Needle Aspiration Cytology (FNAC) for all thyroid swelling. FNAC confirmed colloid goiter (Bethesda II: Benign category) in all seven cases.

PROCEDURE:

Operative time was the time between the starting of the incision to the last stitch. To assess Pain, we used VAS score 24 hours for 2 days and we follow up the patients in one month and six months to assess the cosmetic outcome for which we used images of scars from CT and a simple chart using four parameters: Excellent, Good, Fair, and Poor. In all the cases Hemithyroidectomy was performed under general anesthesia.

INCISION (figure 1): Our practice is to mark the incision two fingerbreadths above the sternoclavicular junction or sternal notch in sitting position before intubation, unlike on extended neck commonly practice in many centres. The reason behind that is that on releasing the extension the incision reaches very near to the sternoclavicular junction which can lead to a hypertrophic scar.

TECHNIQUE:

After we made the incision, we simply deepen it until we reach the thyroid gland. We use small retractors to retract the skin and all the layers of the neck. We deal with the superior pole first followed by the middle thyroid vein region and finally the inferior pole. After neck wall retraction, we use two straight or curve artery forceps with a small swab at the tip to retract the thyroid upper pole towards the wound and to do blunt dissection respectively (Figure 2). We use to identify and isolate the superior laryngeal nerve and secure branches of the upper pole pedicle for which we used sutures, clips, and vessel sealing devices. We dint the record the time but we feel that the time consumption in securing the upper pedicle using any of these modalities is the same. Once the upper pole is free we deal with the middle

thyroid vein in the same manner as in CT. Thereafter we retract the thyroid gland medially and try to locate the tubercle of zuckerlandl (TZ) and inferior thyroid vessels. These are the landmark to identify recurrent laryngeal nerve (RLN). The thyroid gland is then delivered out of the wound (Figure 3) and dissected off from the fibrofatty tissue, branches of the inferior thyroid artery and trachea once we identified the RLN and traced it safely till its insertion. After hemostasis, we close the wounds in layers. **The Inner layers were approximated using 3-0 Polyglactin 910 (Vicryl) suture and skin was opposed by running subcuticular suturing using 3-0 monofilament braided nylon (Dermalon) sutures.** We did not keep drains in all our cases. In all seven cases, we could manage to complete the surgery with the mini-incision.

POSTOPERATIVE PERIOD: Except for the minimal superficial thermal burn in our first case, there were no other complications. The overall pain was very minimal. VAS score ranges from 1-2 till discharge. No patients developed signs and symptoms of hypoparathyroidism in the post-operative period. Sutures were removed on the 5th postoperative day.

Histopathological examination revealed Colloid goiter in all the seven cases.

Patients were reviewed after one month and six months to assess the cosmetic outcome. In the one-month review, we showed them images of scars from CT and the four parameters chart whereas in the six-month review we assess the outcome using the four parameters chart only. All the patients scored Good except the first patient who scored Fair. It's the same

patient who sustained a thermal injury of the skin edge. Figure 4 comprises two images of the scar of two different patients at six months review.

Statistics of all the seven cases are presented in Table 1.

Table 1:

Patient	1	2	3	4	5	6	7
AGE (In Years)	40	22	39	40	30	25	16
GENDER	F	F	F	F	F	F	F
LOBE INVOLVED	L	R	R	L	R	L	R
SIZE (USG Measurement)	3.3x2.8	4.5x2.5	4x4	3.8x3	4x2.9	3.5x3	3.9x2.7
INCISION LENGTH (in cm)	3.5	3.5	3.5	2.5	3	2.5	3
OPERATIVE TIME (Minutes)	107	90	89	62	56	65	67
COMPLICATIONS							
Bleeding (Post Op)	Nil	Nil	Nil	Nil	Nil	Nil	Nil
Recurrent Laryngeal Nerve/ Superior Laryngeal Nerve Injury	Nil	Nil	Nil	Nil	Nil	Nil	Nil
Thermal Injury	+	Nil	Nil	Nil	Nil	Nil	Nil
Wound Infection	Nil	Nil	Nil	Nil	Nil	Nil	Nil
HOSPITAL STAY (In	2	2	2	2	1	2	1

days)							
PAIN (VAS score)	2	1	1	1	1	1	1
COSMESIS (At 1-month review)	Fair	Good	Good	Good	Good	Good	Good

3. RESULTS AND DISCUSSION

Kocher's incision of Thyroidectomy was named after Theodor Kocher who is one of the pioneers in thyroid surgery [1]. The Original Kocher's incision was a vertical incision in the midline with a lateral extension for better access to the upper pole. Later he modified it to linear incision 2 finger breadths above the sternoclavicular joint which is now known as Kocher's incision or collar's incision [7].

In conventional Thyroidectomy usually, the length of the incision used to be about 8-10cm which results in a long scar [8] and on the other hand thyroid diseases are more prevalent in young and middle-aged females whose concern will be more towards the cosmesis after the surgery [4]. An Incision under 3.5 cm is the current definition for MIOT/MINET [6] but for generalized MITS there is no guideline regarding the length of the incision. There are two schools of thought; one group says any incision of less than 6cm should be considered minimally invasive whereas another group proposed that the term should be reserved for incisions shorter than 3 cm [8]. In the literature, the length of the incision varied from 1 - 4.5 cm for the minimally invasive approaches [3, 5, 7, 9].

This imbalance has given the minimal access surgery for the head and neck more popularity nowadays [10]. Gagner performed the first endoscopic parathyroidectomy in 1996, and that was the first reported minimal invasive surgery in the neck. Thereafter many techniques have been evolved in minimally invasive surgery of the neck focusing mainly on the cosmetic outcome [4].

MITS can be classified in many ways (Table 2):

Table 2:

<p>1. Based on the site of incision [11]:</p> <ul style="list-style-type: none">a) Direct/cervical approach (a small incision is made over the neck.): midline [9] or lateral [12].b) Indirect/extra-cervical approach: transoral, axillary, post-auricular and areolar approaches [11].
<p>2. Based on the technique [2]:</p> <ul style="list-style-type: none">a) Minimally invasive open thyroidectomy (MIOT) or minimally invasive non-endoscopic thyroidectomy (MINET),b) Complete endoscopic thyroidectomy (CET), andc) Minimally invasive video-assisted Thyroidectomy (MIVAT).
<p>3. based on incision on the neck [13]:</p>

INCISION ON THE NECK	NO INCISION ON THE NECK
<u>CET with gas insufflations:</u> Anterior approach Lateral approach	<u>CET with gas insufflations:</u> Axillary approach Anterior approach Mammary approach: <ul style="list-style-type: none"> - Axillo-bilateral mammary approach - Bilateral tranaxillary approach - Robot-assisted bilateral axillary approach
<u>MIVAT without gas insufflations:</u> Anterior Lateral	<u>MIVAT without gas insufflations:</u> Endoscopic axillary approach Robot assisted axillary approach Robot assisted bilateral transaxillary approach Anterior approach
<u>MINET:</u> Anterior Lateral	<u>Experimental approaches:</u> Transoral robot-assisted approach Dorsal approach

MIVAT is the most widely used MITS technique which was developed by Miccoli et al in the late 1990s [10]. Subsequently, MIOT (in 2001) and MINET (in 2011) came up [7].

The constant criteria for MITS in the literature are thyroid lobes of less than 3.5-4 cm for a benign nodule and volume less than 30 cc [2, 10, 13]. Till 2010 MITS were limited to low-risk well-differentiated thyroid cancer without any substernal extension and extrathyroidal spread [10] but according to

some recent reports size and histology should not be considered any longer as the limiting factors for MITS [7].

The major advantages of MITS techniques include minimal postoperative pain resulting in patient comfort, better cosmesis and shorter hospital stay which will lead to reduced cost of healthcare [5, 6]. MIVAT has the added advantage of a magnified and illuminated view of the operating field [10]. Pain is much less in MITS when compared with the CT because there are less dissection, traction, and destruction of tissues [10, 13, 14, 15]. The mini-incision is the main limitation for dissection and isolation of the superior pedicle. Few articles suggested incision near the upper pole [7] to avoid excessive traction which results in pain. We don't follow that practice, and we managed to complete the procedure with the usual incision level in all seven cases. In our series, the first patient complained of minor discomfort for 2 days as she sustained a superficial thermal injury of the skin edge from the cautery tip. Subsequently, we started to use tip guard from the next case. Remaining 6 patients in our series scored one according to the VAS score (Score 1: mild pain).

Initially, we made a 3.5 cm incision but after three cases we reduced our incision to 2.5 -3 cm and managed to complete the procedure without extending the incision length.

It is ideal to mark the neck incision two fingerbreadths above the suprasternal notch or higher in normal position rather than in an extended position after intubation as practiced in most of the centres. If we are

marking incision in the extended neck then it should be higher up in normal skin creases. The explanation behind this is that on releasing the extension the incision shifted more caudally almost near to the suprasternal notch. Low lying incision should be avoided as platysma is lacking in the midline at the level of the suprasternal notch and which can cause a hypertrophic scar or keloids [16]. Though one of the main benefits of MITS is the small scar, many articles reported a high incidence of hypertrophic scars or keloid especially with incisions over the anterior chest wall [17]. The small incision usually requires excessive traction for exposure which results in tissue damage leading to hypertrophic scarring. Hypertrophic scar results due to persistent inflammation and excessive deposition of fibroblast-derived extracellular matrix proteins [18]. Ezzat WH et al did not find any histological changes in the incision edges. The inflammatory reaction takes 24-48 hours to start and immediate fixation of the specimen may be the possible cause of this fallacy. The current practice of trimming damaged incision edges is aimed to approximate fresh wound edges, reducing the risk of hypertrophic scarring. In our series, we used a simple four parameters chart and all the patients scored Good except the first patient who scored Fair. It's the same patient who sustained a thermal injury of the skin edge.

In MITS post-operative hyperesthesia or paresthesia in the neck and discomfort during swallowing is less as this procedure does not require the creation of skin flap and also due to less tissue trauma as a result of minimal dissection [3]. No such complications occurred in our series till one month of

following up. Complications related to the extra cervical approach are pneumothorax, chest paresthesia, Brachial plexus injury, local wound infection, perforation, chest pain, Horner's syndrome [19].

The incidences of two of the major concerned complications of thyroid surgery (i.e. recurrent laryngeal nerve palsy and hypoparathyroidism) are similar to those seen in after CT [10,15]. In our series, we did not encounter these complications.

Based on the review of the literature, the overall incidence of complications and outcomes between CT and MIVAT and between MIVAT AND MINET is similar [6, 7, 15, 19]. **Del Rio P** et al stated that the overall outcome between CT and MIVAT was similar, but they found that the incidence of hypocalcaemia is less in CT due to better identification of the parathyroid glands. Fik Z et al reported that except less analgesic consumption the outcome between MIVAT and MINET is similar.

The main disadvantages of MITS procedures are the longer duration of surgery, steep learning curve and increased the cost of surgery due to equipment usage (MIVAT or Robotic MITS) and the inability to convert the incision if required [10, 17]. In our case series, the duration of surgery becomes less as we did the subsequent cases. Reduced operative time in our case series is due to the modification of the mistakes and difficulties encountered in the previous case/cases. Modification made like, use of the guard in cautery tip, use of small long blade retractors, use of curved artery

forceps to retract, use of clips or vessel sealing devices to secure vessels and dissection, proper hemostasis,). Regarding the cost factor in our case series, it was less because of less hospital stay and we didn't use any special instruments.

4. CONCLUSION:

Minimally Invasive Thyroidectomy is a Safe Procedure and as it does not require any Special Equipment and Training It Can Be Done in any Centers irrespective of Hospital Infrastructure.

CONSENT (WHERE EVER APPLICABLE)

Informed and written consent was taken from all the seven patients. Scan copy of one of the consent will be attached with the manuscript.

ETHICAL APPROVAL (WHERE EVER APPLICABLE)

N/A

REFERENCES

1. Dadan J, Nowacka A. A journey into the past – The history of thyroid surgery. *Wiad Lek.* 2008; 61:88–92. [PubMed: 18717051].
2. Radford PD, Ferguson MS, Magill JC, Karthikesalingham AP, Alusi G. Meta-analysis of minimally invasive video-assisted

thyroidectomy. *Laryngoscope*. 2011; 121:1675–1681. doi:
10.1002/lary.21864.

3. Dash AK, Meher D, Patro S, et al. Benign thyroid lesions: small incision hemithyroidectomy is a cosmetic alternative. *Natl J Otorhinolaryngol Head Neck Surg*. 2014; 2(11):21–22.
4. Fan Y, Guo B, Guo S et al. Minimally invasive video-assisted thyroidectomy: experience of 300 cases. *Surg Endosc* 2010: 2,393–2,400.
5. M. Subrahmanyam, R. Sirisha, A. Deepthi, R. N. Mishra. Minimally Invasive Hemithyroidectomy Using a Mini Incision over the Upper Pole of Thyroid Swelling. *Journal of Surgery*. Vol. 3, No. 3, 2015, pp. 21-25. doi: 10.11648/j.js.20150303.12.
6. Fík Z, Astl J, Zábrodský M. Minimally invasive video-assisted versus minimally invasive non-endoscopic thyroidectomy. *Biomed Res Int* 2014; 2014:450170.
7. Linos D. Minimally invasive non- endoscopic Thyroidectomy. A very high in the neck incision thyroidectomy incision. *World J Endoc Surg*. 2015; 7(2):51-52.
8. Zachariah SK. Gas-less video-assisted thyroidectomy for a solitary thyroid nodule: technical report of the first case performed at a rural teaching hospital in India and review of literature. *J Surg Tech Case Report* 2012; 4:27-3.
9. Ruggieri M, Straniero A, Mascaro A, Genderini M, D'Armiento M, Gargiulo P, et al. The minimally invasive open video-assisted approach in surgical thyroid diseases. *BMC surgery*. 2005; 5:9–9.

10. Kazi R, Katina R, Dwivedi RC. Minimal access thyroid surgery—a new down. *Ann R Coll Surg Engl.* 2010; 92:361–362. doi: 10.1308/003588410X12699663903755.
11. Lundgren CI, Stalberg P, Grodski S, Sidhu S, Sywak M, Delbridge L. Minimally invasive thyroid surgery for diagnostic excision of solitary thyroid nodules. *Asian J Surg.* 2007 Oct 1; 30(4):250-4.
12. Pai VM, Muthukumar P, Prathap A, Leo J, A R. Transoral endoscopic thyroidectomy: A case report. *International J Surg Case Rep.* 2015; 12:99–101. doi: 10.1016/j.ijscr.2015.04.010.
13. Sabuncuoglu MZ, Sabuncuoglu A, Sozen I, Benzin MF, Cakir T, Cetin R. Minimally invasive surgery using mini anterior incision for thyroid diseases: A prospective cohort study. *Int J Clin Exp Med.* 2014; 7:3404–3409.
14. Dionigi G¹, Rovera F, Carrafiello G, Bacuzzi A, Boni L, Dionigi R. New technologies in ambulatory thyroid surgery. *Int J Surg.* 2008;6 Suppl 1:S22-5. doi: 10.1016/j.ijisu.2008.12.029. Epub 2008 Dec 14.
15. Zhang P, Zhang HW, Han XD, Di JZ, Zheng Q. Meta-analysis of comparison between minimally invasive video-assisted thyroidectomy and conventional thyroidectomy. *Eur Rev Med Pharmacol Sci* 2015; 19:1381-7. [[PubMed](#)].
16. Gemenjaeger Z. *Atlas of Thyroid Surgery. Principles, practice, and clinical cases.* 1st Edition. 2009 Georg Thieme Verlag KG.
17. Billmann F, Bokor-Billmann T, Voigt J, Kiffner E. Effects of a cost-effective surgical workflow on cosmesis and patient's satisfaction in open thyroid surgery. *Int J Surg* 2013; 31–36.

18. Ezzat WH, O'Hara BJ, Fisher KJ, Rosen D, Pribitkin EA. The minimally-invasive thyroidectomy incision: a histological analysis. *Medical Science Monitor*. 2011; 17(2):SC7–SC10.
19. Del Rio P, Viani L, Montana, CM, Cozzani F, Sianesi M. (2016). Minimally invasive thyroidectomy: a ten years experience. *Gland surgery*, 5(3), 295-9.

APPENDIX

LEGENDS:

Figure 1: Incision of 3.5 cm

Figure 2: Artery forcep with a small swab at the tip use to retract the thyroid lobe.

Figure 3: thyroid lobe has been delivered out of the wound

Figure 4: scar after six months

Figure 4a): first patient of our series who sustained thermal burn.

Figure 4B): scar of the last patient from our series.

Figure 1:

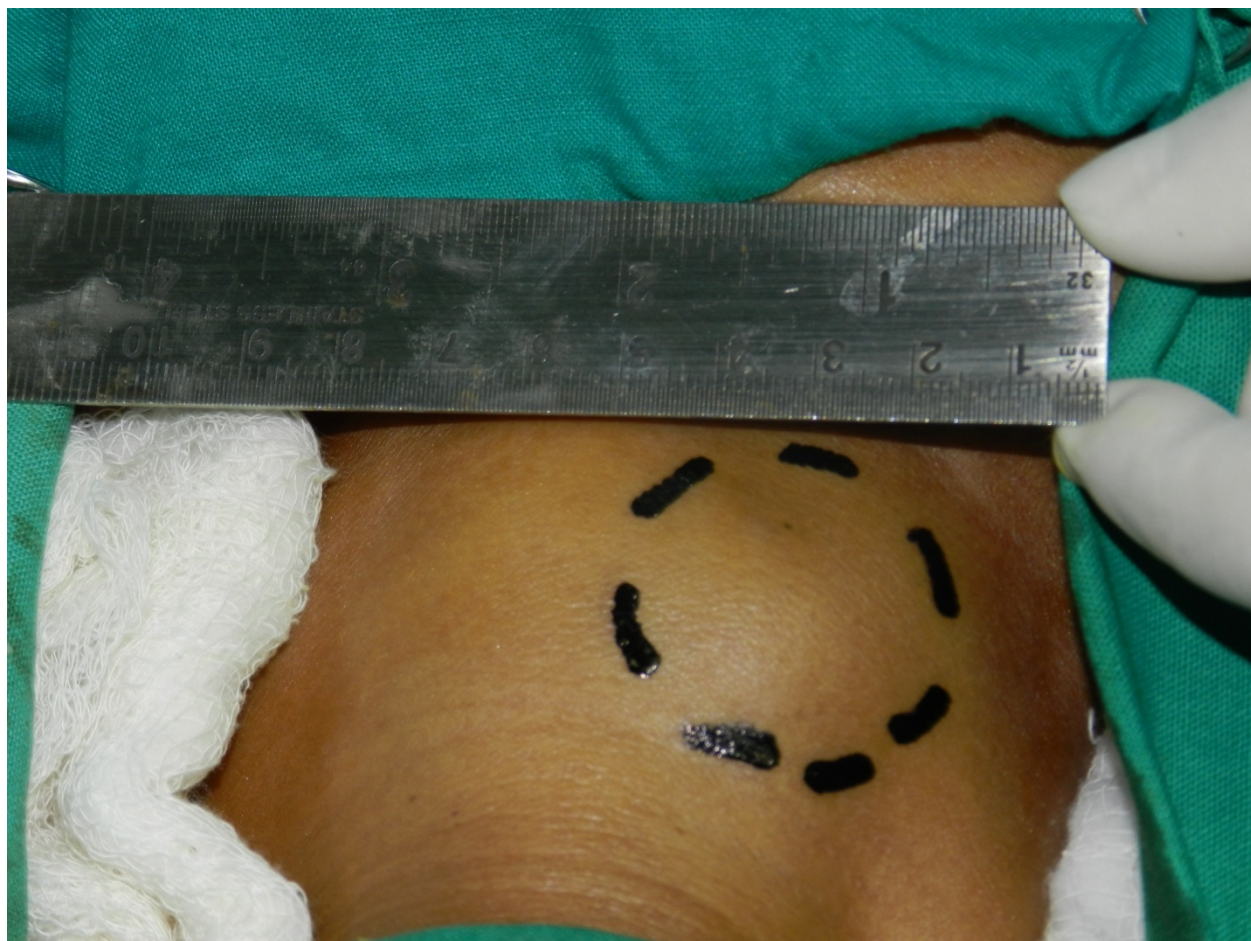
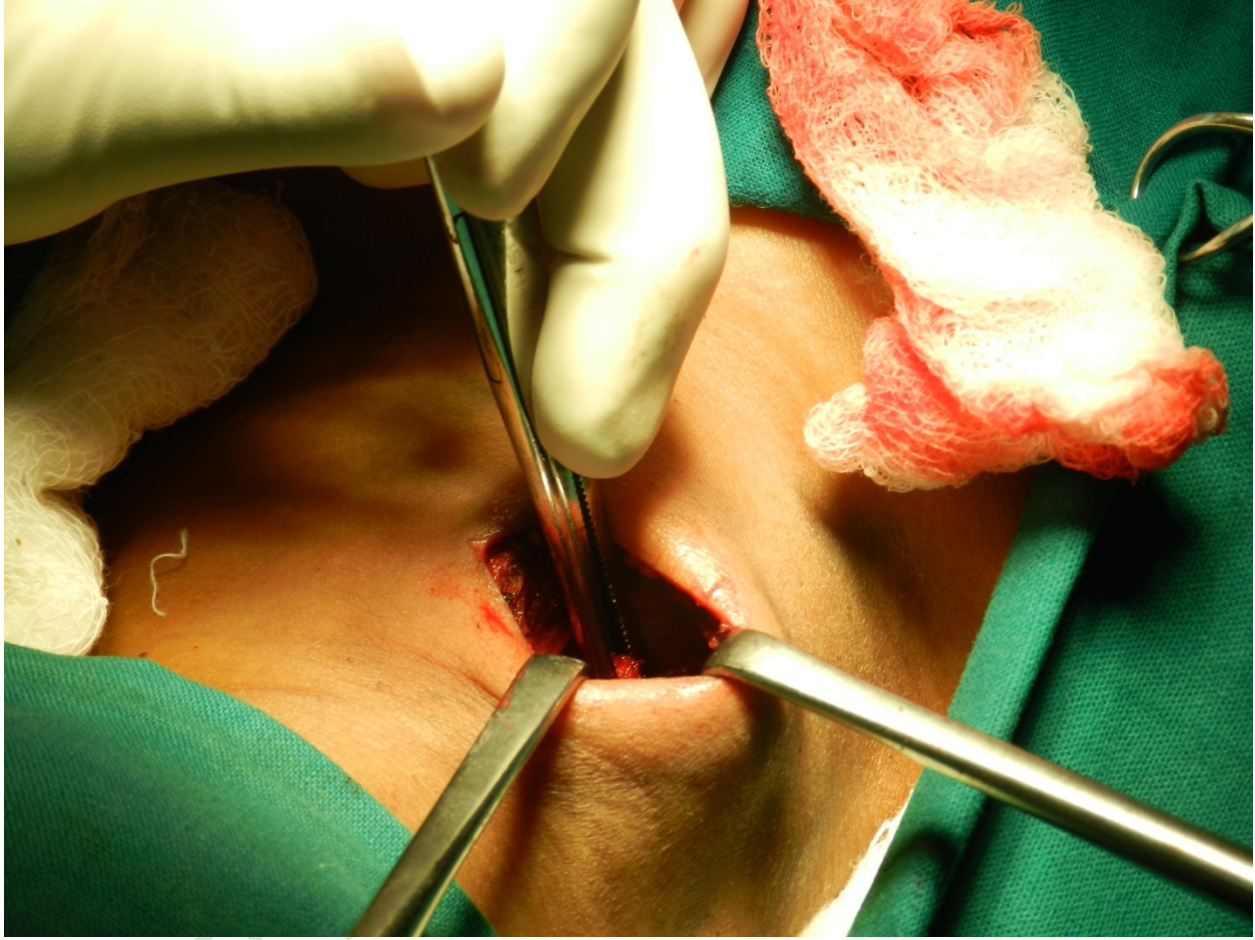

Figure 2:



UNDER

Figure 3:

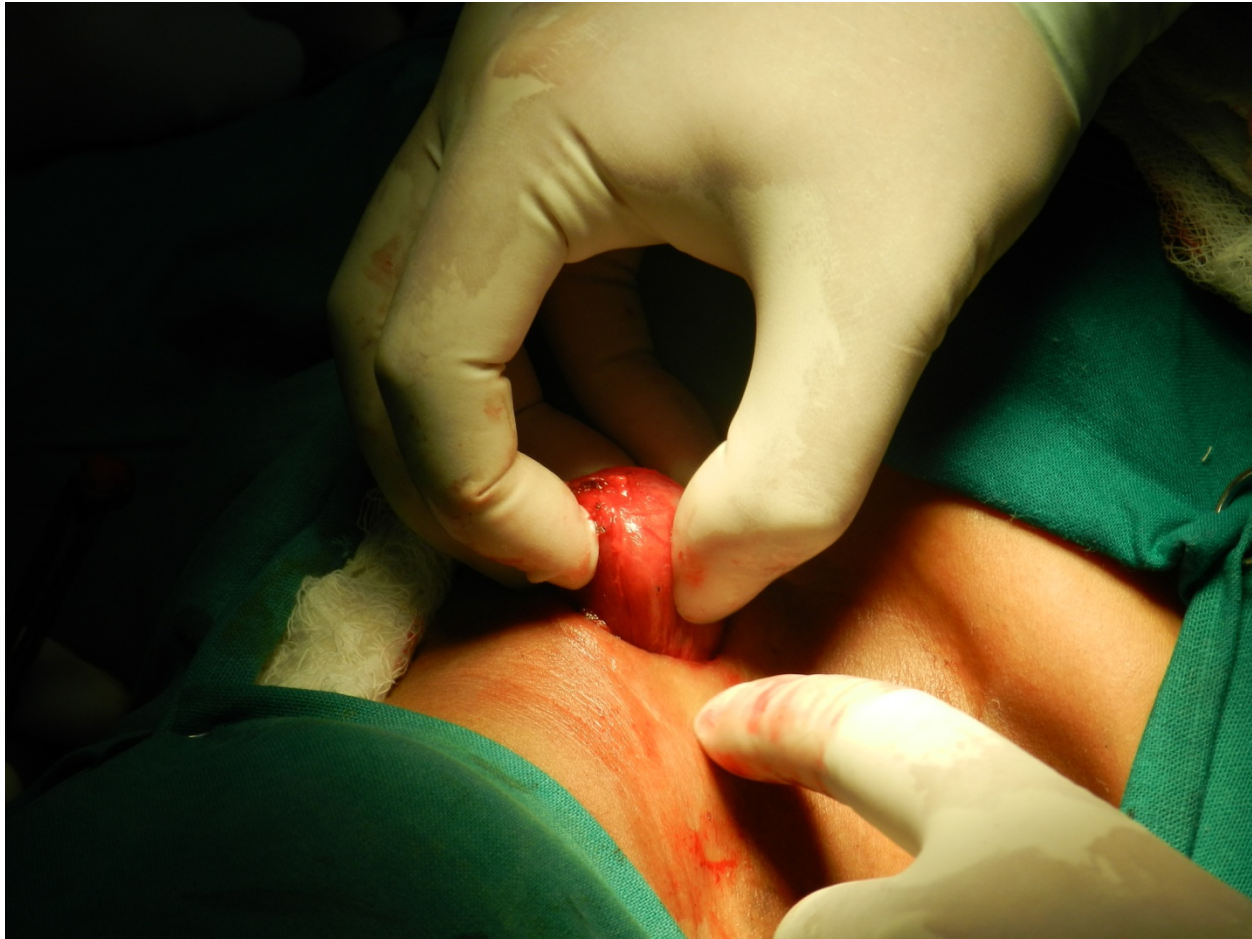
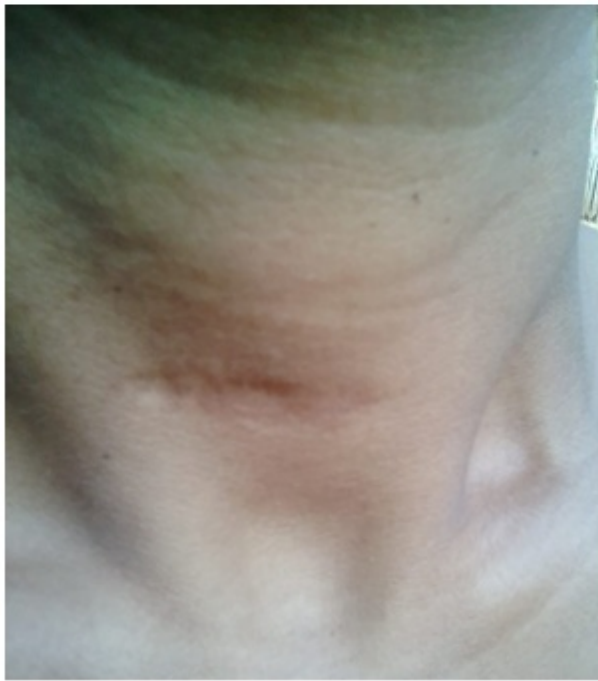
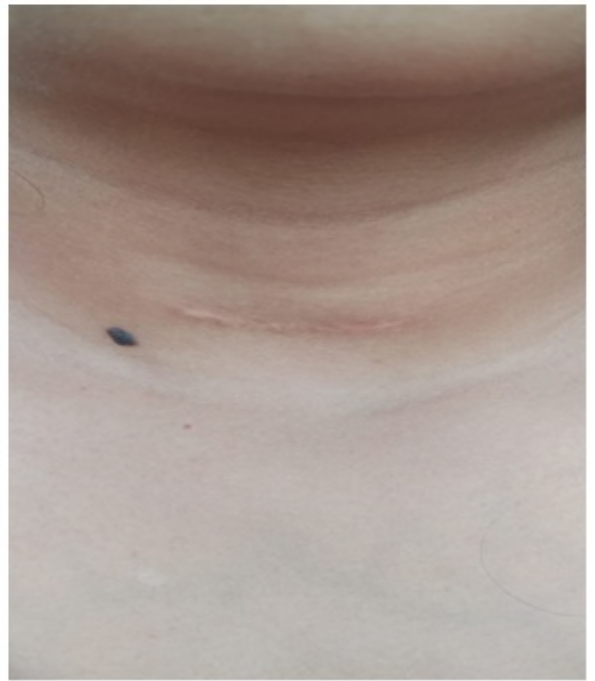Figure 4:

4a): Scar of the first patient



4b): Scar of the last patient of our series.



UNDER PEV