

Mid shaft femoral fracture in a young Haemophilia A Patient - A Case Report.

Shokunbi, W.A¹, Brown BJ², Okunola MO³, Akingbola TS¹, Aworanti, OW^{4*}

¹Department of Haematology, University College Hospital, Ibadan

²Department of Paediatrics, University College Hospital, Ibadan

³Department of Orthopaedics, University College Hospital, Ibadan

⁴Department of Haematology, LAUTECH Teaching Hospital, Ogbomoso

*corresponding author: Dr Oladapo 'Wale Aworanti, Department of Haematology, LAUTECH Teaching Hospital, Ogbomoso, Oyo state, Nigeria. aworantioladapo@yahoo.com

Abstract

Haemophilia is a rare X chromosome linked inherited bleeding disorder, characterized by deficiency of coagulation factor VIII in Haemophilia A or factor IX in Haemophilia B. Patients deficient of either of these coagulation factors are prone to fracture as a result of reduced bone mineral density. We present a case of mid shaft femoral fracture in a eight year old boy with Haemophilia A who slipped on a wet floor in his home. He initially presented at a private facility where he experienced mismanagement by the use of intramuscular injection before coming to our tertiary health care center, University College Hospital (UCH), Ibadan. Management of the fracture was also hampered by non availability of recombinant factor VIII concentrate at presentation; he was transfused with both whole blood and fresh frozen plasma. He had skin tractions done on two occasions with no alignment of the fractured bones before he subsequently had Plaster of Paris cast under recombinant factor VIII concentrate cover. He was discharged after 14 weeks on admission with x-ray at discharge showing over riding of the involved bones. Management of fracture in this haemophilia patient was a difficult task especially with his active lifestyle. Delayed presentation at a tertiary health care

facility and unavailability of recombinant factor VIII concentrate negatively affected the outcome.

Keywords: Factor VIII, Haemophilia, Fracture, Bleeding disorder

Introduction

Haemophilia is a rare X chromosome linked inherited bleeding disorder, characterized by deficiency of coagulation factor VIII in Haemophilia A or factor IX in Haemophilia B. The deficiency of either of these coagulation factors predisposes the patients to abnormal bleeding⁽¹⁻³⁾. The prevalence of Haemophilia A varies significantly among countries, the developed countries have a prevalence of 18 per 100,000males while for the other countries, the prevalence is 10 per 100,000 males.⁴ More than 75% of the bleeding in Haemophilia occurs in the musculoskeletal system. Haemophiliac patients have reduced bone mineral density and a higher rate of fractures compared to the general population, and the severity of the disease is also directly proportional to the risk of developing a fracture.⁽⁵⁾ We present a case of femoral fracture in a young boy with Haemophilia A

Case Report

DC is an eight year old male, primary three pupil who was diagnosed with Haemophilia A in 2009 as a neonate following post circumcision bleeding. He is the first child in a monogamous family setting. He has a younger brother who has no bleeding disorder. There is no history of bleeding disorder in the maternal lineage (family).

He has had multiple major bleeding episodes both before and after the diagnosis: post-circumcision bleed at 8th day of life, bleeding from a scalp laceration at 10th month of life, right foot haematoma, scrotal and gluteal bleed at infancy, gum bleed at 5years old and left knee haemarthrosis at 7years old.

He had Factor VIII assay done at infancy, which was found to be 18%, a repeat was done seven years after the first assay, and similarly found to be 19%. However, he has had major bleeds despite this moderate factor VIII level.

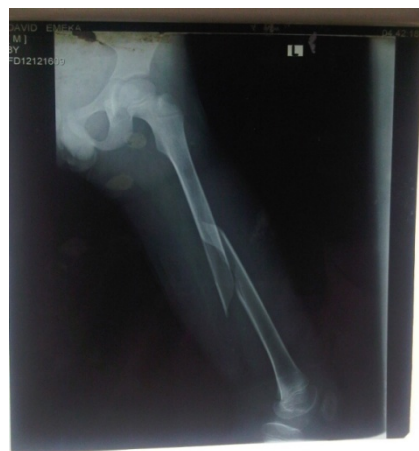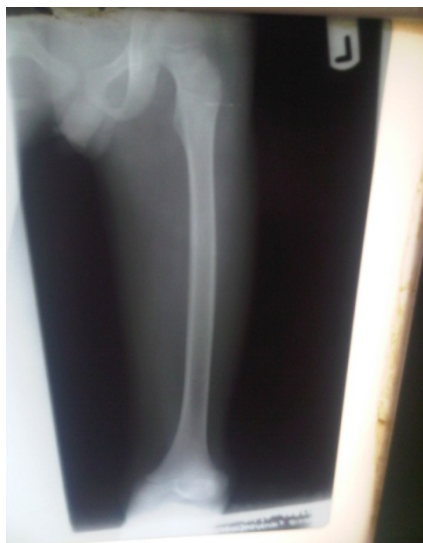He sustained a spiral fracture at the mid shaft of left femur after slipping on a wet floor. There was swelling of the left thigh and inability to use the left lower limb. He was taken to a private hospital where he had X-rays of the left thigh which showed left femoral spiral mid shaft fracture. He had intramuscular injection in the right gluteal region at the private hospital with severe bleeding and was referred to UCH on account of the bleeding. Examination at presentation showed a young boy who was not in painful distress, moderately pale, anicteric and acyanosed. Musculoskeletal system showed swollen and tender left thigh.

Investigations done at presentation show Packed Cell Volume of 18%, PT: Test- 15secs, aPTT : Test- 95secs, Control-35secs

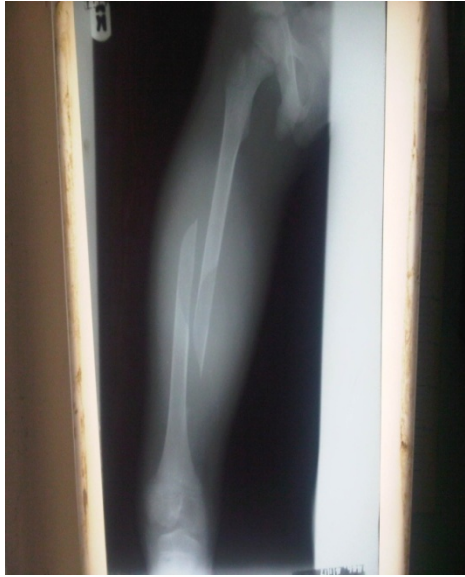Table 1: The Prothrombin Time and Activated Partial Thromboplastin of the Patient. PT Control- 15secs, aPTT Control-35secs

Week	Prothrombin Time (sec)	Activated Partial Thromboplastin Time (sec)	Comments
1st	15	95	At presentaion
2nd	14	105	

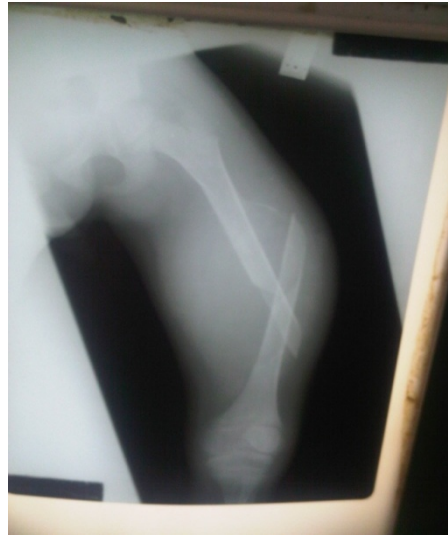3rd	15	105	
4th	14.5	46	2hrs post FVIIIc
10th	-	47	2hrs post FVIIIc
14th	-	73	2hrs post FVIIIc



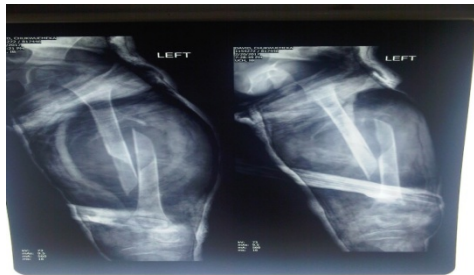
(1) (2)



(3)



(4)



(5)

Fig 1: Normal left femur done one year prior to fracture following left knee haemarthrosis

Fig2: 1st X-ray post fracture of the left femur

Fig 3: X-ray of the left femur after 1st skeletal traction

Fig 4: X-ray of the left femur after 2nd skeletal traction

Fig 5: X-ray of the left femur following POP cast

Due to non-availability of factor VIII concentrate at presentation, he was transfused with a total of seven units of FFP and three units of whole blood over three days. The bleeding at the gluteal region stopped on Day 5.

Following orthopaedic surgeon's review, a joint meeting was held involving the parents and the managing physicians- orthopaedic surgeon, paediatrician and Haematologist. It was an opportunity to counsel the parents again on the nature of the disease, treatment modalities and possible outcome. They both gave informed consent for the procedure and skin traction was done. Unfortunately, after few weeks of the skin traction, a repeat x-ray showed there was no alignment in the fractured bone. Repeat skin traction was done, 6weeks apart but due to the restless nature of the patient, there was mal-union. The swelling in the left thigh increased following the second skin traction and his PCV dropped from 25% to 15%. He had 250mls whole blood transfused; the post transfusion PCV was 21%. The limb was allowed to rest for about two weeks with no intervention; this is to allow for resolution of the swelling. Subsequently, he was commenced on recombinant Factor VIII concentrate at 1500units 12hourly.

Thereafter, he had left lower limb POP cast on his 10th week of admission, with infusion of 3,000IU of rFVIIIIC as prophylaxis. He had a total of 108,500 units of rFVIIIIC infusion over 46 days and there was a significant improvement, though the X-ray at the time of discharge showed the fractured bones overriding themselves. He was discharged after 14weeks of admission with a PCV of 30% and to continue

on blood supplements. He was subsequently followed up at the paediatric and orthopaedic outpatient clinics with shortening of the affected limb.

Discussion

Haemophilia is an X-chromosome linked inherited bleeding disorder, and is almost invariably a disease of males ⁽²⁾. All the over 100 haemophilia patients on our register are males. The disease is characterized by reduced or lack of synthesis of coagulation factor VIII (Haemophilia A) or factor IX (Haemophilia B) ⁽¹⁻³⁾. The most common type of haemophilia is haemophilia A, and this accounts for about 85% of the cases ^(6,7).

The severity of the disease is graded based on the percentage of the concentration of the coagulation factor: severe (<1%), moderate (1% to 5%), and mild (>5%)^(2,3). Risk of bleeding and complications is directly associated with percentage of coagulation factor⁽³⁾. The index patient with FVIIIc level of 18% has a mild disease based on the severity classification. However, clinically he exhibited features of a severe disease having about eight major bleeding episodes before this report. The bleeding phenotype in haemophilia has been recently described as heterogeneous, and does not necessarily depend on the percentage of the factor level alone^(8,9). He was diagnosed following post circumcision bleeding, in line with previous findings by A Jamil et al 2003, who reported that about 65% of haemophilia diagnosis were made within the first seven days following post circumcision bleed^(10,11).

The fracture in this patient followed a major trauma as he slipped on a wet floor. This follows previous reports that bleeding in a haemophliac, with factor VIIIc level of more than 5% usually occurs following a major trauma. Fracture is also

common in haemophiliacs with an active lifestyle as seen in this case, i.e that of a young boy who has been very active since birth, not understanding the implications of the diagnosis of haemophilia

Fractures in the upper limbs are commoner in Haemophilia, though lower limbs used to be more frequent prior to the millennial year⁽¹⁾. The patient was initially treated at a private facility where intramuscular injection was given, this contradicts the treatment guideline for the management of haemophiliac⁽³⁾, which includes no intramuscular injection because of the risk of haematoma. He was initially transfused with fresh frozen plasma and whole blood at presentation, these are not the ideal treatment plan for haemophiliacs. Only 15% of the haemophiliacs worldwide has access to ideal treatment.⁽²⁾

This patient had skin tractions on two occasions which were unsuccessful before a closed plaster cast was eventually applied, this is against the recommendations in the management of fractures in haemophilia, closed plaster casts are not recommended in hemophilia for the risk of compartment syndrome. A rigid internal fixation is preferred to external fixation, but this has to be done under recombinant factor VIII concentrate cover, which is not readily available in our environment and it is quite expensive^(3,6).

The objective of modern fracture treatment is to obtain an optimal outcome with the patient's return to full activity as soon as possible, we could not achieve this outcome in this patient because of delay in presentation to UCH, delay in accessing adequate rFVIII concentrate and the cost implication. There was mal-alignment of the fractured femur at discharge, which could have been prevented by internal fixation.⁽³⁾

Currently, internal stabilization is indicated in most displaced fractures in the adult, whereas external fixation remains the best choice for initial stabilization when the fracture is complicated by severe soft-tissue injuries. If a fracture is promptly treated in a haemophilia patient, it will progress to healing in a similar time frame to those occurring in the general population.⁽⁶⁾

This case report tries to explain the difficulties encountered in managing skeletal complications in patients with Haemophilia in Low resource country in Nigeria, and shows the level of awareness of this disorder in our environment.

Conclusion

Mid shaft fracture was seen and managed in a young haemophilia patient despite having a moderate disease. He however has a very active lifestyle, maybe because of his age. He was discharged home without full recovery. Prompt presentation at a tertiary health care facility, where multidisciplinary services are available will go a long way in getting an optimal outcome. There is also a need to make recombinant factor VIII concentrate more readily available and less expensive to patients with haemophilia especially in low resource country like Nigeria.

References

1. Cariglia H, Landro M.E, Galatro G, Candela M, Neme D. Epidemiology of fractures in patients with haemophilia. *Injury* 2015; 46(10):1885-1890
2. World federation of haemophilia. Guidelines for the management of Hemophilia 2nd edition
3. Rodriguez-Merchan E.C. Musculoskeletal complications of Hemophilia. *HSS J.*2010 Feb; 6(1):37-42
4. J.S Stonebraker, P.H.B Bolton-Maggs, J. Michael Soucie, I Walker, M.Brroker.A study of Variations in the Reported Haemophilia A Prevalence Around the World. *Haemophilia* 2010; 16(1):20-32
5. Gay ND, Lee SC, Sochacki P, Recht M, Taylor JA. Increased fracture rates in people with haemophilia: a 10-year single institution retrospective analysis. *British Journal of Haematology.* 2015, 170:584-586
6. Alhaosawi MM. Guidelines of management of musculoskeletal complications of hemophilia. *J.Appl Hematol.* 2014; 5: 75-85
7. Beyer R, Ingerslev J, Sorensen B. Current practice in the management of muscle haematomas in patients with severe haemophilia. *Haemophilia* 2010; 16:926-31
8. Coppola A, Capua MD, Dario Di Minno ND,Di Palo M, Marrone E, Lerano P, et al. Treatment of hemophilia: a review of current advances and ongoing issues. *J Blood med* 2010; 1: 183-195
9. van Dijk K, Fischer K, van der Bom JG, Grobbee DE, van den Berg HM. Variability in clinical phenotype of severe haemophilia: The role of the first joint bleed. *Haemophilia.* 2005;11(5):438–443.
10. Jamil A, Bayoung M, Iram D, Ader B. Paediatric severe haemophilia: Initial presentation, characteristics and complications. *The Internet Journal of Haematology.* 2003(1):2
11. Shittu OB, Shokunbi WA. Circumcision in haemophiliacs: the Nigerian experience. 2001 Sep; 7(5): 534-536