

original research paper

Intracystic papillary carcinoma in the mammary gland of she-camel (*Camelus dromedaries*), Sudan

ABSTRACT

Aims of the Study: Survey of udder disorders over one year to investigate the histopathological lesions of tumors in camel (*Camelus dromedarius*).

Place of Study: The study was undertaken in the Department of Pathology, Central Veterinary Research Laboratory, Ministry of Animal Resource and Fisheries, Khartoum, Sudan

Study Design: 45 tumors of camel udder tissues were obtained from Tumboul abattoir Al-Gazeera State; the gross and histopathological lesions were studied.

Methodology: The macroscopic pictures of samples were reviewed and described, then histopathological lesions were studied using H&E stain. Lastly immunohistochemical staining was done using estrogen, progesterone antibodies and **CytoKeratin 5/6**.

Results: Intracystic papillary carcinoma (IPC) was diagnosed in a 13-year-old non-pregnant, non-lactating local eco-type she-camel. Out of 23 malignant tumors, the udder displayed multiple neoplastic masses entrapped in multiocular cystic spaces. The neoplastic cells were arranged in papilliferous fronds supported by fibrovascular stalk. These cells were pleomorphic cuboidal to low columnar epithelial cells with vesicular nuclei. Tumor invasion was encountered in the cystic wall and lymphatic vessels

Conclusion: To the best of our knowledge this may be the first intracystic papillary carcinoma reported in the udder of a dromedary worldwide.

Keywords: Intracystic papillary carcinoma, immuno-stain mammary gland, the dromedary-she-camel, Sudan.

1. INTRODUCTION

Neoplasms of the mammary glands occur in all animal species. The prevalence of tumor in carnivores and herbivores and between captive and wild carnivores is quite different (1). This neoplasm is the most common in bitches; it ranks third after skin and lymphoma in queens (2). The available literature on papillary cystadenoma in food producing animal is rare (3). The occurrence of intracystic papillary carcinoma in herbivores is meagre. Only there was a single report that on multicentric papillary cystadenoma in a cow (4). To the best of our knowledge this may be the first of intracystic papillary carcinoma report in the udder of dromedary worldwide.

2. MATERIALS AND METHODS:

2.1 Case history

During a survey of udder affections of slaughtered she-camels was conducted at Tumbol slaughterhouse, El-Gezira, State, Sudan. A thirteen-year-old, non-pregnant, non-lactating local eco-type she-camel with a history of chronic incurable udder affection was examined at slaughter. She originates from North Drafur State. **The udder was slightly swollen, hard in consistency and the teat of the left hind quarter was distended approximately 2-3 times the normal size, completely obstructed canal. On cut section the udder was lobulated, grayish-white with arborescent growth with irregular extensive branches hanging from the body of the udder filling and occluding the teat canal.**

2.2 Histopathological method

Tissue specimens from udder were fixed in 10% formalin, processed routinely in paraffin wax and 5-6 μ sections were cut and stained with haematoxylin and eosin (H&E). For tumor Immunohistochemistry using dextrane polymer_hrp for estrogen and progesterone receptor was done, and Ck 6&7.

3. RESULTS

At slaughter, the udder was slightly swollen, hard in consistency and the teat of the left hind quarter was distended approximately 2-3 times the normal size, and its canal was completely obstructed. On cut section the udder was lobulated, grayish-white with arborescent growth with irregular extensive branches hanging from the body of the udder filling and occluding the teat canal. Small multi-papillae forming bunch of grabe-like structures were projecting from these arborescent growths (fig 1).

Histopathologically, the most prominent finding was complete obliteration of normal udder tissue which was replaced by multilineoplastic masses entrapped in multilocular cyst or dilated ducts. The papillary fronds infiltrated into primary, secondary and tertiary branches (fig 2). Tumor invasion of the cyst wall and the lymphatics were detected. The lobules bordering the neoplastic masses presented areas of early tumor transformation with the papillary fronds appeared to be emerging from, or infiltrating into apparently normal secretory acini (fig 3). Each cyst was lined with one layer of flat to low cuboidal epithelial cells surrounded by fibrous tissue, stroma that varied in size from narrow to moderately wide in size. Each of the neoplastic masses composed of densely packed papilliferous fronds supported by fibrovascular core that appeared to be projected from the cyst wall (fig 4). Some papillary projections were covered with one or multi-layers of cuboidal to low columnar epithelial cells. On the other hand exophytic intracystic papillary fronds covered with

pleomorphic poorly orientated undifferentiated epithelial cells were regularly encountered together with stratification of the nuclei which formed irregular clusters. The nuclei were vesicular or clear with the ground-glass appearance. Dystrophic calcification was encountered in the epithelium and

connective component of neoplastic masses. Moderate mononuclear cells reaction was observed in stromal connective tissue.

Immunostain for estrogen and progesterone were both negative while the ck 5/6 was highly positive (fig 5)



Fig 1: Macroscopic appearance of the tumor.
A formalin fixed piece of the tumor showed a lobular pattern delineated by fibrous septa.

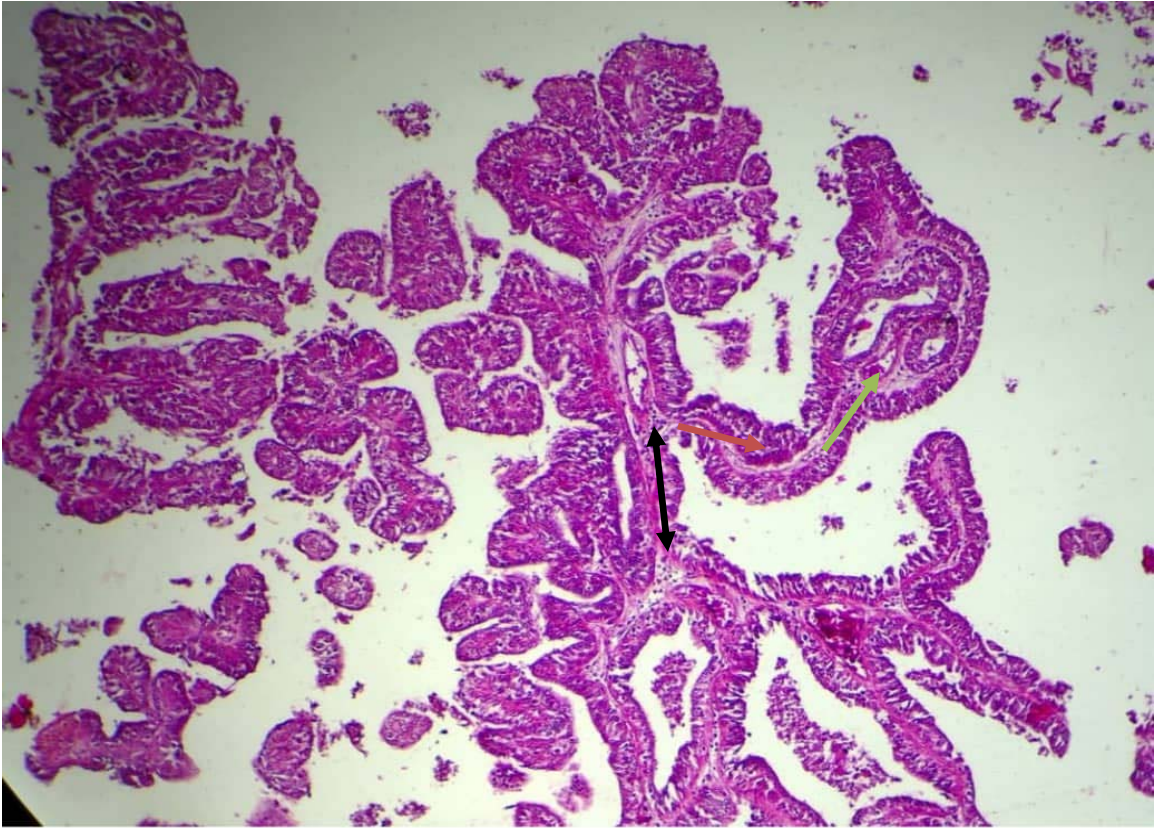


Fig 2: Intracystic papillary carcinoma, Note complex fibrovascular core with primary (black), secondary (red) and tertiary (green) branches H&E x10.

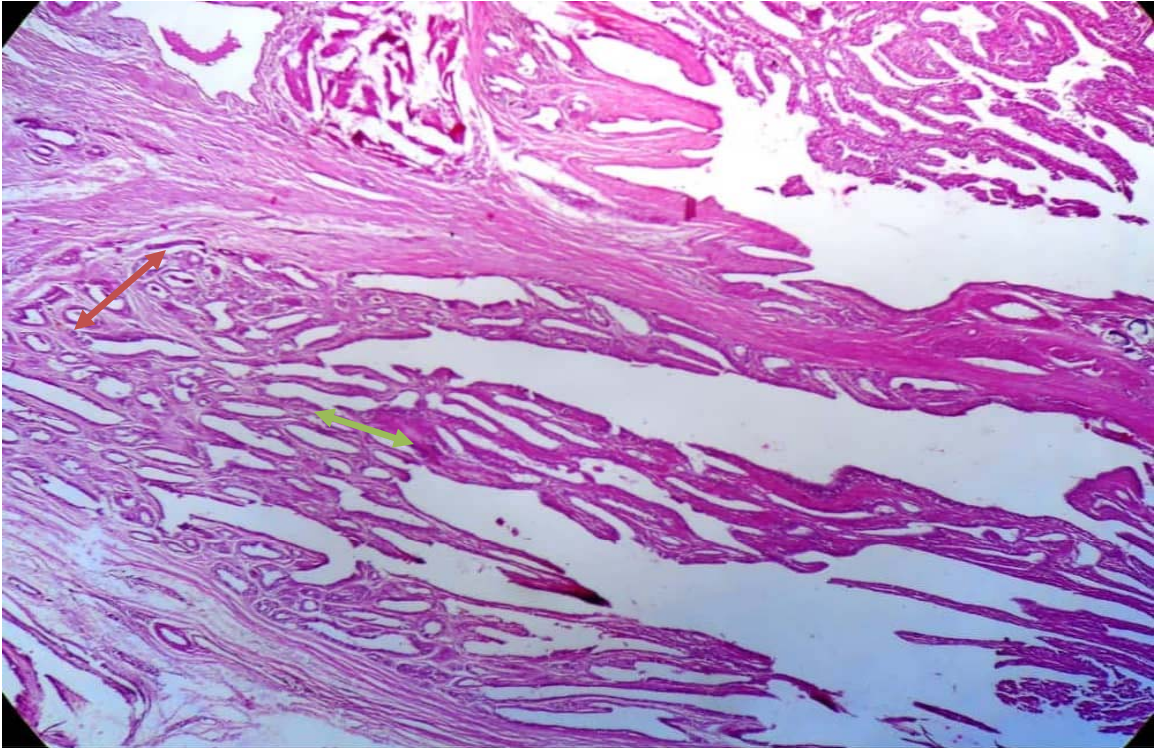


Fig 3: Intracystic papillary carcinoma Note, Early tumor transformation (green arrow) or infiltrated in apparently normal glandular tissues (red arrow) H&E x4.

UNDEI

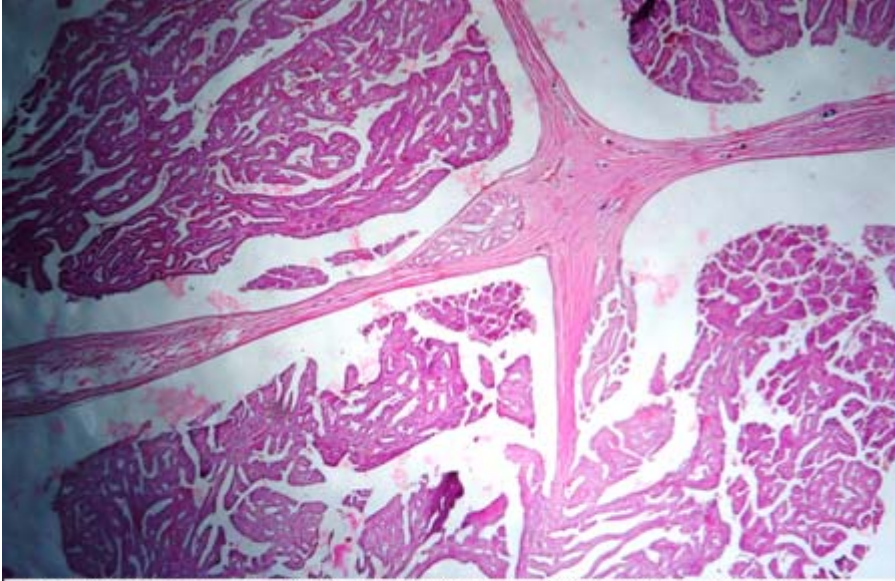


Figure 4: lower view of Intracystic papillary carcinoma. Note, multiple neoplastic masses uitrapped in multiocellular cystic spaces, the fibrovascular stak projecting from the cyst wall, cyst wall invasion by tumor H&E.

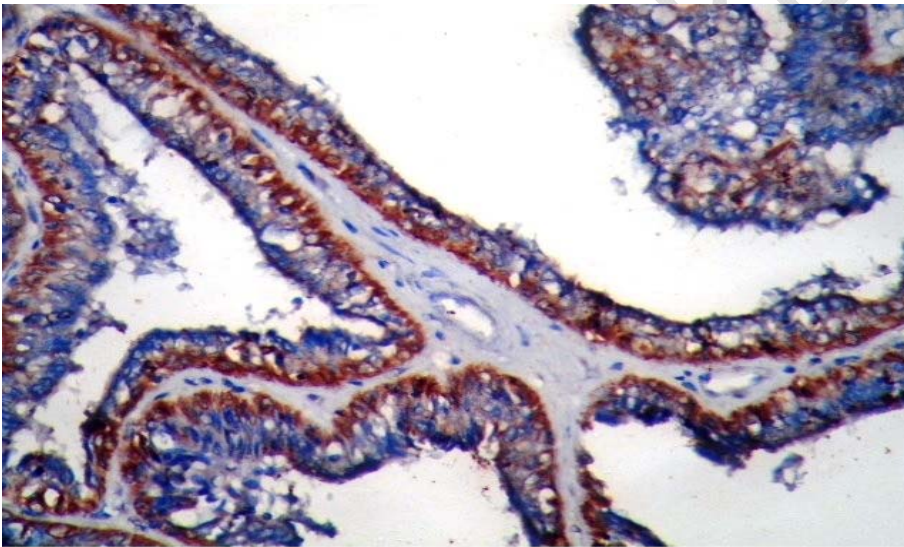


Fig 5: Udder of she camel with intracystic papillary carcinoma and positive for ck 5/6 Note, brown color, immunostain X40.

4. DISCUSSION

In the current study the masses were diagnosed as intracystic papillary carcinoma (IPC) based on the presence of papillary frond-forming pattern supported by fibrovascular stalk, which were considered as a diagnostic feature of papillary carcinoma (5; 6; 7; 8). These changes were consistent with those previously described for IPC in bitches (9); a cow (4); zoo animals (10) and in the man (6; 11; 12). The neoplastic masses were projected in cystic cavity thus giving pathognomonic feature of intracystic neoplasm, this is in line with (6 ; 11) who stated that if

intracystic component is present the tumor it should be classified as intracystic papillary carcinoma.

Based on the aforementioned morphological features and the relatively poorly differentiated plastic cells with cellular and nuclear pleomorphism and tumor invasion in cyst wall and lymphatics vessels, The tumor was described as carcinoma or malignant. This is in agreement with (13) and (2) who considered the cellular anaplasia and tumor invasion as a hallmark for malignancy. Furthermore, presences of empty or vesicular nuclei are considered as classic nuclear morphologic feature of papillary carcinoma (8; 14; 15). Other authors (16; 11), however, reported that invasion of papillary carcinoma occurs infrequently, as early small focus of stromal invasion and almost at the periphery of the lesion. (17) reported intracystic papillary carcinoma invasion in cyst wall, in vascular veins and lymphics.

Morphologically, IPC has the features of intraductal papillary carcinoma (IDPC) *in situ*. (18) stated that the differentiation between them may be arbitrary. However, (6) described IDPC *in situ* as non-invasive carcinoma extending into the small and medium sized ducts throughout the breast. On the other hand, (12) is of the opinion that if the epithelium of the papillary carcinoma has features diagnostic for intra-ductal component the tumor should be classified as intra-ductal.

Our study showed that certain lobules adjacent to the tumor revealed coexistence of both papillary fronds and apparently normal glandular tissue. It is difficult to draw any conclusion whether the papillary fronds emerging from, or infiltrating into, apparently normal udder tissue. Other investigators (19) (20) are of the opinion that adenocarcinomas (Tubular, papillary), arise from the alveolar epithelium . Furthermore, (19) suggested that papilliferous epithelium proliferations develop from the alveolar tissue within lobule, interlobular duct or teat sinus. Papillae were formed, when the ductules or alveoli become dilated and separated by thin stromal septa. When the septa break, the lobule is converted into single cyst with intraluminal papillae.

In lamb immune-histochemistry revealed the ductal epithelium to be positive for pan cytokeratin (AE1/AE3) and loose fibrovascular stroma was positive for vimentin and basal cells covering the ductal epithelium of alpha-smooth-muscle actin. Immuno-staining for the estrogen and progesterone receptors was negative may have resulted from a lack of cross reactivity to the ovine species of antibodies used. A diagnosis of mammary fibroadenoma was made based on the histological and immunohistochemical findings (21). In the mixed mammary tumor in camel, they found papillary section was moderate positive result for estrogen receptor and negative progesterone, while the fibroadenoma section was negative for both receptors (22)

5. CONCLUSIONS

To our knowledge this is the first time that the tumor cases reported in the field and found to be a problem in the udder of the camels

Intracystic papillary carcinoma IPC is described, the histopathology in one of best method for diagnoses tumor.

Further research should be tackled in order to determine the role of the neoplastic masses in the disease prevalence for better epidemiological consideration.

ACKNOWLEDGEMENTS

The Authors wish to thank the Director of Central Veterinary Research Laboratory for permission to publish this manuscript. The technical assistance of Omer. F, Nageeb. M and Omiema, H is highly appreciated. Nada Salih Osman, Senior of histopathology department in radiation and isotopes center Khartoum for their technical assistance.

ETHICAL APPROVAL

All authors hereby declare that all animals experiments have been examined and approved by the appropriate ethics committee and have therefore been performed in accordance with the ethical standards.

CONSENT

All authors declare that written informed consent was obtained from the animal for publication of this paper and accompanying images.

REFERENCES:

- (1) Munson L, Moresco A. Comparative pathology of mammary gland cancers in domestic and wild Animals. J. Breast Diseases IOS Press. 2007; 28: 7-21.
- (2) Misdrop W. Tumors of the mammary glands. In: Tumors of Domestic Animals, 4th edition, Meuten, D. J. (ed), Blackwell publisher; 2002 Pp. 575-606
- (3) Povey RC, Osborne AD. Mammary gland neoplasia in the cow. Vet Pathol.1969; 6:502-512.
- (4) Reimer JM, Sweeney RW, Saik J. Multicentric papillary cystadenoma in the udder of a cow. J. A. V. M. A. 1988; 192:1297-1298.
- (5) Stewart FW. Tumor of the breast. Atlas of tumor pathology section IX- Fascicle 34, Armed Forces Institute of pathology Washington D.C. 1950; Pp: F34-18 to F34-114.
- (6) Cater D, Orr SL, Merino MJ. Intracystic papillary carcinoma of the breast. Cancer.1983; 52: 14-19.
- (7) Soo MS, Williford ME, Walsh R, Bentley RC, Kornguth P. Papillary carcinoma of the breast, imaging findings. A.J.R. 1995; 164:321- 326.

- (8) Rosen PP. Papillary carcinoma. In: Rosen pathology, Philadelphia, Pa. Lippincott-Raven, 1997; Pp: 335-354.
- (9) Misdrop W, Colchin E, Hampe JF, Anne Jabara AG, Sandersleben V. 1972. Canine malignant mammary tumor II. Adenocarcinoma, solid carcinoma and spinal cell carcinoma. Vet. Pathol. 1972; 9: 447-470.
- (10) McAloose D, Munson L, Naydan DK. Histologic features of mammary carcinomas in zoo field treated with Melengestrol acetate (MgA) contraceptive. Vet. Pathol. 2007; 44:320-326.
- (11) Liberman J, Feng TL, Susnik B. Case 35: Intracystic papillary carcinoma with invasion. Radiology. 2001; 219:781-784.
- (12) Muttarak M, Somwangrasert A, Chaiwun B. Intracystic papillary carcinoma of the breast. Biomed. Imag. Inter. J. 2005; 1:1-3.
- (13) Cheville NF. 1976. Neoplasia In: Cell Pathology, Ed. by Cheville. N.F. Iowa State University Press, Ames 1976; Pp: 266-322.
- (14) Khan AR, Abu-Eshy SA. 1998. Variants of papillary carcinoma of the thyroid. Experience at Asir centre Hospital. J.R. Coll. Surg. Edinb. 1998; 43: 20- 25.
- (15) Karmegama K, Takami H, Miyajima K, Miura T, Hosoda Y, Ito K. 2001. Papillary carcinoma occurring with an adenomatous goiter of thyroid gland in Cowden's disease. Endocrine pathol. 2001; 12:73-76.
- (16) Sliver S, Askin F. 1997. True papillary carcinoma of the lung. A distinct clinicopathologic entity. Am. J. Surg. Pathol. 1997; 21:43-51.
- (17) Gatchell FG, Dockerty MB, Clagett OT. 1958. Intracystic carcinoma of the breast. Surg. Gynecol. Obstet. 1958; 106:347-352.
- (18) Hampe JF, Misdrop W. Tumors and dysplasia of the mammary glands. Bull. WHO. 1974; 50: 111-133.
- (19) Moulton JE. Tumor of the mammary gland. Tumors of the Domestic Animals, 2nd edition, Moulton, J. E. (ed), University of California Press. Berkeley, C. A. 1987; 350 p.
- (20) Benjamin SA, Lee AC, Sandurs WJ. Classification and behavior of canine mammary epithelium neoplasm based on life span observation in Beagles. Vet. Pathol. 1999; 36:423-436.

(21) Gulbahar MY, Guvenc T, Yarim M, Kabak YB and Sozgen Y. Mammary fibroadenoma in a lamb. J. Vet. Sci. 2007; 8: 423-425.

(22) Abeer AM, Zakia AM, Muna EA and Afaf EA. Incidence of Multiple Mammary Tumors and Fibroadenoma in Pathological Study of Udder Affections in Camel (*Camelus dromedarius*) J C T I, 2016; 4(1): 1-7.

UNDER PEER REVIEW

جمهورية السودان

جمهورية السودان

Republic of the Sudan

Ministry of Livestock

Animal Resources Research Corporation

Central Veterinary Research Laboratory
(CVRL)



وزارة الثروة الحيوانية

العامية لبحوث الثروة الحيوانية

المركزي للبحوث البيطرية

To: International Research Journal of Oncology

To whom it may concern

Subject: Ethical Clearance

This is to certify that the following authors: Abeer Abdella, Zakia Abass Khalid Mohamed and Muna Ahmed, were veterinary researchers, they did this work under title (Intracystic papillary carcinoma in the mammary gland of she-camel in Sudan) in Central Veterinary Research Laboratory, Soba Khartoum, Sudan. I can assure that they legally sampled the animal following all ethical procedures and they have run the requested laboratory test perfectly. The center administration and all authors agree to publish this article after submitting to this journal.

With best regard

A Dr. Magdi Badawi

Director / Central Veterinary Research Laboratory

Date: 7/1/2019