

QUINSY IN ADULT: CLINICAL PROFILE AND MANAGEMENT CHALLENGES IN TWO TERTIARY HOSPITALS NORTHWEST NIGERIA.

Abstract:

Purpose of the study:

Quinsy also known as Peritonsillar abscess (PTA) is a life threatened complication of acute exudative tonsillitis requiring immediate surgical intervention. We profile the clinical presentation and highlight challenges in management.

Materials and Method:

A retrospective analysis of all patients diagnosed with Quinsy at the departments of otorhinolaryngology of the Usmanu Danfodiyo University Teaching Hospital Sokoto and Specialist Hospital Birnin Kebbi between May 2014 to April 2017. These patients' clinical records were retrieved from the health record department and data extracted were analyzed using Statistical Package for the Social Sciences (SPSS) version 23.

Results:

A total of 147 adult patients had tonsillitis within the study period. Only eighteen patients with quinsy 13(72.2%) females and 5(27.8%) males with an M: F=1:2.6 were analyzed. Age range is between 18 years – 58 years with a mean age of 35.4 years. The highest incidence was 66.7% in patients within the age group 21-40 years. Odynophagia and trismus were the commonest presenting features in all the patients. Side of Quinsy involvement was on the left tonsils 12(66.7%). There was spontaneous rupture in 5(27.8%) while 13(72.2%) of patients had incision and drainage. All patients had broad-spectrum antibiotics. Interval tonsillectomy was carried out on 12(66.7%) of patients while 6(33.3%) of patients did not consent for tonsillectomy and were subsequently lost to follow up. No recurrence of symptoms or mortality recorded.

Conclusion:

Quinsy is a life threatening otorhinolaryngological emergency common amongst young female adults. Optimal management is still antibiotics therapy and drainage of abscess in our center.

Key Words: Quinsy, Peritonsillar abscess, complication, odynophagia, tonsillectomy

45
46
47
48
49
50
51
52
53
54
55
56
57
58
59
60
61
62
63
64
65
66
67
68
69
70
71
72
73
74
75

1. INTRODUCTION

Quinsy an old term also known as Peritonsillar abscess (PTA) is an accumulation of pus in the potential space between the capsule of the tonsil and the pharyngeal constrictor muscle [1,2]. It is the most common deep neck space abscess and a common cause of ENT admissions worldwide, with significant morbidities and occasionally mortality [3-5]. Complications that could arise from peritonsillar abscess are; aspiration of purulent material, extension to contiguous deep neck spaces with eventual mediastinitis, septicemia and airway obstruction [6-8]. The later can rapidly lead to death if left unattended. Quinsy affects all age groups but peaks in the second and third decades of life [9-11].

Despite its common occurrence, its aetio-pathogenesis is still a source of debate [1]. It has been thought to arise as a result of complicated acute tonsillitis (AT) [1,3,5,11]. Proponents of this theory argue that infection arising from the mucous membrane of the tonsil give rise to peritonsillitis which progress to give rise to tissue necrosis and abscess formation [1, 10,12]. This theory has however been faulted for several reasons. The epidemiology of AT is different from that of PTA in some aspects [13, 14]. The peak age of presentation of acute tonsillitis varies from that of PTA, which peaks in the second and third decade of life [10, 11]. The AT theory does not explain the microbiologic changes within the substance of the tonsil, and the fact that PTA also occurs in patients without prior AT or recurrent tonsillitis [1, 15].

The most widely accepted theory now is that of PTA arising from inflammation and subsequent suppuration of the Weber's salivary gland [1, 5,13,16]. The Weber's salivary gland is situated at the superior pole of the tonsil, and has its common duct drain through the capsule of the tonsil into the tonsillar crypts. Blockage of the duct leads to inflammation with subsequent changes that lead to suppuration of the peritonsillar tissues with accumulation of pus in the peritonsillar space [1,13]. This theory best explains the epidemiology and aetio-pathogenesis of PTA. Microbiology of PTA is polymicrobial, but in some instances may be monomicrobial [1,15,17,18]. Group A Streptococci (GAS), and *Fusobacterium Necrophorum* are common organisms isolated from aspirates of patients [1,3,18,19].

76
77
78
79
80
81
82
83
84
85
86
87
88
89
90
91
92
93
94
95
96
97
98
99
100
101
102
103
104
105

Patients with PTA may present with sore throat, odynophagia, fever, otalgia, trismus, muffled voice, halitosis or airway obstruction. Diagnosis is mostly clinical from history and classical examination findings of medialization of the tonsils, contralateral deviation of the uvula, hyperemia of the pharyngeal mucosa, inflamed jugulo-diaphragmatic lymph nodes among others [9,11]. In a few patients, PTA may be bilateral, and the classical features on examination may not be easily identified. Diagnostic difficulty may also arise in patients whose oral cavity cannot be adequately examined for various reasons [20]. In these cases, diagnosis may be aided by a CT Scan or Ultrasound scan. In settings where there are constraints of resources, a CT Scan may be a luxury, the patient may sadly not be able to afford. This places a lot of burden on the clinical skills of the attending clinician.

Medical management, Needle aspiration (NA), Incision and drainage (I&D) and Quinsy tonsillectomy can all be employed in treating PTA [8,21-24]. Over time the trend has moved from the more aggressive methods like quinsy tonsillectomy to more conservative methods such as treatment with medications alone [2,7]. Quinsy tonsillectomy is removal of the tonsils at the time of PTA [8,21]. Proponents for this treatment modality argue that, removal of the whole tonsil will lead to complete evacuation of the pus and give rapid relief of symptoms [8]. The overall hospital stay is also shortened, as patients don't need a second hospital admission for interval tonsillectomy or another drainage for PTA. Also dissection is easier, as the pus itself helps to create a plane between the tonsil and its bed. Needle Aspiration and I&D have similar response rates and outcomes, though theoretically, Needle Aspiration may have more recurrence rates than incision and drainage [8].

Medical management with antibiotics, analgesics, hydration and steroids is now being favored by many authors [2]. They argue that less invasive methods still work, and anti-inflammatory agents reduce the inflammatory process, leading to faster recovery. However patients may need to be carefully selected for this treatment modality. In environments where patients come to the hospital only as a last resort, and are easily lost when the first treatment modality doesn't appear to work, medical management may not be advocated. This study aims to present the clinical

106 profile and to highlights management challenges of peritonsillar abscess observed in two tertiary
107 hospitals in Northwestern Nigeria.

108
109
110

111 **2. METHODOLOGY**

112 This was a retrospective study of records of all patients that presented to the ENT department of
113 two tertiary hospitals (Usmanu Danfodiyo University Teaching Hospital Sokoto and Specialist
114 Hospital Birnin Kebbi) in Northwestern Nigeria with peritonsillar abscess from May 2014 to
115 April 2017. Medical records of patients who were clinically diagnosed with peritonsillar abscess
116 presenting to the Centres during the period under review were retrieved, and relevant data
117 extracted. Data was analyzed using Statistical Package for the Social Sciences (SPSS) version 23

118

119 **3. RESULTS**

120 **3.1 Demographics**

121 A total number of 147 Adult patients with tonsillitis were seen within the study period of which
122 18 patients with quinsy were recruited for this study. Out of this, 13 (72.2%) were females, while
123 5 (27.8%) were males, with a Male to Female ratio of 1: 2.6. The ages of patients ranged from 18
124 to 58 years, with a mean age of 35.4 years. See [Table 1].

125

126 Table 1: Age distribution of patients

S/No	Age Group (Years)	Females	Males	Total (%)
1	0 – 20	1	-	1 (5.6)
2	21 – 40	9	3	12 (66.7)
3	41 – 60	3	2	5 (27.7)
4	Total	13	5	18 (100)

127

128 **3.2 Clinical Presentation**

129 All patients presented with Odynophagia, followed by Trismus in 83.3% of patients. See table 2.
130 Thirteen patients (72.2%) presented with a prior history of tonsillitis, while 5 (27.8%) patients
131 did not have a prior history of tonsillitis.

132
133
134
135
136
137

Table 2: Symptoms patients presented with.

S/No	Symptoms	Number of patients	Percentage
1	Odynophagia	18	100.0
2	Dysphagia	10	55.6
3	Muffled voice	8	44.4
4	Fever	7	38.9
5	Headache	9	50.0
6	Neck Pain	12	66.7
7	Trismus	15	83.3
8	Epigastric pain	5	27.8

138
139
140
141

All patients presented with unilateral PTA, 5 of them came at an advanced stage, with already ruptured abscesses. The left sided PTA accounted for 66.7% of cases. See [Table 3].

Table 3: Side of involvement

S/No	Gender	Right	Left
1	Females	2	11
2	Males	4	1
Total (%)		6 (33.3)	12 (66.7)

142
143
144
145
146
147
148
149

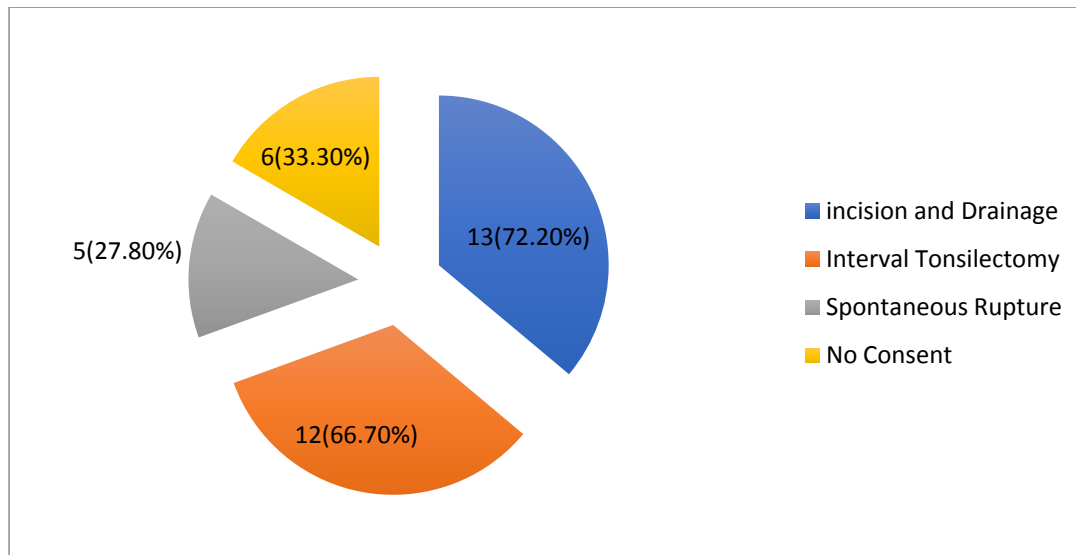
3.3 Diagnosis and Treatment

Diagnosis in all patients was clinical. The 5 patients who presented with ruptured PTA were managed medically with antibiotics, analgesics, mouth gaggles, and steroids. Patients were given parenteral antibiotics (Ceftriaxone and Metronidazole) for 48 to 72 hours and thereafter converted to oral Augmentin (Amoxicillin/Clavulanic acid) and Metronidazole. The remaining 13 patients had a test needle aspiration to confirm the diagnosis of PTA. These patients had Incision and drainage done and were thereafter commenced on medical treatment as above. All

150 patients were thereafter scheduled for interval tonsillectomy and 12(66.7%) had the surgery
151 while 6(33.3%) did not consent for tonsillectomy and were however lost to follow up. The over
152 all mean duration of hospitalization was 4.8days (Range 1-14days). No mortality recorded in this
153 study.

154

155



156

157

158 **FIGURE I: Surgical treatment and spontaneous drainage of PTA.**

159

160

161 **4. DISCUSSION**

162 A total number of 18 patients were observed in our Centre during the 3 years studied. This is not
163 surprising as the health seeking behavior of patients in our environment is poor. The fact that
164 5(27.8%) of the patients had to wait for the abscess to rupture before presenting to the hospital
165 further buttresses this fact. Most patients see orthodox healthcare as a last resort, and even if they
166 feel constraint to take orthodox drugs, they will rather get those drugs over the counter than
167 come to the hospital to see a doctor let alone an ENT Surgeon. The increase rate of self-
168 medication, treatment from private clinics may be attributed to delay in presentation and the
169 small size of patients in this study. This may be the reason all patients were on antibiotics before
170 presenting to the hospital. It is likely that some cases of PTA got resolved with such antibiotics
171 therefore patients may not see the need for further care in the hospital. Several factors are

172 responsible for this poor health seeking behavior especially in developing countries, most
173 notable is lack of resources to fund healthcare. This is so because most patients in our
174 environments pay for healthcare out of pocket, and for the few that have health insurance, the
175 often-difficult bureaucratic processes in accessing healthcare discourages them. These poses a
176 great challenge to the otolaryngologist in the management of this condition.

177 The mean age in this study was 35.4 years. This agrees with the fact that PTA is common among
178 Adolescents and young adults [9, 11]. Risberg and colleagues in a retrospective review over
179 three years in Sweden also had similar mean age (31.2 years) [10]. Other authors reported a
180 similar mean age [11, 25]. We had no child that presented with PTA among our patients during
181 the study period. Children also present with PTA, but the incidence among them is low, with
182 older children being the majority [4, 26]. Majority of our patients (72.2%) were females. This is
183 at variance with what is commonly observed [8, 9,11]. Other studies reported no significant
184 difference in the prevalence among males or females [10, 25]. However, Segal and colleagues in
185 a study of PTA among 126 children in Jerusalem observed a female preponderance of 56.4%.

186 All patients in this study presented with odynophagia. The second most common presentation
187 was trismus. Fever was seen among 38.9% of the patients. This may not be unconnected with the
188 prior use of antibiotics among the patients in this study. Souza and colleagues reported sore
189 throat as their most common symptom [9]. Odynophagia is sometimes used interchangeably with
190 sore throat, though they are distinct entities. Fever is a more common symptom among younger
191 children [4, 26].

192 Five patients (27.8%) did not have a prior history of tonsillitis in this study. This is similar to
193 findings by Marom and colleagues [25]. It would have been expected that if PTA arises as a
194 complication of AT all our patient should have had a prior history of AT. Only 36% of patients
195 had previous tonsillar infection among a pediatric population [26]. Mazor and colleagues in a
196 retrospective review of PTA cases treated at a regional hospital in Radom Poland, among 111
197 patients reported a previous history of tonsillitis among 35.5% of their patients [11]. We
198 observed that 66.7% of patients had left sided PTA. Other authors observed no difference
199 between either sides [25,26].

200 Five of our patients presented with spontaneous rupture of PTA a life threatening complication.
201 There is a high risk of aspiration, lung abscess, aspiration pneumonia and deep neck space
202 infection associated with spontaneous rupture of PTA, however none of our patient develop any

203 of these complications. No further drainage was required for these patients. They were
204 commenced on antibiotics, mouth gaggles for toileting and other medical treatment.

205 It is a well-established fact that broad-spectrum antibiotics show advantage over single
206 antibiotics in the management of PTA [27]. Our choice of antibiotics is Intravenous Ceftriaxone
207 and Metronidazole for the first 48 to 72 hours. This is because of the polymicrobial nature of
208 aspirates in our environment, and the good tissue penetration of Ceftriaxone [1]. Other authors
209 prefer to use Penicillins as their first line [23]. We rather use Ceftriaxone because we are
210 concerned about immunologic complications of GAS, and will want a drug that can clear it as
211 much as possible [1,3,15,17,18]. Immunologic complications of GAS are not much of a problem
212 in some developed countries as it is in our environment [23]. Augmentin is used by some authors
213 with caution in AT because Infectious mononucleosis is a differential of AT. Amoxicillin can
214 give rise to maculopapular rash in patients with infectious mononucleosis [3]. We routinely use
215 Augmentin for AT and PTA patients when converting them to oral medications and we have not
216 recorded any case of rash. Marom and colleagues also reported the routine use of
217 Amoxicillin/Clavulanic acid for their patients [25]. Some in the management of PTA also
218 advocates Clindamycin, Ceftriaxone combination [8].

219 The choice of any surgical technique is still debatable as no consensus on the available options.
220 Although many authors [25,27] reports the choice of needle aspiration as being less invasive,
221 cost effective and convenient, our patients with unruptured PTA, had I & D, and thereafter were
222 scheduled for interval tonsillectomy (**figure 1**). We adopted this method because of the
223 peculiarities of our environment one of which is the need for repeat needle aspiration due to
224 recurrence that mostly results from noncompliance to appropriate Medical treatment. Knowing
225 that patients may not opt to return to the hospital when they have recurrence we prefer to offer
226 them I&D, which is associated with less recurrence. Though quinsy tonsillectomy has been
227 shown to be safe [21], and will be more apt in this circumstance, majority of our patients had
228 interval tonsillectomy, which is usually 4-6 weeks after incision and drainage. We therefore
229 advocates the need for proper health education on the life threatening complications associated
230 with PTA and the choice of interval tonsillectomy in averting this dangers.

231

232

233

234

235

236 **5. CONCLUSION**

237 This study observed a lower number of PTA patients as compared to other studies. We also
238 observed a female preponderance among our patients, with a mean age of 35.4 years.
239 Odynophagia followed by Trismus were the most common symptom. Spontaneous rupture of
240 PTA was the only fatal complication reported in this study. All patients were clinically
241 diagnosed and subsequently managed as in-patient with antibiotics, incision and drainage in
242 72.2% of patients and interval tonsillectomy in 66.7%.

243 We therefore recommends the need for a multicenter research to determine the actual pattern of
244 PTA in our environment; adequate funding of health care institutions for the provision of
245 affordable, accessible services and the need for proper health education on the life threatening
246 complications associated with PTA.

247 **COMPETING INTEREST**

248 Authors have declared that no competing interests exist.

249

250 **REFERENCES**

251

- 252 1. Powell E, Powell J, Samuel J, Wilson J. A review of the pathogenesis of adult
253 peritonsillar abscess: time for a re-evaluation. *Journal Of Antimicrobial Chemotherapy*.
254 2013; 68(9): 1941-1950. doi: 10.1093/jac/dkt128
- 255 2. Battaglia A, Burchette R, Hussman J, Silver MA, Martin P, Bernstein P. Comparison of
256 Medical Therapy Alone to Medical Therapy with Surgical Treatment of Peritonsillar
257 Abscess. *Otolaryngology–Head and Neck Surgery*. 2018; 158(2): 280–286.
- 258 3. Powell J, Wilson J. An evidence-based review of peritonsillar abscess. *Clinical*
259 *Otolaryngology*. 2012; 37(2): 136-145. doi: 10.1111/j.1749-4486.2012.02452.x
- 260 4. Baldassari C, K. Shah R. Pediatric Peritonsillar Abscess: An Overview. *Infectious*
261 *Disorders - Drug Targets*. 2012;12(4):277-280.
- 262 5. Klug TE, Rusan M, Fuursted K, Ovesen T. Peritonsillar Abscess: Complication of Acute
263 Tonsillitis or Weber’s Glands Infection? *Otolaryngology–Head and Neck Surgery*.
264 2016; 155(2): 199–207.

- 265 6. Johnson R, Stewart M, Wright C. An Evidence-Based Review of the Treatment of
266 Peritonsillar Abscess. *Otolaryngology–Head and Neck Surgery*. 2003;128(3):332-343.
- 267 7. Chang BA, Thamboo A, Burton MJ, Diamond C, Nunez DA. Needle aspiration versus
268 incision and drainage for the treatment of peritonsillar abscess. *Cochrane Database of*
269 *Systematic Reviews* 2016, Issue 12. Art. No.: CD006287. DOI:
270 10.1002/14651858.CD006287.pub4.
- 271 8. Albertz N, Nazar G. Peritonsillar abscess: Treatment with immediate tonsillectomy – 10
272 years of experience. *Acta Oto-Laryngologica*. 2012;132(10):1102-1107.
- 273 9. Souza D, Cabrera D, Gilani W, Campbell R, Carlson M, Lohse C et al. Comparison of
274 medical versus surgical management of peritonsillar abscess: A retrospective
275 observational study. *The Laryngoscope*. 2016;126(7):1529-1534.
- 276 10. Risberg S, Engfeldt P, Hugosson S. Incidence of peritonsillar abscess and relationship to
277 age and gender: Retrospective study. *Scandinavian Journal of Infectious Diseases*.
278 2008;40(10):792-796.
- 279 11. Mazur E, Czerwińska E, Korona-Głowniak I, Grochowalska A, Koziół-Montewka M.
280 Epidemiology, clinical history and microbiology of peritonsillar abscess. *European*
281 *Journal of Clinical Microbiology & Infectious Diseases*. 2014;34(3):549-554.
- 282 12. Ellis M. *Infectious Diseases of the Respiratory Tract*. Cambridge, UK: Cambridge
283 University Press, 1998.
- 284 13. Passy V. Pathogenesis of peritonsillar abscess. *Laryngoscope* 1994; 104:
285 185–90.
- 286 14. Farmer S, Khatwa M, Zeitoun H. Peritonsillar abscess after
287 tonsillectomy: a review of the literature. *Ann R Coll Surg Engl* 2011; 93:
288 353–7.
- 289 15. Gavriel H, Vaiman M, Kessler A, Eviatar E. Microbiology of Peritonsillar Abscess as an
290 Indication for Tonsillectomy. *Medicine*. 2008;87(1):33-36.
- 291 16. Brook I. Microbiology and management of peritonsillar, retropharyngeal, and
292 parapharyngeal abscesses. *J Oral Maxillofac Surg* 2004; 62: 1545–50.
- 293 17. Gavriel H, Lazarovitch T, Pomortsev A, Eviatar E. Variations in the microbiology of
294 peritonsillar abscess. *European Journal of Clinical Microbiology & Infectious Diseases*.
295 2008;28(1):27-31.

- 296 18. Klug T, Henriksen J, Fuursted K et al. Significant pathogens in peritonsillar abscesses.
297 Eur J Clin Microbiol Infect Dis 2011; 30: 619–27.
- 298 19. Rusan M, Klug T, Ovesen T. An overview of the microbiology of acute ear, nose and
299 throat infections requiring hospitalization. Eur J Clin Microbiol Infect Dis 2009; 28: 243–
300 51.
- 301 20. Edinger JT, Hilal EY, Dastur KJ. Bilateral peritonsillar abscesses: a challenging
302 diagnosis. *Ear, Nose and Throat Journal* 2007 86(3): 162–163.
- 303 21. Windfuhr J, Zurawski A. Peritonsillar abscess: remember to always think twice.
304 European Archives of Oto-Rhino-Laryngology. 2015;273(5):1269-1281.
- 305
- 306 22. Wikstén J, Blomgren K, Eriksson T, Gultfred L, Bratt M, Pitkäranta A. Variations in
307 treatment of peritonsillar abscess in four Nordic countries. *Acta Oto-Laryngologica*.
308 2014;134(8):813-817.
- 309 23. Visvanathan V, Nix P. National UK survey of antibiotics prescribed for acute tonsillitis
310 and peritonsillar abscess. *The Journal of Laryngology & Otology*. 2009;124(4):420-423.
- 311 24. Ozbek C, Aygenc E, Tuna EU, Selcuk A, Ozdem C. Use of steroids in the treatment of
312 peritonsillar abscess. *The Journal of Laryngology & Otology*. Cambridge University
313 Press; 2004;118(6):439–42.
- 314 25. Marom, T., Roth, Y., Itskoviz, D., & Cinamon, U. (2008). Changing Trends of
315 Peritonsillar Abscess. *Otolaryngology–Head and Neck Surgery*, 139(2_suppl), P33–P33.
- 316 26. Segal N, El-Saied S, Puterman M. Peritonsillar abscess in children in the southern district
317 of Israel. *International Journal of Pediatric Otorhinolaryngology*. 2009;73(8):1148-1150.
- 318 27. Shaul C, Koslowsky B, Rodriguez M, Schwarz Y, Muahnna N, Peleg U et al. Is Needle
319 Aspiration for Peritonsillar Abscess Still as Good as We Think? A Long-term Follow-up.
320 *Annals of Otology, Rhinology & Laryngology*. 2014;124(4):299-304.