

# **Studies on the effects of Fanta additives and simultaneous consumption of Fanta with ascorbic acid on histological parameters of male mice**

## Abstract

Sodium benzoate and ascorbic acid are the most significant additives in Fanta soft drink. The effect of consuming these additives and simultaneous consumption of Fanta with ascorbic acid were investigated to understand histopathological alterations in both liver cells and testis. Experimental mice were grouped into 7 different sets and five of the groups were administered 4 mg/kg body weight of the treatments, while the other two groups served as normal and vehicle control. The histological results reveal presence of activated Kupffer cells, sinusoidal widening and cytoplasmic vacuolation in the liver of mice exposed to Fanta, sodium benzoate and sodium benzoate with ascorbic acid, while in addition to these, there were severe cellular and granular casts in group administered Fanta with ascorbic acid. Severe cellular casts and granular cast is an indication of hepatic diseases. Fanta, sodium benzoate, ascorbic acid and sodium benzoate with ascorbic acid did not alter the histopathology of the testis, but simultaneous consumption of Fanta with ascorbic acid might prevent the formation of new stem cells and may hinder them from dividing to specialized cells.

Key words: Sodium benzoate, Ascorbic Acid, Fanta, Histological Alteration, Stem Cells, Vacuolation.

## Introduction

Food is any substance that is taken for the purpose of providing nutritional support for the body or pleasure (Francis, 2000). It is made up of any of the following in varied ratios;

carbohydrates, fats, vitamins, proteins, minerals and roughages. Foods are eaten to maintain life and stimulate growth (Abdulmumeen *et al.*, 2012). To preserve the integrity of food, additives are added. Therefore, food additives are substances added to preserve flavour, or to enhance food taste and appearance, during any of the following stages; production, packaging, transportation and/or storage (Kunkel and Barbara, 2004). Examples of the commonly used additives are monosodium glutamate (MSG), white sugar, benzoic acid (and its salts, such as sodium benzoate), ascorbic acid (vitamin C), aluminium silicate, butylated hydroxyl toluene (BHT), etc. (Abdulmumeen *et al.*, 2012). Sodium benzoate is widely used as a preservative in pickles, sauces, fruit juices, pharmaceuticals, and therapeutic regimens (CICAD, 2005). It is also used as antimicrobial agents in edible coatings (CICAD, 2005). The acceptable daily limit intake of benzoic acid and its salts ranges between 0-5 mg/kg body weight (EFSA, 2016). Ascorbic acid is an important antioxidant with multiple cellular functions. It is present in many fruits and vegetables and it is also synthesised from glucose in the liver of many mammalian species, allowing the maintenance of physiological levels.

Since 2006, the European Commission and Member States had become aware of the potential formation of benzene under certain conditions in soft drinks from the reaction of benzoic acid and other ingredients (EFSA, 2016). When benzoic acid or its salts and ascorbic acid are used simultaneously, considerations should be given to the storage of the soft drinks and the food contact materials to minimise the formation of benzene in beverages (EFSA, 2016). Further monitoring of the formation of benzene was encouraged by European Commission and Member States (EFSA, 2016).

Fanta is a brand of fruit-flavoured carbonated drinks produced by The Coca-Cola Company and marketed globally. It is the second oldest brand and is enjoyed more than 130 million times every day around the world (Coca-Cola, 2017). Recently, simultaneous consumption of this soft drink with ascorbic acid has been implicated to be poisonous and able to cause death

(Sahara Reporters, 2017, Abuad news, 2017). However, little is known about its pathological effects on liver and testis. Since liver is the major organ responsible for the metabolism and detoxication of a number of xenobiotics in animal and human, this study was therefore conducted to investigate the histopathological effect of simultaneous consumption of Fanta with ascorbic acid on liver. The histology of the testis will also be investigated to ascertain whether they are able to affect the germ cell, since there is no concrete information on the influence of sodium benzoate on reproductive organs. Also, there is dearth of information as regards the effects of ascorbic acid, Fanta and simultaneous consumptions of Fanta with ascorbic acid on testis. Hence, we need to carry out this kind of research to provide baseline information on their effects.

#### Materials and Methods

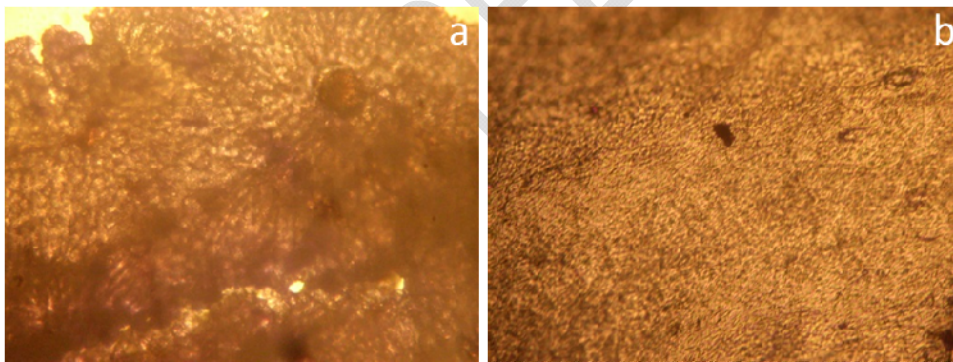
The experimental mice were purchased from the Department of Animal and Environmental Biology of Adekunle Ajasin University and acclimatized for two weeks prior to the experiment. They were divided into seven (7) groups; groups 1 and 2 served as normal and vehicle controls, respectively, while groups 3,4,5,6 and 7 were administered 4 mg/kg ascorbic acid (AA), sodium benzoate (SB), Fanta (FA), ascorbic acid with Fanta (AAF), and ascorbic acid with sodium benzoate (AAS), respectively for five (5) non-consecutive days and were allowed to feed on pelleted feed for 25 days. Group 1 were administered water without using oral gavage (WA) while Group 2 received water using oral gavage (WO) in order to access if oral gavage can induce any form of stress on the animals by altering the histological pattern of the liver. The mice were bred and maintained under allowed experimental conditions (approved by Department of Animal and Environmental Biology, AAUA) and in accordance with all known standards animal care.

## HISTOPATHOLOGICAL EXAMINATION OF LIVER AND TESTES

The mice were dissected and organs of interest (liver and right testes) were isolated. The tissues collected from the experimental mice were fixed in 10% formal saline and the tissues were decalcified, trimmed, then embedded in paraffin wax. A manual microtome model Hedee model no KD-202C was used to cut into thin section. The sections cut (tissue sections of 3–5 $\mu$ m thick), went through deparaffination, rehydration and stained with Haematoxylin and Eosin (H–E), then mounted in neutral DPX medium for morphological evaluation before microscopic examination at 200x

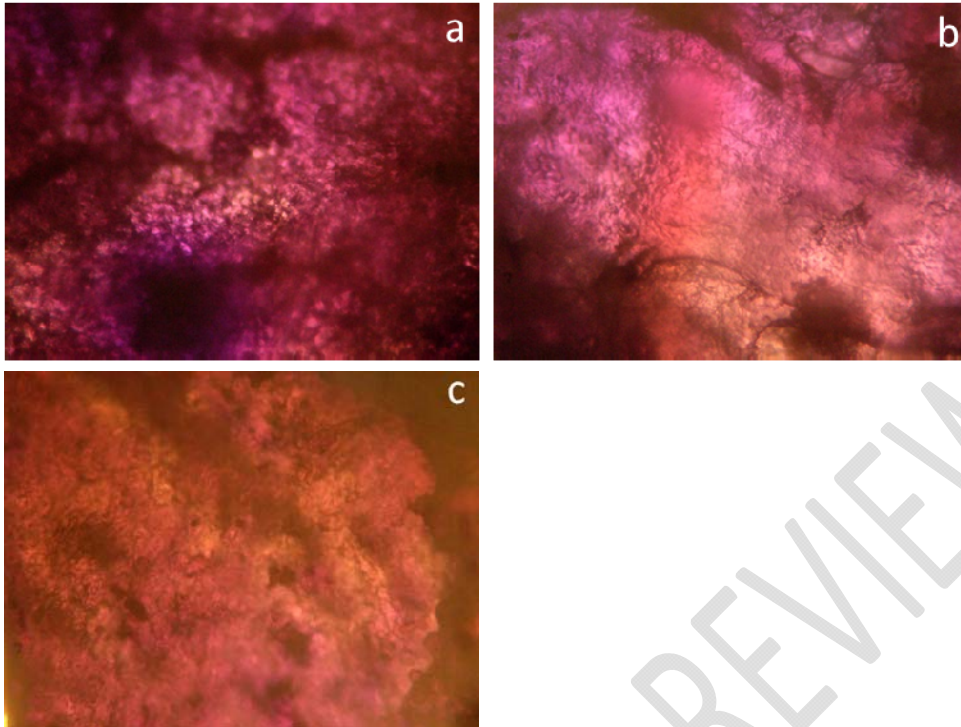
### Results

The histopathological examination of liver of the experimental mice administered with different treatment in order to understand the influence of simultaneous consumption of fanta and ascorbic acid were presented in Figures 1 to 6 below.



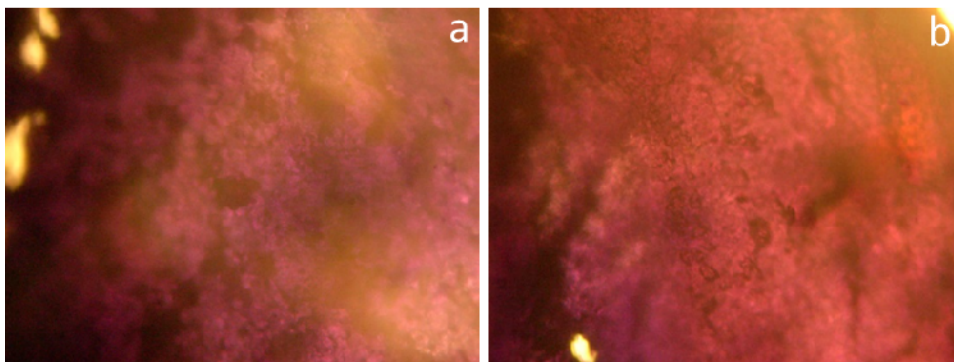
*Figure 1: Photomicrograph of mice liver, (a) administered water without oral gavage (WA) (b) administered water using oral gavage (WO)*

Figures 1a and b show the presence of normal central vein and hepatocytes. There are no observable changes in the histological pattern of the liver. The lack of disruption of hepatic cords, even sizes of nucleus in hepatocytes (6–7  $\mu$ ) and normal central vein attest that no changes occur in the liver of the mice.



*Figure 2: Photomicrograph of liver of a mice administered (a) ascorbic acid (AA) (b) Fanta (FA) (c) sodium benzoate (SB)*

Few cellular and granular casts were evident in Figure 2a. In both Figures b and c, the presence of activated Kupffer cells, sinusoidal widening and cytoplasmic vacuolation were observed. The similarity in the observation from the two treatments might be related to the fact that sodium benzoate is a preservative agent in Fanta, and might be the cause of the changes that was observed in the liver of mice administered Fanta.

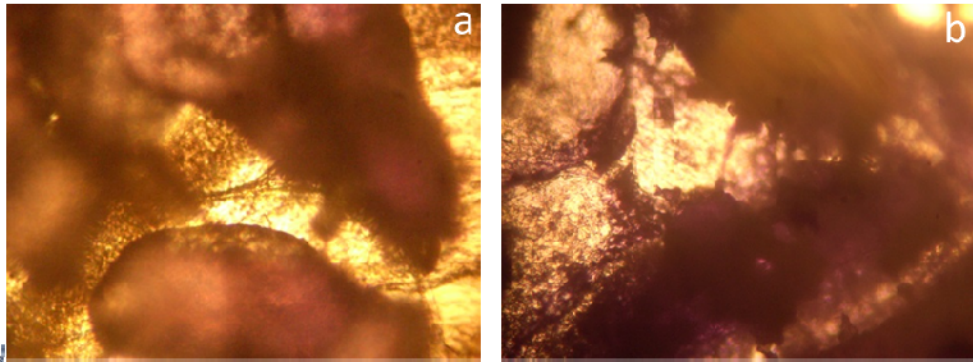


*Figure 3: Photomicrograph of liver of mice treated with mixture of ascorbic acid with (a) Fanta (b) sodium benzoate*

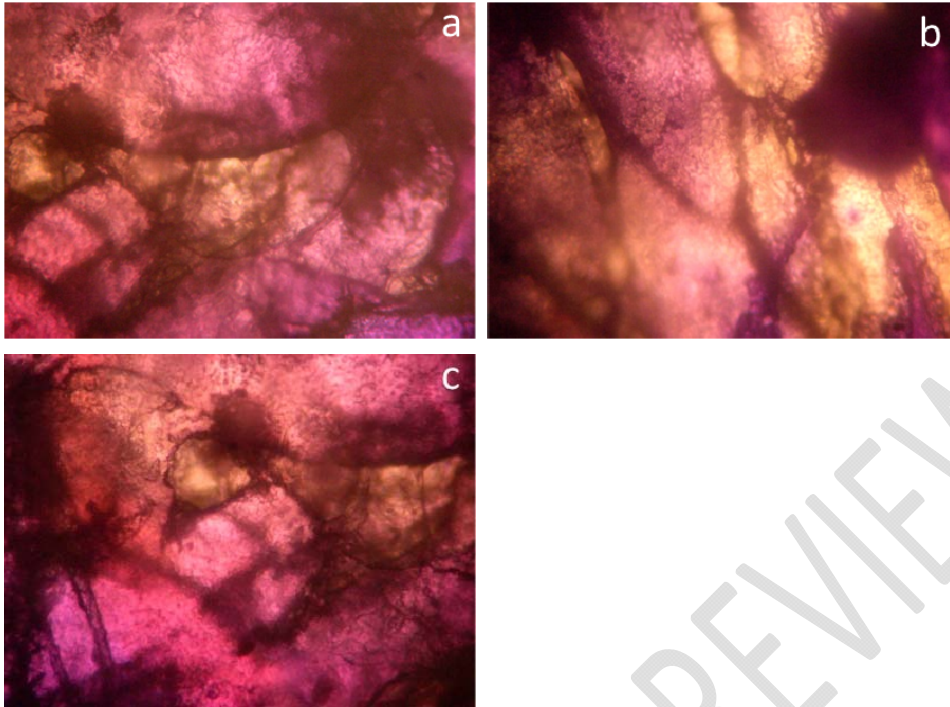
The photomicrograph in Figure 3a shows severe cellular cast, granular cast, activated Kupffer cells, sinusoidal widening and cytoplasmic vacuolation. The photomicrograph of the liver of the experimental mice administered with ascorbic acid and sodium benzoate is shown in Figure 3b. The presence of activated Kupffer cells, sinusoidal widening and cytoplasmic vacuolation were also observed. This observation could be as a result of the presence of ascorbic acid in Fanta originally, hence further addition gave liver more work to do and resulted in its damage. It could also be because the addition of ascorbic acid to the Fanta caused the sodium benzoate (in Fanta) to shift the reaction to production of benzoic acid and later benzene, which lead to severe cellular and granular cast.

The results from the photomicrograph of testis of experimental mice administered; water without oral gavage, water with oral gavage, sodium benzoate, Fanta, ascorbic acid with Fanta and sodium benzoate with ascorbic acid are shown in Figures 4a, 4b, 5a, 5b, 5c, 6a and 6b, respectively. All the photomicrographs show presence of undifferentiated stem cells, primary spermatocyte, secondary spermatocyte and spermatids which are embedded within the cytoplasm of large nurse attached to the basal lamina at the tubular capsule. This is an indication that all the treatments have no effect on the testis. However, Figure 6b shows a

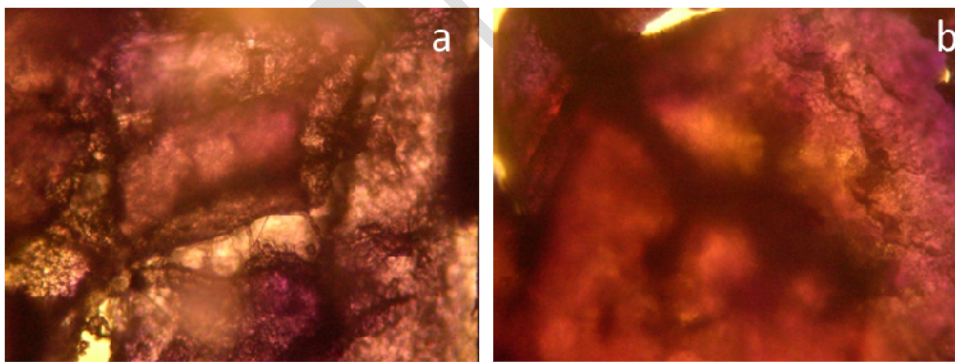
slight difference in the photomicrograph observation, as there are severe undifferentiated stem cells, primary spermatocyte, secondary spermatocyte and spermatids which are embedded within the cytoplasm of large nurse attached to the basal lamina at the tubular capsule.



*Figure 4: Photomicrograph of testis of mice administered (a) no treatment (b) water*



*Figure 5: Photomicrograph of testis of mice administered (a) sodium benzoate, (b) Fanta, (c) ascorbic acid*



*Figure 6: Photomicrograph of testis of mice administered ascorbic acid and (a) sodium benzoate (b) Fanta*

## Discussion

Food additives have been gaining importance in modern food technology because of the growing demands for processed food. Benzoic acid and its salts are among the most common preservatives used for inhibiting microbial growth because of the cost-benefit ratio (Theron and Lues, 2010). Benzoates help to control the growth of some bacteria, filamentous fungi, and yeasts, thereby preventing product deterioration and the growth of pathogenic species (Bilau et al., 2008). Sodium, potassium, and calcium benzoates and ascorbic acid usually occur naturally in foods and can also be added as food additives. Ascorbic acid are usually added to processed foods as supplementary nutrient or antioxidants. The presence of benzoates and ascorbic acid as food additives have been implicated to cause the production of Benzene which is a known carcinogenic agent (EFSA, 2016; CICAD, 2005). According to Gardner and Lawrence (1993), hydroxyl radicals generated by the reduction of oxygen or hydrogen peroxide by ascorbic acid, catalyzed by metal ions, could decarboxylate benzoic acid through a pH-dependent reaction, resulting in the benzene formation in foods and beverages.

The important roles performed by the liver, not only in the storage and release of nutrients, but also in the neutralization and elimination of a variety of toxic substances (Baratta et al., 2009), have prompted investigations of Fanta additives and simultaneous consumption of Fanta with ascorbic acid on liver. The lack of disruption of hepatic cords, even sizes of nucleus in hepatocytes and normal central vein for the control and vehicle groups attest that no changes occur in the mice liver. This lack of changes in the liver may be because no treatment was administered on the mice. Hence, the liver from the control and vehicle groups could serve as a very good reference point. Furthermore, the result of those administered water with oral gavage reveals that oral gavage is not a liver stressor.

The liver histopathological results of mice exposed to Fanta, sodium benzoate, Fanta with ascorbic acid and sodium benzoate with ascorbic acid revealed the presence of activated Kupffer cells, sinusoidal widening and cytoplasmic vacuolation. The similarity in the observation from these treatments might be related to the fact that sodium benzoate is a preservative agent in Fanta, and might be the cause of the changes that was observed in the liver of mice administered with Fanta. This agreed with the findings of Oyewole *et al.* (2012) that reported that Sodium benzoate mediated hepatorenal toxicity in Wister rat.

Cytoplasmic vacuolation is a morphological phenomenon observed in mammalian cells after exposure to bacteria or viral pathogens as well as to various natural and artificial low molecular weight compounds (Shubin *et al.*, 2016). Vacuolation of cytoplasm is regarded as ballooning degeneration, which is a kind of cellular defensive mechanism against injurious substances (Abdel Hameed, 2004). The vacuoles are usually responsible for collecting injurious element and preventing them from interfering with the biological activities of these cells (cytoplasm) (Cheville, 2009). During abnormal micropinocytosis in methuosis, micropinocytosis does not fuse with other organelles of the endocytic pathway and do not recirculate to the plasma membrane, but rather accumulate in the cytoplasm, fuse with each other, and form vacuoles (Shubin *et al.*, 2016). Cytoplasmic vacuolation was evident in liver of all the mice administered with treatment except those administered ascorbic acid (as shown in Figures 2 and 3). This could be an indication that the administered substances were treated by the liver as a foreign body, which is capable of inducing cytoplasmic death. This agreed with the report of Zhang and Wang (1984) that cytoplasmic vacuolation is a consequence of disturbance induced by xenobiotics. Eweka (2007) also observed liver tissue impairment and vacuolations when rats were administered monosodium glutamate with varied concentration (3-60 mg). Vacuolations of hepatocytes were pronounced around the central vein in the mice injected with MSG (Bhattacharya *et al.*, 2011). This confirmed that

cytoplasm treated all the treatments (except ascorbic acid) as xenobiotics, which are capable of terminating its life.

Liver dystrophy is mainly due to damage of main cell macromolecules (lipids, proteins, DNA) (Mohamed and Mohamed, 2009), which result from oxidative stress induced by xenobiotics (such as aflatoxins, sodium benzoate, benzoic acid, benzene, ascorbic acid, and even Fanta), a mechanism that could provoke oxidative damages in liver cells. Furthermore, accumulation of metal (such as Ca, Na, etc.) in hepatocytes provokes mitochondrial dysfunction and reduced rate of adenosine triphosphate synthesis, resulting in morphological disturbances of liver structure (Valchey *et al.*, 2016). Critical observation of Figures 2 and 3 shows that histological feature of hepatic parenchyma was variable in different parts and that these changes were not uniform. According to Valchey *et al.* (2016), histopathological changes in liver parenchyma might be due to the accumulations of xenobiotics in hepatocytes following impaired lipid metabolism since liver is the target for detoxification of noxious substances.

Sinusoids are low pressure vascular channels that receive blood from terminal branches of the hepatic artery and portal vein at the periphery of lobes and deliver it into central veins. They are lined with endothelial cells and flanked by plates of hepatocytes. Sinusoids are populated by numerous Kupffer cells. Sinusoidal widening is a characteristic of hepatic sinusoidal dilation (HSD) (Saadoun *et al.*, 2004). HSD is usually found in the vicinity of hepatic tumours, heart failure, hepatic venous outflow block, veno-occlusive disease, granulomatous disorders, infectious, or infiltration of sinusoids by several of benign or malignant cells (Saadoun *et al.*, 2004). Hepatic sinusoidal dilatation is common in the clinicopathological entity non-cirrhotic intrahepatic portal hypertension, which consists of various types of architectural alterations (Saadoun *et al.*, 2004). These architectural alterations have been

related to several causal factors, including xenobiotics (Saadoun *et al.*, 2004). The present study reveals that sodium benzoate is the major cause of sinusoidal widening. This could be as a result of dissociation of sodium benzoate to benzoic acid and sodium ion. This benzoic acid can under stomach condition convert to benzene and carbon (IV) oxide. Benzene, even at little concentration, is capable of causing hepatic tumours since benzene is carcinogenic. According to McNeal *et al.* (1993), the concentration of benzene in foods with benzoates and ascorbates was high (varied from 1 to 38 ng/g) when compared with those without added benzoates (less than 2 ng/g of benzene). Furthermore, it has been reported that there is tendency for the production of benzene in food and beverages when the concentration of benzoic acid is the same with that of ascorbic acid, but when the concentration of the latter is higher, there will be no production of benzene (Vania *et al.* 2015). Since there were sinusoidal widening in all cases where sodium benzoate was administered, then there is possibility of traces of benzene been formed.

Variety of non-parenchymal resident cells including a population of macrophages is called Kupffer cells (Baratta *et al.*, 2009). Kupffer cells play a critical role as first line of defence against particulates and immunoreactive substances. Activation of Kupffer cell is essential to the response of liver to infection or injury. Presence of activated Kupffer cell in mice exposed to various treatments except control groups and those administered ascorbic acid, is an indication that the treatments act as xenobiotics due to the presence of sodium benzoate. Inflammatory activation of Kupffer cells, the resident macrophages in liver, has been implicated in both obesity-induced insulin resistance and fatty liver disease (Odegaard *et al.*, 2008). Inflammatory activation of Kupffer cells by lipopolysaccharide (LPS) promotes hepatotoxicity in obese mice (Odegaard *et al.*, 2008; Li and Diehl, 2003). There appear to be great therapeutic potential of activated Kupffer cells, but their functions in metabolic disease is unclear (Odegaard *et al.*, 2008). From this present study, it can be deduced that

consumption of sodium benzoic is able to initiate an inflammatory response of Kupffer cell and if not controlled, can lead to liver/hepatic disease.

Cellular casts may be made of white blood cells, red blood cells, kidney cells, or other substances such as fat or protein. Granular casts are acellular casts that have a granular appearance. These casts result either from the degeneration of cellular casts, or direct aggregation of plasma proteins or immunoglobulin light chains. They are associated with renal and viral disease, and exercise, when seen in urine, during urinalysis. Presence of few cellular cast and granular cast is not an indication of any disorder, but the presence of severe cellular cast and granular casts in experimental mice administered Fanta with ascorbic acid (Figure 3a) suggest chronic hepatic disease.

The mice environment, as well as the administration method has no effect on testis morphology as shown in Figure 4. The observation in Figures 5 and 6 show that Fanta, sodium benzoate, and ascorbic acid did not have effect on the testis of the experimental mice, however, Figure 6b shows severe undifferentiated stem cells. This is an indication that simultaneous consumption of Fanta with ascorbic acid damages the stem cells, which may prevent them from dividing into a specialized cells or hinder them from producing more stem cells

The results from testes histology revealed that SB either taken directly or as preservative in Fanta did not alter the structure of the testes and that there were production of several undifferentiated stem cells together with different stages or phases of spermatocytes formation. This is an indication these treatments do not have any negative effects on the production of sperm cells and therefore may not be genotoxic at low concentration. This agreed with the report of Nair (2001) that SB has no toxic effect on reproduction. Sasaki *et al.* (2002) worked on 39 currently used food additives on different 8 mouse organs using

Comet assay and reported that SB (2000 mg/kg) in mice organs did not create DNA damage at a statistically significant level.

## Conclusion

Administration of treatments through oral gavage did not affect histopathology results of liver and testis of the experimental mice. Fanta, sodium benzoate and sodium benzoate with ascorbic acid have mild dystrophy effects on the liver cells, but Fanta with ascorbic acid altered histopathological parameters of the mice greatly, which might result to hepatic diseases. No changes were observed in the testis of mice administered Fanta, sodium benzoate, ascorbic acid, and sodium benzoate with ascorbic acid, however severe undifferentiated stem cells were noted in the testis of mice that consumed Fanta with ascorbic acid simultaneously. Hence, simultaneous consumption of Fanta with ascorbic acid has damaging effects on reproduction of mice and may lead to infertility.

## References

Abdel Hameed, T.F (2004). Light and electron microscopic studies on the effect of orally administered formalin on liver and kidney of Guinea pig. *Journal of the Egyptian German Society of Zoology C. Histology and Histochemistry*, 45:203-224.

Abdulmumeen, H.A., Risikat, A.N., Sururah, A.R (2012). Food: its preservatives additives applications. *International Journal of Chemical and Biochemical Sciences*, 1:36-47.

Afe Babalola University news (2017). <http://www.abuad.edu.ng/taking-fanta-sprite-with-vitamin-c-poisonous/>

Baratta, J.L., Ngo, A. Lopez, B., Kasabwalla, N., Longmuir, K.J, Robertson, R.T (2009). Cellular organization of normal mouse liver: a histological, quantitative

immunocytochemical, and fine structural analysis. *Histochemistry Cell Biology*, 131(6): 713–726.

Bhattacharya, T., Bhakta, A., Ghosh, S. K (2011). Long term effect of monosodium glutamate in liver of albino mice after neonatal exposure. *Nepal Medical College Journal*, 13(1):11-16.

Bilau, M., Matthys, C., Vinkx, C., de Henauw, S. (2008). Intake assessment for benzoates in different subgroups of the Flemish population. *Food and Chemical Toxicology*, 46 (2): 717–723.

CICAD (2005). Benzoic acid and sodium benzoate. *Concise International Chemical Assessment Document*, 26:1-46.

Cheville, N.F (2009). Ultrastructural pathology: the comparative cellular basis of disease. 2<sup>nd</sup> ed. Willey-Blackwell. A John Wiley of Sons, Inc. USA.

Coca cola Company (2017). <http://www.coca-colacompany.com/stories/2017>.

dos Santos, V.P.S., Salgado, A.M., Torres, A.G., Pereira K.S (2015). Benzene as a chemical hazard in processed foods. *International Journal of Food Science*, 1-7.

Eweka, A.O (2007). Histological studies of the effects of monosodium glutamate on the liver and kidney of adult Wistar rats. *Internet Journal of Health*, 6(2):6-15.

EFSA (2016). Scientific Opinion on the re-evaluation of benzoic acid (E 210), sodium benzoate (E 211), potassium benzoate (E 212) and calcium benzoate (E 213) as food additives. *European Food Safety Authority Journal*, 14(3):4433-4559. 33.

Francis F.J (2000). Pioneer in food science and quality. *In a Century of Food Science Chicago: Institute of Food Technologist*, 13-14.

Gardner, L. K., Lawrence, G. D (1993). Benzene production from decarboxylation of benzoic acid in the presence of ascorbic acid and a transition-metal catalyst. *Journal of Agricultural and Food Chemistry*, 41 (5): 693–695.

Hashem, M.A., Mohamed, M.A (2009). Haemato-biochemical and pathological studies on aflatoxicosis and treatment of broiler chicks in Egypt. *Veterinaria Italiana*, (45)2: 323-37.

Kunkel, E.M., Barbara, H.D (2004). The Gale Group Inc., Macmillan Reference USA, New York, Gale Nutrition and Well-being A to Z.

Li, Z., and Diehl, A.M. (2003). Innate immunity in the liver. *Current Opinion in Gastroenterology*, 19:565–571.

Nair, B (2001). Cosmetic ingredient review expert panel: Final report on the safety assessment of benzyl alcohol, benzoic acid and sodium benzoate. *International Journal of Toxicology*, 3: 23-50.

Odegaard, J.I., Ricardo-Gonzalez, R.R., Eagle, A.R., Vats, D., Morel, C.R., Goforth, M.H., Subramanian, V., Mukundan, L., Ferrante, A.W., Chawla, A (2008). Alternative M2 Activation of Kupffer Cells by PPAR $\delta$  Ameliorates Obesity-Induced Insulin Resistance. *Cell Metabolism*, 7: 496-507.

Oluwole, I.O., Dere, F.A., Okoro, O.F (2012). Sodium benzoate mediated hepatorenal toxicity in wistar rat: modulatory effects of *Azadirachta indica* (Neem) leaf. *European Journal of Medicinal Plants*, 2(1): 11-1.

Shubin, A.V., Demidyuk, I.V., Komissarov, A. A., Rafieva, L.M., Kostrov, S.V (2016). Cytoplasmic vacuolation in cell death and survival. *Oncotarget*, 7(34):55863-55889.

Saadoun, D., Cazals-Hatem, D., Denninger, M-H., Boudaoud, L., Pham, B-N., Mallet, V., Condat, B., Brie`re, J., Valla, D (2004). Association of idiopathic hepatic sinusoidal dilatation with the immunological features of the antiphospholipid syndrome. *Case Report Gut*, 53:1516–1519.

Sahara Reporters (2017). <http://saharareporters.com/2017/03/13/court-orders-nafdac-compel-nigerian-bottling-company-warn-consumers-dangers-drinking>

Sasaki, Y.F., Kawaguchi, S., Kamaya, A., Ohshita, M., Kabasawa, K., Iwama, K., Taniquchi, K., Tsuda, S (2002). The coment assay with 8 mouse organs: result with 39 currently used food additives. *Mutation Research*, 519: 103-19.

Theron, M.M., Lues, J.F.R (2010). Organic acids and food preservation, CRC Press, Boca Raton, Fla, USA, 1st edition.

Valchev, I., Grozeva, N., Marutsova, V., Nikolov, Y (2016). Effects of aflatoxin B1 only or co-administerd with mycotox NG on liver function in turkey broilers. *International Journal of Advance Research*, 4(9):1425-1443.

Zhang, L.Y., Wang, C.X (1984). Histopathological and histochemical studies on toxic effect of brodifacoum in mouse liver. *Acta of Academic and Medical Science*, 6 (5):386-388.