

Case reports / Case studies

Cleidocranial Dysostosis – an Enigma Developmental Bones Anomaly.

ABSTRACT

Cleidocranial Dysostosis, known also as Cleidocranial dysplasia, Mutational Dysostosis , Scheuthauer Marie-Sainton syndrome, is a rare condition which is characterized by delayed ossification of midline structures. Case study of the phenomenon has been reported here. Reports revealed that the classical association of a spectacular dental anarchy, with non-closure of cranial sutures, retention of deciduous teeth and delayed eruption of permanent denture and typical facies of underdevelopment raise strong suspicion of autosomal syndrome. The reviewed patient as a classic demonstration of cleidocranial dysostosis, succinctly represented the condition.

Keywords: Cleidocranial Dysostosis, Mutational Dysostosis, Case Study

INTRODUCTION

Cleidocranial Dysostosis, known also as Cleidocranial dysplasia, Mutational Dysostosis , Scheuthauer Marie-Sainton syndrome, is a rare condition which is characterized by delayed ossification of midline structures. It arises as a microdeletion of a chromosome band 6p214, t (6; 18) (p12; q24) translocation 12 and pericentric inversion of chromosome 6.13 from haploinsufficiency caused by mutations in the CBFA1 (Runx2) which is located on the short arm of chromosome 6¹. This chromosome band functions to encode the transcription factor needed for osteoblast differentiation.^{1, 2, 3} However, in some cases the cause is unknown.¹ The principal features described by Gorlin, Pindborg and Collen, is an inherited autosomal dominant syndrome that has equal sexual distribution.⁴ Cleidocranial dysostosis has a reported incidence of 1:200,000⁵.

Cleidocranial dysostosis presents with partial or complete skeletal defects of several bones. It is reported that a painless swelling around the clavicle is a common finding due to deficient or clavicle aplasia sparing the medial ends while complete aplasia is reported in 10% of cases.²

When the clavicles are reduced to small vestiges, hypermobility of the shoulders ensues resulting in effortless painless apposition of the shoulders in front of the chest in 80% of cases.^{5, 6} Such condition may cause nerve damage symptoms from brachial plexus irritation.²

A large soft spot on the top of the head due to delayed and imperfect ossification of the cranium or late closure of fontanelles result in frontal bossing of the forehead as found in Basal Cell Nevus Syndrome and Crouzon syndrome.^{7, 8, 9, 10} The oral manifestations include delayed exfoliation of primary teeth, delayed or non-eruption of permanent teeth and or retention of deciduous dentition and supernumeraries which must be removed to make way for adult teeth in an underdeveloped jaw.¹¹

Other features are low nasal bridge, hypertelorism, high-arched palate, prognathic mandible, maxillary hypoplasia (micrognathism), teeth displacement in the orbits due to deficient cement formation and underdeveloped paranasal sinuses⁵. The phenotypic spectrum ranges from mildly affected individuals with dental abnormalities only, to severely affected patients with syringomyelia^{8, 9}.

Many bones are underdeveloped in the pelvis and joints resulting in widened symphysis and Coxa vara, abduction limitation and Trendelenburg gait. Variety of skeletal abnormalities result in moderately short stature and frame often revealed in the joints of the hand and fingers are short, wide, with cone-shaped epiphyses of the middle and hypoplastic distal phalanges, feet and nails not evident in their siblings^{2, 11, 12, 13, 14}.

The craniofacial abnormalities become obvious during adolescence, which underscores the difficulty of early diagnosis though some cases are often diagnosed in childhood usually at 2-3 years of age¹⁵. The characteristic features include delayed ossification of cranial sutures and fontanelles, often open throughout life producing broad, large and brachycephalic skull. The face is relatively small with hypoplastic maxillary, nasal, zygomatic and lachrymal bones, underdeveloped paranasal sinuses and prominence of the frontal, parietal and occipital bones. Maxillary under development results in relative mandibular protrusion.^{9, 11} Classical features of frontal bossing, hypertelorism and clavicle hypoplasia in both mother and daughter, who claim complete ignorance of the abnormality as cleidocranial dysostosis reported^{11, 16}. Interestingly, other notable cases of patients reportedly used the abnormality of clavicle aplasia for comedy

and or rescue operation of normal individuals¹⁷. However, a rare case of a premature infant delivered at 36weeks gestation of a 40 year old multigravida (G9P8) was reported with symptoms of respiratory distress due to chest deformity that necessitated intensive care unit management.³. The significant clinical variability of this syndrome reflect a degree of phenotypic polymorphism even within the same family and can be a challenge to the attending dentist.^{9, 11}. Epidemiologically,cleidocranial dystosis incidence has been reported in 1: 200,000. ⁵

We report a case of on adolescent who presented with excruciating temporomandibular joint pain as a result of dental malocclusion, a condition that almost always prompts the first visitation to the dentist.

CASE REPORT

CLINICAL HISTORY

AA a 19 year-old girl was seen at the dental clinic complaining of excruciating pain at the temporomandibular joint after eating. The pain of long duration, was initially mild and relieved by analgesics but steadily increased in intensity and frequency over the period of one year. It became excruciating in the last few months, necessitating dental consultation. There was no associated localised or generalised fever or cervical lymphadenopathy. Past medical, surgical and social histories were non-contributory. She is the first child in a family of five children. There was no similar abnormality in her siblings, parents or members of their extended family.

PHYSICAL EXAMINATION

Physical examination revealed a young lady, weighing 55Kg and 1.50m in height. The vital signs were within normal limits. A significant finding was hyper mobility of her shoulders; easily apposed in front of the chest. The facies was that of underdevelopment of the face with depressed nasal bridge, malocclusion and mandibular prognathism. There was some tenderness on palpation of the temporomandibular joint but not warm to touch. No ulceration was noted over the temporomandibular joint.

There was dental malocclusion, anterior open-bite, there were retention of some deciduous teeth in the lower left quadrant, first and second deciduous molars were supra-erupted, and directly

below them were the gnarled erupting first and second premolars in the lower jaw. The patient had two premolars; one premolar was placed lingually between the first and second molars in the right mandible while the other premolar was located buccally between the left upper jaw maxilla first and second molars. There were multiple unerupted permanent teeth and supernumerals appearing on the radiograph. There was also narrowing of both arches with high arched palate. A working diagnosis of cleidocranial dysostosis was made.

INVESTIGATIONS

HEMATOLOGY

The patient's chromosomal studies were normal.

RADIOGRAPHY

SKULL XRAY

Skull (Fig.1a, b, c, d) x-ray examinations revealed non-closure of the sagittal and lambdoid sutures and wormian bones at the lambdoid (fig.1a). The maxillary and frontal sinuses were underdeveloped (fig.1b & c). The maxilla bilaterally and facial sinuses were under developed. There was permanent dentition except the right mandibular third molar. Supernumerary teeth were present bilaterally in the mandibular incisor region and unilaterally in the right mandibular premolar/molar and right maxillary molar regions (fig.1c & d). Arching of the palate was noted.

CHEST XRAY

The chest x-ray (Fig.2) revealed complete absence of the clavicles bilaterally. The radiological diagnosis of cleidocranial dysostosis was made thus confirming the clinical opinion.

TREATMENT

The treatment given was extraction of the supernumerary, impacted and unerupted teeth as they erupted and fabrication of dentures aimed at exposure of permanent teeth, and occlusal equilibration. Carious teeth were restored to eliminate pain and infection.

A course of antibiotics and analgesics to compliment treatment was given. The patient reported complete relief of pain in her temporomandibular joints after two weeks of treatment.

DISCUSSION

Cleidocranial dysostosis is a rare disturbance of developmental anomaly in bones of membranous origin characterised by aplasia / hypoplasia of the clavicle, cranium, face, dental and oral manifestations of proclivity towards retention of deciduous dentition. It is also associated with supernumerary dentition, multiple impactions of the permanent dentition as manifested in the index case. The diagnosis of the disease involved over the years. Martin¹⁸ first reported the condition in 1765, described congenital clavicle defect in a patient, in 1871 both clavicle and skull congenital defects were reported by Scheuthauer¹⁹ and by 1897 the diagnosis of cleidocranial dysostosis was coined by Marie and Sainton²⁰ who described involvement of intramembranous bones of skull, clavicle and flat bones.

Dentition and jaws involvement was described by Hesse²¹ while Yamamoto²² was the first to describe occurrence of 63 supernumerary teeth in a patient. The condition characterised by decreased eruptive force of both primary and permanent dentition, prolonged retention of primary teeth and an increase in odontogenesis resulting in excessive supernumerary teeth^{23, 24}. Yamamoto et al using the electron microscope with crystallographic technique, found that lack of cellular cementum in both normal and supernumerary teeth, partially hyperplastic acellular cementum played no role in teeth eruption rather opined that early loss of gubernacular cord resulted in failure of teeth eruption²².

The condition was then thought to be of unknown aetiologies, pathogenesis, often but not always hereditary²⁵. And when inherited, it appears autosomal dominant, transmitted equally by both sexes without racial predilection^{4,7}. Migliorisi and Blenkinsopp put forward a combination of predominantly defective membranous bone formation, delayed cranial suture and fontanel closure as characteristic features of the condition²⁶. Marie and Sainton first described the hereditary nature of cleidocranial dysostosis as a transmitted autosomal dominant trait²⁰. Spontaneity has been found in about 40% of patients⁹ as well as pituitary dysfunction had also been described^{27, 28, 29, 30}. The occurrence of the syndrome in a two consecutive generations of mother and daughter was reported by Cleber Silva and Tyndall^{16, 31}.

Various degrees of bone hypoplasia; delayed ossification of cranial sutures, intrasutural wormian bone formation and increased skull width as in the index case, sometimes noted exhibit a groove

from the nasion to the sagittal suture were reported by other workers^{9,11}. The critical evaluation of the characteristic features of Cleidocranial dysostosis come handy to differentiate the delayed closure of fontanel from other bony dysplasia like Osteogenesis imperfecta. Hypothyroidism, Rickets and syndromes such as Downs, Crouzon, Apert, Dubowitz and Rousell-Silver's²⁹.

The stature is usually short with narrow and markedly drooped shoulders as in the index case, due either to unilateral or bilateral, partial or total clavicle hypoplasia or aplasia but the neck appears relatively long^{2, 3, 6, 9, 11, 30}. Partial aplasia is common, aplasia of the clavicle at the acromial ends as found in the case presented with variation in size, origin and insertion of the muscles results in hyper mobility of the shoulders and easy approximation in the front of the chest^{2, 5, 11, 16}. The partial collarbones defect noted bilaterally in 80%, cause nerve damage symptoms is not found in the index case⁶.

The features of hypertelorism, mild exophthalmia, brachycephaly, pronounced bossing of biparietal and frontal bones, and small face reported by Tyndall were found in the index case as well as broad based with depressed bridge/saddle nose, skeletal orbital height greater than its width noted by other workers correlate with the finding of the index patient^{30,31}.

Various workers noted Facial bone hypoplasia of maxillary, zygomatic from midfacial deficiency, narrow paranasal sinuses, high arching palate, hard and soft palate submucosal cleft with well-developed mandible resulted in pseudoprognathism as seen in the presented patient.^{31, 33, 34} Congenital dislocation of the hip, delayed closure of the pubic symphysis, pelvic dysplasia as well as cranial manifestations had also been reported.^{30, 33}

The major intraoral features are retained deciduous dentition, delayed or failure of eruption of some or all of the permanent dentition and multiple supernumeraries and tendency for cyst formation in relation to unerupted tooth^{31,33, 34}. The delayed / failed eruption affects deciduous teeth less, since they are covered by small amount of bone at birth, much as permanent teeth without deciduous precursor have greater chance to erupt³³. Fardy concludes however, that the theory of inadequate bone resorption earlier propounded by Rushton in 1932 and confirmed by the works of Hitchin, Migliorisi and Blenkinsopp, explain further that non eruption of permanent teeth is not genetic abnormality since deciduous teeth erupts normally³⁴. They found deformities in the root of permanent teeth of assisted eruption by exposure and that root abnormality are consequential to resistance to eruption, whereas root resorption of primary teeth appears

disturbed³⁴. McIvor is of the opinion that eruption of teeth depends on normal circulating thyroxine and growth hormone, it is delayed in hypopituitarism and hypothyroidism and premature in gigantism and late in progeria³⁰. The delayed eruption or failure of eruption of permanent teeth especially those with deciduous precursors were observed to contribute to the malocclusion as seen in the case presented. A few permanent teeth may just fail to erupt without local or generalised abnormality, but frequently has family history³⁰.

Dental anomalies include root dilacerations, spiking or elongation, kinking, twisting and an almost complete absence of cementum^{31, 34}. Most patients have decreased auditory acuity, resulting from narrowing of the external auditory canals and hypoplasia of the mastoid bones³⁴. This is however not a dominant complaint of the presented case.

Tyndall reports unusual features involving various vascular complications, beta thalassemia minor, large electroencephalographic responses with usually normal laboratory findings³¹. Additionally, extra articular manifestations also occur in this patient presenting clinically as the temporomandibular joint pain. Shafer et al³⁵ introduces the concept of myofascial pain dysfunction syndrome of the masticatory apparatus, muscle spasm being the principle factor of the manifestation. It is initiated by muscular over extension, over contraction or fatigue. Over extension, results from either dental restoration or prosthetic appliances. These encroach on the intermaxillary space. In contrast, over contraction results from over closure due to bilateral loss of posterior teeth or resorption of alveolar bone after the construction of the prosthetic appliance³⁵.

Muscular spasm consequent to over extension produced by left mandibular first and second deciduous molars encroach on the intermaxillary space.

The eruption force of the underlying left mandibular first and second premolars causes the temporomandibular joint pain experienced by the patient. This over the years is the contributory factor to muscular over extension that places a strain upon the entire masticatory apparatus. The extraction of the hyper erupted left first and second deciduous molars, occlusal equilibrium obtained by silver amalgam restoration of the carious teeth with occlusal interference removed by using articulating paper results in a permanent relief of the patient's pain confirmed the opinions of various workers^{31, 33, 34, 35}. Like any genetic abnormality /disease conditions,

cleidocranial dysostosis can exhibit all the features or an almost subclinical expression of merely a few traits as demonstrated by this patient under review.

The clinical and radiological manifestations would suffice to clinch the diagnosis of this structural defect syndrome as is the case presented has a gamut of features.

Early diagnosis of cleidocranial dysostosis could be difficult as majority of cases become obvious only during adolescence and pointer findings or swellings are painless. This however highlights the importance of thorough observation of each patient's general appearance, examination and evaluation by the initially consulted physician.

CONCLUSION

The classical association of a spectacular dental anarchy, with non-closure of cranial sutures, retention of deciduous teeth and delayed eruption of permanent denture and typical facies of underdevelopment raise strong suspicion of autosomal syndrome.

When steadily increasingly excruciating painful mastication occurs with an almost limitless movement of the shoulders and ease of their approximation in front of the patient exist, a working diagnosis of cleidocranial dysostosis is made until proved otherwise.

Roentgenographic evaluation of the skull, intraocular and chest x-ray examinations are quite revealing and confirmatory.

The reviewed patient as a classic demonstration of cleidocranial dysostosis, succinctly represented the condition.

References:

1. Tanaka JL, Ono E, Filho EM, Castilho JC, Moraes ME. Cleidocranial dysplasia: importance of radiographic images in diagnosis of the condition. J Oral Sci September; 2006 48 (3): 161-166..
2. Turek's Orthopaedics: Principles And Their Application. Lippincott Williams & Wilkins, 2005. Pp. 251-252. ISBN 9780781742986.
3. Kristina Imeen Ringe, Eckart Schirg, Michael Galanski. Radiology Case.

2010 Apr;4(4):9-12::DOI: 10.3941/jrcr.v4i4.396.

4. Gorlin RJ, Pindborg J, Cohen MM. Syndromes of the head and neck. 2nd edition, McGraw-Hill, New York, 1976: pp. 180-184.
5. Lovell, Wood. Lovell & Winter's Pediatric Orthopaedics. 6ed 2006. Lippincott Williams & Wilkins. p.240.ISBN 9780781753586.
- 6.Juhl, John. Paul and Juhl's Essentials of radiologic imaging. 7th ed. 1998 Lippincott-Raven. ISBN 9780397584218.
7. Greene, Walker. Netter's Orthopaedics, 1st ed. Masson. ISBN9781929007028.
8. Kalliala E, Taskinen PJ. Cleidocranial dysostosis. Report of six typical cases and one atypical case. O.S., O.M&O.P. 1962; 15 (7): pp. 808-822.
9. Mundlos S. Cleidocranial dysplasia: clinical and molecular genetics. J Med Genet 1999;36:177-182.
10. Gulay K, Filiz AA, Emelgul O, Halit RG, Yusuf G, Aysenur O. Cleidocranial Dysplasia: A Case Report. J Clin Res Pediatric Endocrinol. Sep 2010; 2(3): 134-136.
11. De Nguyen T, Turcotte JY. Cleidocranial dysplasia: review of Literature and presentation of a case. Journal Canadian Dental Association 1994; 60(12): 1073-8.
12. Giampietro F, Cinzia M, Davide F, Silvia G. Angle Orthod. 2009; 79:178-185.
13. Vanderwerf, Sally. Elsevier's medical terminology for the practicing nurse. 1998. Elsevier. p. 65. ISBN 9780444824707.
14. Menkes, John. Child Neurology 7ed 2006. Lippincott Williams & Wilkins. p. 307. ISBN 978078175049..
15. Hefti, Fritz. Pediatric Orthopedics in practice. Springer, p.478. ISBN 9783540699644.
16. Cleber S, Steven D; Neil S. Cleidocranial Dysostosis: A Case Report. Col Dent. 1997; Rev 2:26.
17. Kennedy, J, Michael (1987-10-17). "Jessica Makes It to Safety-After 58 1/2 Hours". Los Angeles Times.
18. Martin M. Sur un déplacement naturel de la clavicle. J Med Chir Pharmacol.1765;23:456.
19. Scheuthauer G. Kombination rudimentärer Schlüsselbeine mit Anomalien des Schädels beim erwachsenen Menschen. Alig Wein Med Zig 1871;16:03.

20. Marie P, Sainton P. Observation d'hydrocephalie hereditaire par vice de developement du crane et due cerveau. Bull. Soc. Med. Paris. 1897; 14/3B: 706.
21. Hesse G. Weitere Befunde am Zahnsystem dysostotischer individen. Osi Z Stomat. 1922;24:205.
22. Yamamoto H, Sakae T, Davies JE. Cleidocranial dysplasia: A light microscope, electron microscope and crystallographic study. Oral Surg , Oral Med, Oral Pathol. 1989;68:195-200.
23. Dard M. Histology of alveolar bone and primary tooth roots in a case of cleidocranial dysplasia. Bulletin du Groupement International Pour La Recherché Scientifique Et Odontologie 1993; 36(3-4):101-7.
24. Quinn PD, Lewis J, Levin LM. Surgical management of a patient with cleidocranial dysplasia: a case report. Special Care in Dentistry 1992; 12(3):131-3.
25. Alderson CG. Hereditary cleidocranial dysostosis- case report. Br. Dent. J. 1960; pp. 108:157. L.
26. Migliorisi JA and Blenkinsopp PT. Management of cleidocranial dysostosis. Br. J. Oral Surgery. 1980;18:212-220.
27. Stiff RH and Lally ET. Cleidocranial dysostosis: Report of a case. Oral Surg. 1969; 2 (2): 202-207.
28. Miller R. et al. Cleidocranial dysostosis: A multidisciplinary approach to treatment. JADA 1978; 96 (2):296-310.
29. Seldin HM, Seldin SD, Rakower W. Cleidocranial dysostosis. J. Oral Surg. 1950;8 (3): 236-241.
30. McIvor J. Dental radiology. In: Grainger and Allison (eds): Diagnostic radiology: A textbook of medical imaging. 3rd edition, Churchill Livingstone, New York, 1997: pp. 2335-2336.
31. Tyndall DA. Cleidocranial dysostosis: A nearly unrecognised case. General Dentistry September-October 1983; pp 390-393.
32. Jones KL. Smith's Recognasable Patterns of Human Malformations. Philadelphia: Elsevier Sanders; 2006.pp872-873.
33. Bishop RG. Dental management of cleidocranial dysostosis, case report. Australian Dental Journal February 1984;29(1):1-4.

34. Fardy MJ. Case study. Cleidocranial dysostosis: some problems in the Dental management of occlusion. Dental Update 1984; 363-368.
35. Shafer WG, Hirsch MK, Levy BM. A textbook of oral pathology. 4th Ed. W B Saunders & company, London, 1983: pp. 713-714.

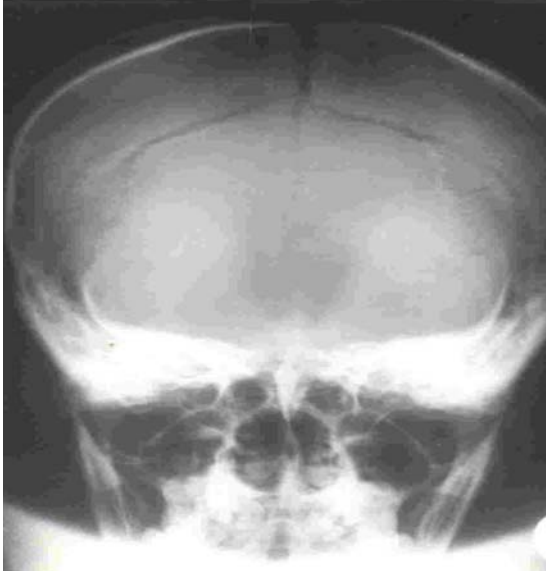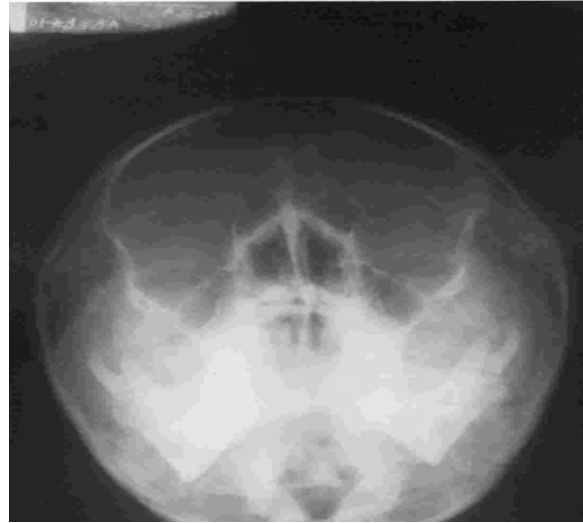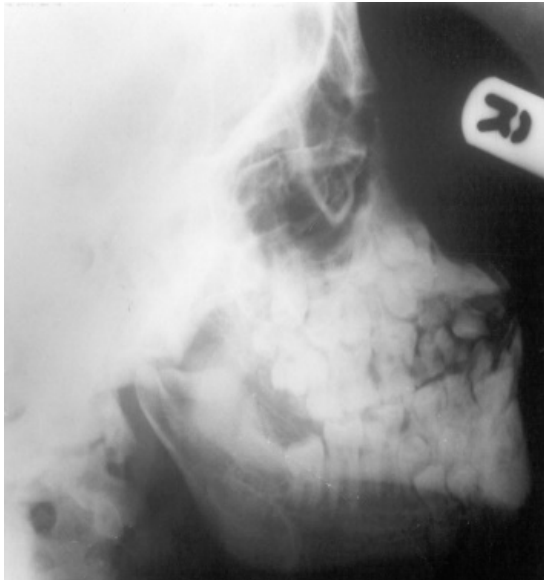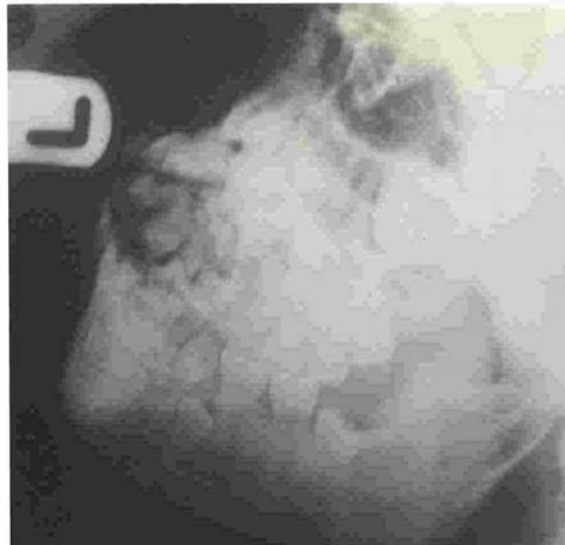
A**B****C****D**

Fig.1. Skull PA view (A): showing non-closure of the cranial sutures, OM view (B) revealing underdeveloped sinuses. Face Lateral and Oblique views (C&D): showing dental anarchy and retention of some deciduous teeth. Features are consistent with Cleidocranial dysostosis.

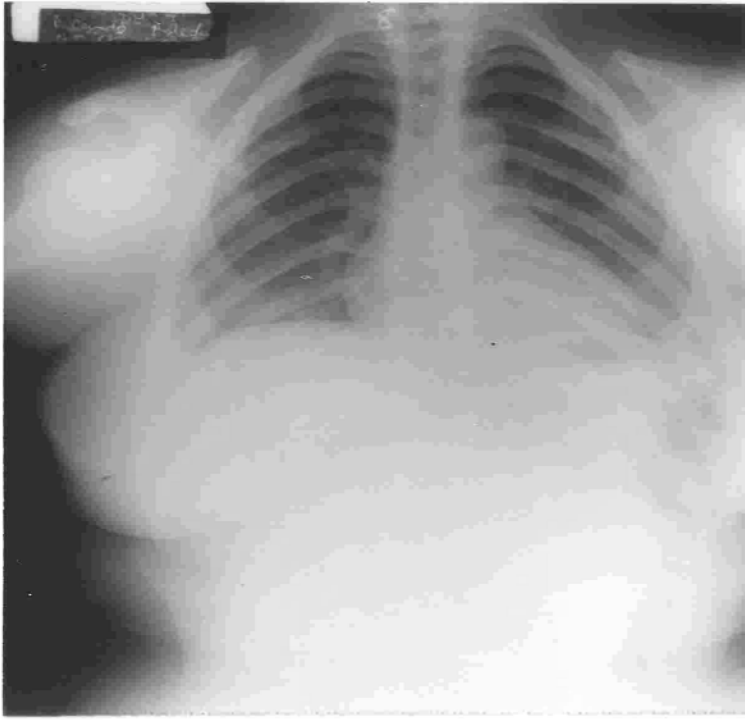


Fig. 2. Plain Chest PA view: showing bilateral absence of clavicles in keeping with Cleidocranial dysostosis.