An Over View of Bovine dermatophytosis

Abstract:

Dermatophytosis is a superficial fungal infection of hair and keratinized layers of the epidermis and is caused by keratinophilic and keratinolytic genera such as *Microsporum*, *Trichophyton* and *Epidermophyton*. It is an endemic infection in many countries throughout the world affecting companion animals (dogs, cats), domestic animals (calves), and laboratory animals (rabbits) as well as humans. *T. verrucosum* considered the main cause of ringworm in cattle. The typical lesion is a heavy, grey-white crust, circular and raised above the skin most frequently found on the head and neck. The disease can be diagnosed by direct examination, fungal culture, skin biopsy sero and molecular diagnosis methods. This overview will forecast more light of the different aspects of this disease.

Key words:

Dermatophytosis,Bovine,Clinical feature, Diagnosis.Treatment

Introduction:

Dermatophytosis (ringworm) is a superficial infection of the keratinacious epidermidermal layers of the skin, hair and nails caused by dermatophytes (*Microsporum*, *Trichophyton* and *Epidermophyton*). According to their natural reservoir, dermatophytes are classified as anthropophilic, zoophilic or geophilic [1].

Ringworm fungi are found all over the world but grow best in warm and humid environments and are therefore, more common in tropical and subtropical regions where they cause considerable losses as a result of decreased production, public health concern, premature culling, treatment costs and downgrading of hides and skin [2- 4].

Dermatophytosis mainly affected cattle especially young calves due to less developed immune system [5], the disease has been reported in other animals as small ruminants and human [6].

Predisposing factors

1- Age
2- Breed of animal

UNDER PEER REVIEW

3- Stress
4- Transportation
5- Management
6- Climate condition [7]

Epidemiology:

Most outbreaks of Dermatophytosis in cattle often occurred in fall and winter months due to over crowdness inside housing and contact with infected objects as mangers and walls. Cattle under one year old are more susceptible to the infection especially under stressful conditions like transportation and during weaning [8, 9].

The arthroconidia of the fungus is able to survive in skin scales of infected animals for up to several months in moist and dark places which lead to easily transmission to human and other animals [10]. On the other hand cattle could carry dermatophytes spores on their coats without showing any signs of disease [11].

Economical impacts:

1- Reduce weight up to 10-13 kg/butchered animals in beef cattle
2- Lower milk yield in dairy cattle
3- Poor hide quality for the leather industry [1, 12]

Transmission:-

Dermatophytosis transmitted through direct contact with infected animals; therefore, overcrowded stables have a high prevalence rate of infection, where the fungus can spread easily among subjects confined in small areas [13]. The disease can also be transmitted indirectly contact with contaminated fomites [14].

Clinical features:

UNDER PEER REVIEW

The typical lesion in cattle is a heavy, grey-white crust, circular and raised above the skin most frequently found on the head and neck, especially around the eyes and face, but may, in severe cases, be found all over the body [15, 16] (Figs. 1-5)

Fig.1: Head of a 3 months old calf with thick, crusty, grayish- white raised lesions around the eyes (Circled).[23]

Fig.2: Circumscribed area of alopecia filled with heavy asbestos like scales.[31]

UNDER REVIEW

Fig.3: A: Adult Cow show regular hairless areas at tail. B: Calf showing circular hairless area at head and around of eye [60]

Fig.4: Ring worm lesions of face, neck and body of a calf.[61]

Fig.5: Typical ring worm lesions on the body of a calf. [61]

UNDER PEER REVIEW

Etiology:

T. verrucosum considered the main cause of ringworm in cattle has been isolated by [17-22]. Outbreak of dermatophytosis in cattle caused by *T. verrucosum* reported by [23]

T.mentagrophytes has been isolated by [24, 25]. *T. soudanenses* has been repoted by [26]**.** [27, 28] recorded *M canis***.** *T. equinium, M. gallinae* and *M. gypseum*. *T.rubrum* has been reported by [29].

Diagnosis:

Diagnosis of ringworm in cattle based on clinical signs, direct microscopic examination of skin scraping and isolation of causative agent on specific medium [30].

Sample collection:

Skin scraping samples from the cattle that were suspected to be infected with dermatophytes will be collected on the basis of gross lesion on their body after cleaning with ethyl alcohol 70%. Hair and scrapings samples were collected with forceps or scalpel just behind the extending margin in the infected area. Samples can be kept in polyethylene bags [31].

Direct examination:

Each Sample from infected cattle should be divided into two portions, one portion to be used for direct microscopic examination and the other for culture. Direct examination of hairs and scales looks for the presence of fungal hyphae and/arthrospores. Hairs or hair fragments with hyphae and arthrospores are thicker, with a rough and irregular surface.

This procedure can be done with clearing agents such as Potassium Hydroxide (KOH) 10 or 20% [32-34]. Infected hairs can be readily identified at x4 or x10 magnification, appearing pale, wide and filamentous compared with normal hairs. On high magnification (x40) cuffs of arthrospores are visible.(Fig.6)

UNDER PEER REVIEW

Fig.6: Microscopic examination of infected hair :(A) Endothrix arrangement of arthrospore and (B) Ectothrix arrangement of arthrospore [60]

Fungal culture:

Fungal culture is considered the 'gold standard' for diagnosis [35]. Sabouraud's dextrose agar (SDA) containing cycloheximide, penicillin and streptomycin were used in most diagnostic laboratories. Plates should be incubated at 25ºC for 5 weeks. Dermatophytes test media (DTM) is recommended as the best media for isolation of dermatophytes because the presence of the red color indicated positive result, this can help in early identification of highly suspected cultures [36]. The isolates should be examined macroscopically for culture characters including (texture, shape and color), pigment production [37] and microscopically after staining with lactophenol cotton blue using wet mount technique [38]. (Figs.7-10)

In addition to technique steps mentioned above, pigment production on corn meal agar, urease activity on urea agar base, growth at 37◦C on SDA. Biochemical test were employed to differentiate *Trichophyton* spp. are enriched medias with thiamine and inositol, the isolates are subcultured in this media [39].

UNDER PEER REVIEW

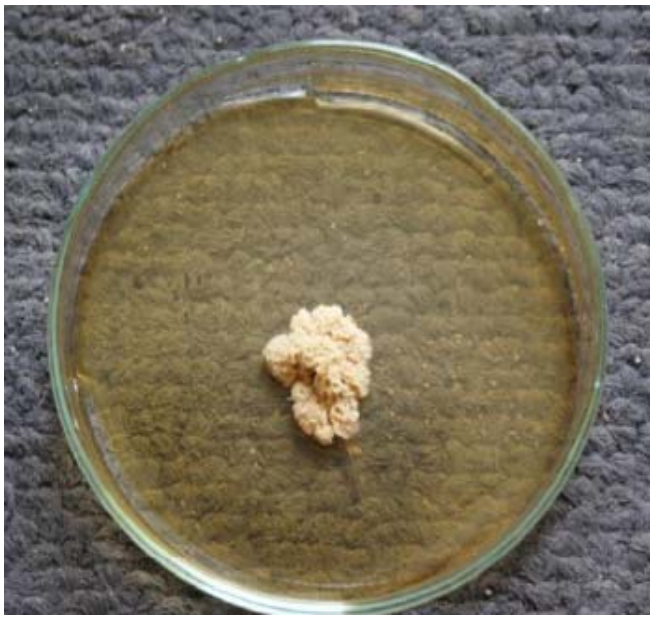

Fig.7: *T. verrcosum* showing very slow growing, with heaped up, button like appearance folded white colored colony. [22]

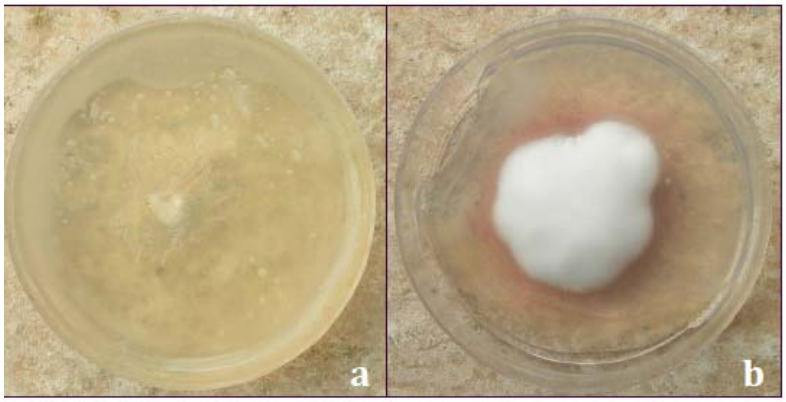

Fig.8: Growth of *T. verrcosum* (a) on T1 vitamin free (b) T3 with inositol and thiamine media [23]

UNDER PEER REVIEW

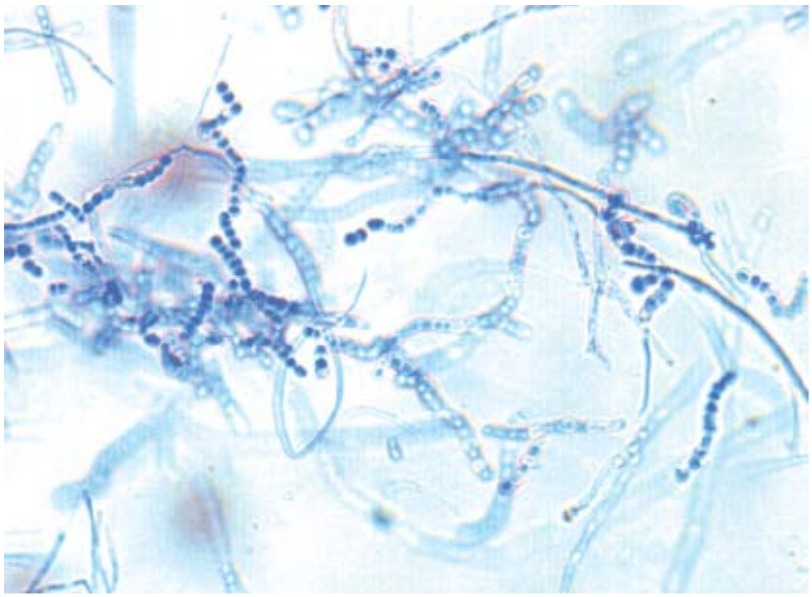

Fig. 9: Wet mount from ***T. verrcosum*** **culture show** broad, irregular hyphae and the chains of chlamydospores [25]

Fig. 10: **Wet mount from *T. verrcosum* culture show macronidia have a rat-tail or string bean shape [60]**

Skin biopsy:

Skin biopsy from active lesion should be collected after clean with 70% alcohol, the area around the lesion must be injected with local anesthesia drug. 1 mm^3 tissue should be cut from the edge of circular raised lesion. Skin samples first fixed in 10% formal saline then 5-6 thick paraffin embedded section should be processed. Before staining, xylene must be used to remove paraffin. Two kinds of stains can be used haematoxylin and easin for histopathological examination and Grocott methenamine for demonstration of fungal hyphae in tissue sections [40]. (Figs.11-14)

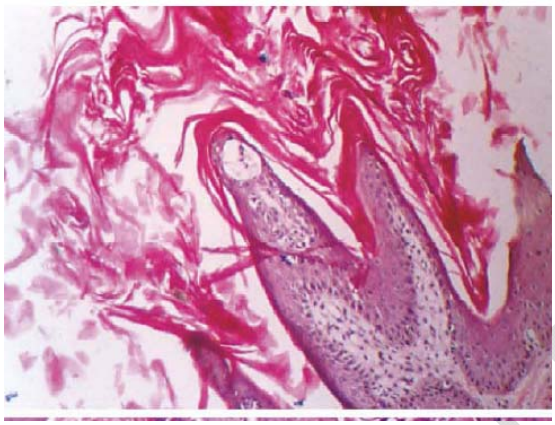

Fig. 11: skin section showing marked hyperkeratosis of the stratum corneum of epidermis H&E x100. [40]

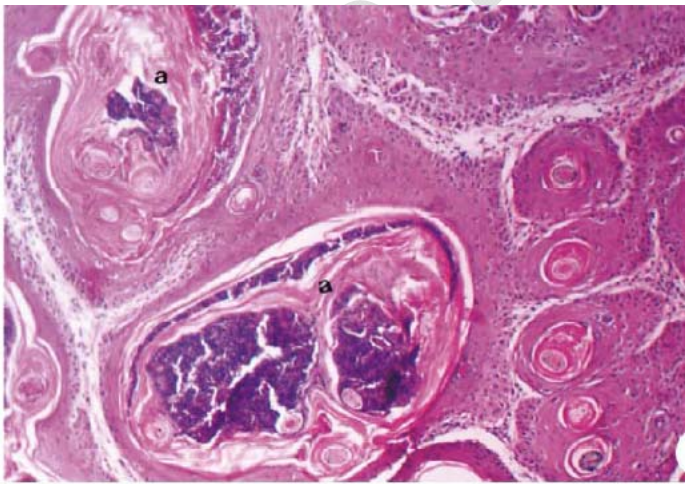

Fig.12: Hair follicles showing excessive keratinization and destruction due to abscess H&E x100. [40]

PEER REVIEW

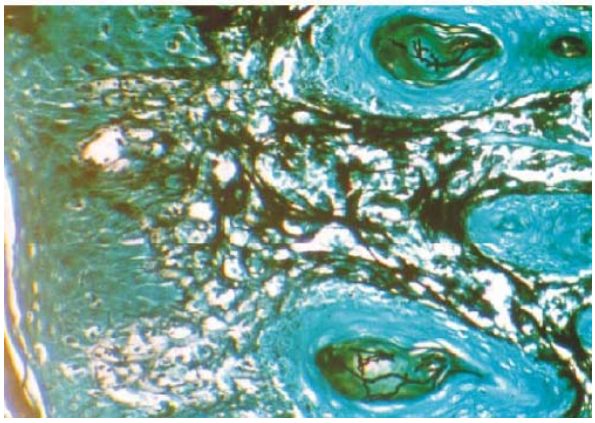

Fig.13: Hair follicles showing fungal hyphae in longitudinal section in keratinized mass GMS x200. [40]

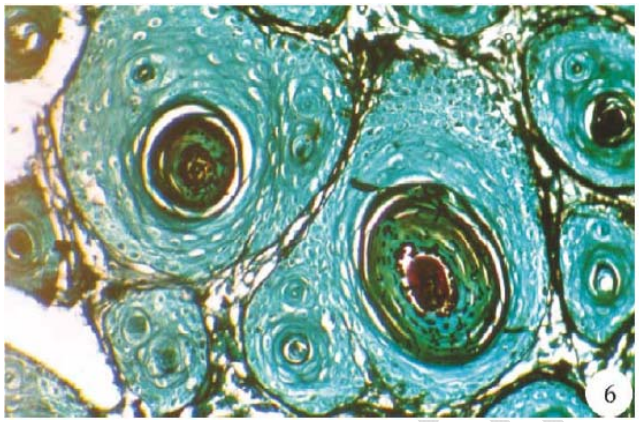

Fig.14: Hair follicles showing fungal hyphae in cross section in keratinized mass GMS x200. [40]

Molecular identification:

Diagnosis with conventional methods is time-consuming because it might take up to 4 weeks or longer to give the final results [1]. Furthermore, morphological identification may be confusing due to polymorphism of dermatophytes [41]. During the last decade, a wide variety of molecular techniques has become available as possible alternatives for routine identification of fungi in clinical microbiology laboratories [42, 43]. Two different molecular techniques for identification of dermatophytes isolated from cattle were done by [44]; the first was the use of polymerase chain reaction (PCR) to amplify the internal transcribed spacer regions of the ribosomal DNA using ITS-1 and ITS-4 as primers. Restriction fragment length polymorphism analysis the amplified ITS regions using the enzyme MvaI to identify dermatophyte species. The second technique was a PCR using the short oligonucleotide 5'-GACAGACAGACAGACA-3' as primer

UNDER PEER REVIEW

for the RAPD typing of the isolates for identification of dermatophytes based on species specific profiles.(Figs.15-16)

Three specific primers were used by [45**]** to amplify small subunit ribosomal RNA gene of *Trichophyton* spp. (Fig.17)

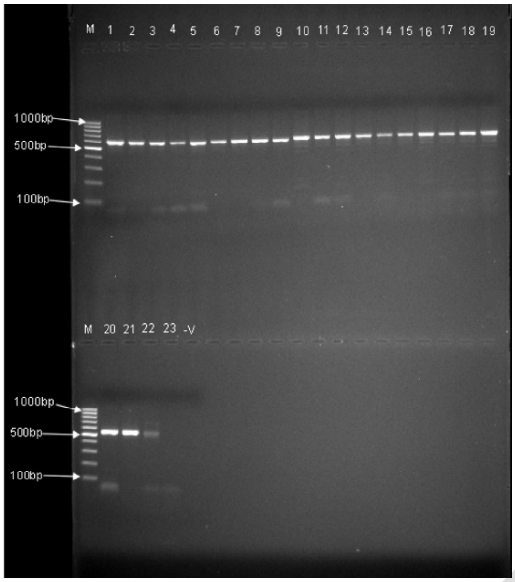

Fig.15: Agarose gel electrophoresis showing amplification of the 600 bp ITS region of *T. mentagrophytes* by PCR. Lane M, molecular weight marker, Lanes (1–23), isolates 12, 13, 26, 32, 37, 45, 47, 58, 62, 78, 81, 83, 95, 120, 139, 215, 237, 321, 332, 345, 380, 415, and 427 phenotypically identified as *T. mentagrophytes* and lane–v, negative control.[44]

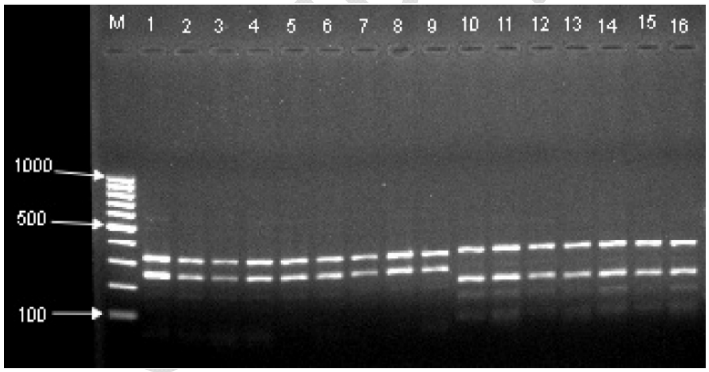

Fig.16: Agarose gel electrophoresis of MvaI digestion products for the 600 bp ITS region of *T mentagrophytes*. Lane M, molecular weight marker; lanes(1–9), isolates, 12, 13, 26, 32, 37, 45, 47, 58, and 62 (approximately, 320 and 280 bp), lanes 10–16, isolates 78, 81, 83, 95, 120, 139 and 215 (approximately, 350 and 250 bp)[44].

PEER REVIEW

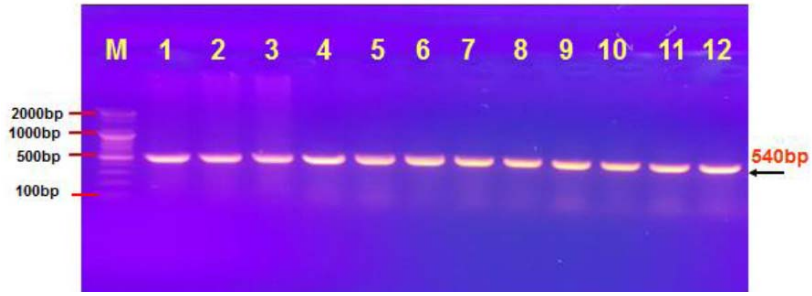

Fig. 17: show under UV light by use Agarose gel in electrophoresis analysis apparatus that shows the PCR product analysis of small subunit ribosomal RNA gene in Trichophyton spp. isolates. M: marker (range between 100 to 2000bp), lane (1-12) some of positive Trichophyton spp. in (540bp) PCR product size.[45]

Serodiagnosis:

Two different recombinant forms of Trichophyton *rubrum* dipeptidyl peptidase V (TruDppV) and *T. rubrum* leucin aminopeptidase 2 (TruLap2), which are 98% identical to *Trichophyton verrucosum* orthologues were used for identification of *T.verrusoum* isolated from cattle by ELISA. Detection of specific antibodies against DppV gave 89.6% sensitivity, 92.7% specificity, a 96.8% positive predictive value, and a 78.4% negative predictive value. The recombinant TruLap2-based ELISA displayed 88.1% sensitivity, 90.9% specificity, a 95.9% positive predictive value, and a 75.7% negative predictive value [46].

Treatment:

Optimal therapy of dermatophytosis requires a combination of topical antifungal therapy, concurrent systemic antifungal therapy and environmental decontamination. The treatment should be continued until two consecutive negative cultures (at weekly or bi-weekly intervals) are obtained [13]. Topical treatments speed resolution of clinical lesions and may help prevent zoonotic contagion. Systemic therapies that have prolonged residual activity in the skin and hair provide the most effective treatments.

Topical therapy:

1- Zinc oxide [47]
2- Thiabendazole[48]
3- Ointment containing benzoic acid 6 g, salicylic acid 3 g, sulfur 5 g, iodine 4 g and vaseline 100 g [15]
4- 1% tioconazole [49]

UNDER PEER REVIEW

5- enilconazole (10%)[50]
6- Whitfield's ointment [51]
7- Silver Nitrate [52]
8- Natamycin[53]

Systemic therapy:

1- Ivermectin 200 micrograms /Kg. [54,55]
2- Griseofulvin10 mg/kg body weight for 7 days in mild infections; in severe cases 2–3 weeks[13]

Environmental decontamination:

Clinafarm can be used for disinfecting of environment with spray or smoke generator [56].

Vaccination

A live vaccine of *Trichophyton verrucosum* was used to control cattle dermatophytosis [57], while an attenuated strain of *Trichophyton verrucosum* was reported by [58]. In case of herd the use of attenuated vaccine led to decrease of new infected herds from 1.7% in 1980 to 0.043% in 2004 [59].

Conclusion:

Dermatophytoses are the most common fungal infections in cattle. Many studies were done considering different aspects of the disease (eg. epidemiology, clinical features, diagnosis, treatment, prevention, and control). Due to economic impact and health problem of the disease in cattle vaccination and improved hygiene, may be useful for managing ringworm.

References:

1- Weitzman I., Summerbell R.C. The Dermatophytes .Clinical Microbiol Review.1995; 8:240-259.
2- Wabacha JK, Gitau GK, Bebora LC, Bwanga CO, Wamuri ZM, Mbithi PM. Occurrence of dermatomycosis (ringworm) due to *Trichophyton verrucosum* in dairy calves and its spread to animal attendants. Jof South African Vet Associ1998; 69(4): 172-173.
3- Nweze EI. Dermatophytosis among children of Fulani/Hausa herdsmen living in Southeastern Nigeria. Revista Iberoamericana de Micologia. 2010; 27(4): 191-194.

UNDER PEER REVIEW

4- Swai ES, Sanka PN. Bovine Dermatophytosis Caused by *Trychophyton verrucosum*: A Case Report. Vet World. 2012; 5(5), 297-300.

5- Radostits OM, Blood DC, Gay CC. Veterinary Medicine, 10th Ed, Bailliere Tindall, London, 1997.

6- Ming PX, YLXm Ti, Bulmer GS. Outbreak of *Trichophyton verrucosum* in China transmitted from cows to humans. Mycopathologia. 2006; 161:225-228.

7- Al-Rubiay KK. Dermatoepidemiology: A household survey among two urban areas in Basra city, Iraq. Int J Dermatol. 2006; 4:1-4.

8- Moretti A, Agnetti F, Mancianti F, Nardoni S, Righi C, Moretta I, Morganti G, Papini M.. Dermatophytosis in animals: epidemiological, clinical and zoonotic aspects. Gital.Dermatol.Venereol. 2013.; 148: 563-572.

9- Songer GJ, Post WK. Veterinary Microbiology. Bacterial and Fungal disease Agent of Animal disease. Elsevier Saunders.2005: 361-363.

10- Weber A. Mycozoonoses with special regard to ringworm of cattle. Mycoses. 2000; 43: 20–22.

11- Takatori K, Takahashi,A, Kawai S, Ichijo S, Hasegawa A.. Isolation of *Trichophyton verrucosum* from lesional and non-lesional skin in calves. J Vet.Med. Sci. 1993; 55(2): 343-344.

12- Ogbonna C I, Enweani I B, Ogueri S C. The distribution of ringworm infections amongst Nigerian nomadic Fulani herdsmen Mycopathologia, 1986; 96(1): 45-51.

13- Chermette R, Ferreiro L, Guillot J. Dermatophytoses in animals. Mycopathologia. 2008; 166: 385-405.

14- Pal M, Dave P. Transmission of *Trichphyton verrucosum* infection from cattle to man. Intas Polivet . 2006;7: 429-431

UNDER PEER REVIEW

15- AL-Ani FK, Younes FA, AL-Rawashdeh FO. Ringworm infection in cattle and horses in Jordan. *Acta Veterinaria Brno*, 2002; 71: 55-60.

16- Cam Y, Gümüssoy K.S, Kibar M, Apaydin N, Atalay Ö. Vet Record.2007;160:408-410.

17- Abou-Eisha AM, Sobih MA, Hanaa MF, Heba SE. Dermatophytes in animals and their zoonotic importance in Suez Canal area. SCVMJ, 2008, XIII(2).

18- Hameed K, Riaz ChF, Nawaz MA, Naqvi SMS, Gräser Y, Kupsch C, Pasquetti M, Luca Rossi L, Min ARM, Tizzani P, Chiavassa E, Peano A. *Trichophyton verrucosum* infection in livestock in the Chitral district of Pakistan. J Infect Dev Ctries 2017; 11(4):326-333.

19- R. Papini S. Nardoni A, Mancianti FF. High Infection Rate of *Trichophyton verrucosum* in Calves from Central Italy. Zoonoses. 2009;56(2): 59-64

20- El-diasty EM, Ahmed MA, Okasha N, Mansour SF, El-dek SI, Abd El-khalek HM, Youssif MH . Antifungal activity of zinc oxide nanoparticles against dermatophytic lesions of cattle. Romanian j. biophys. 2013; 23(3): 191-202.

21- Crotti S, Moretta I, Moretti A, Maresca C, Troiani L, Papini M. *Trichophyton verrucosum* infection in cattle farms of Umbria (Central Italy) and transmission to humans. Mycoses. 2014; 57(7) : 400-405

22- Mousa SW, Abdeen EE. Evaluation of New Compounds Efficacy on Dermatophytosis Treatment in Cattle and Buffalo. J of Dairy and Vet Sci. 2018;7 (1):1-4

23- Dalis JS, Kazeem HM, Kwaga JKP, Kwanashie CN. An outbreak of ringworm caused by *Trichophyton verrucosum* in a group of calves in Vom, Nigeria. Afr. J Microbiol. Res. 2014; 8(8):783-787.

24- Agnetti F, Righi C, Scoccia E, Felici A, Silvia Crotti S, Moretta I, Moretti A, Maresca C, Troiani L, Papini M. *Trichophyton verrucosum* infection in cattle farms of Umbria (Central Italy) and transmission to humans . Mycoses.2014;57(7) : 400-405

25- Shams-Ghahfarokhi M, Mosleh-Tehrani F, Ranjbar-Bahadori S, Razzaghi-Abyaneh M. An epidemiological survey on cattle ringworm in major dairy farms of Mashhad city, Eastern IranIRAN. J. Microbiol. 2009;1 (3) : 31-36

UNDER PEER REVIEW

26- Duartea ER, Oliveiraa NJF, Medeirosb AO, Rosac CA, Facury-Filhod EJ. Yeasts isolated from beef heifers with ringworm. Arch Med Vet. 2013; 45:71-75

27- Abu-Samra MT, Imbabi SE, Mahgoub ES. *Microsporum canis* infection in calves. Sabouraudia. 1975;13(2):154-156.

28- Nweze EI. Dermatophytoses in domesticated animals. Rev Inst.Med Trop Sao Paulo. 2011; 53(2):95-99

29- Mitra SK, Sikdar A, Das P. Dermatophytes isolated from selected ruminants in India. Mycopathologia. 1998; 142(1):13-6.

30- Dalis JS, Kazeen HM, Kwaga JKP, Kwanashie CN, Muhammed M1, Okewole PA., Shamaki D, Ahmed MS. Dermatophytosis caused by *Trichophyton verrucosum* in a three month old calf in Shendam, Plateau State, Nigeria International J of Microbiol Res. 2014; 6(1):515-518.

31- ElAshmawy WR, Ali ME. Identification of Different Dermatophytes isolated From Cattle, Cats and Horses Suffered From Skin Lesions Alexandria J of Vet Sci. 2016; 49 (2): 126-132

32- Lacaz CS, Porto E, Martins JEC, Heins-Vaccari EM, Melo TN. Tratado de Micologia Médica, 9th ed. Prefácio: Bertrand Dupont. São Paulo: Sarvier. 2002; 44(5): 297-298.

33- Sidirm J. Micologia médica à luz de autores contemporâneos. Rio de Janeiro: Guanabara Koogan. 2004.

34- Pérez J, Carrasco L. Diagnóstico histopatológico de micosisenpatología veterinária. Revista Iberoamericana de Micologia. 2000; 17: 18-22.

35- Moriello, KA. Diagnostic techniques for dermatophytosis. Clinical Techniques in Small Animal Practice 2001; 16: 219–24.

36- Moriello K. Feline dermatophytosis Aspects pertinent to disease management in single and multiple cat situations. J of Feline Medicine and Surgery. 2014; 16: 419–431

37- Ellis D, Davis S, Alexiou H, Handke R, Bartley R. Description of medical Fungi. Mycology Unit, Women's and Children's Hospital, North Adelaide. 2007.

UNDER PEER REVIEW

38- Rebell G, Taplin D. Dermatophytes: their recognition and identification. Revised edn. Coral Gables, University of Miami Press, Florida. 1974

39- Dalis, J S, Kazeem HM, Kwaga JKP, Kwanashie CN. An outbreak of ringworm caused by *Trichophyton verrucosum* in a group of calves in Vom, Nigeria. Afr J Microbiol Res. 2014; 8(8):783-787.

40- Kumar R,Khurana R, Narang G. Histopathology of dermatophytosis in cattle calves. Indian J Vet Pathol. 2010; 34(1):9-11.

41- Gupta AK, Ryder JE, Summerbell RC. Onychomycosis: Classification and diagnosis. J Drugs Dermatol. 2004; 3:51–56.

42- . Arabatzis M, Xylouri E, Frangiadaki I, Tzimogianni A, Milioni A, Arsenis G, Velegraki A. Rapid detection of *Arthroderma vanbreuseghemii* in rabbit skin specimens by PCR-RFLP. Vet Dermatol. 2006;17:322–326.

43- Arabatzis M, Bruijnesteijn van Coppenraet LE, Kuijper EJ, de Hoog GS, Lavrijsen AP, Templeton K, van der Raaij-Helmer EM, Velegraki A, Graser Y, Summerbell RC. Diagnosis of common dermatophyte infections by a novel multiplex real-time polymerase chain reaction detection/identification scheme. Br J Dermatol. 2007;157:681–689.

44- Dalis JS, Kazeem HM, Kwaga JKP, Kwanashie CN, Yakubu B, Owolodun OA, Jambol AR. Molecular characterization of dermatophytes isolated from cattle in Plateau State, Nigeria. Vet Microbiol. 2018; 219:212-218.

45- Ismaeel GK. Molecular identification of some causes of ringworm isolated from cattle in Al-Diwaniya region. J of kerbala university 2017 ; 15 (2) : 148-158.

46- Băguţ ET, Cambier L, Heinen MP, Cozma V, Monod M, Mignon B. Development of an Enzyme-Linked Immunosorbent Assay for Serodiagnosis of Ringworm Infection in Cattle. Clin Vaccine Immunol. 2013; 20(8): 1150–1154.

47- El-Diasty EM, Ahmed MA, Okasha N, Mansour SF, El-Dek SI, El-Khalek HMA M.H. Youssif MH. Antifungal activity of zinc oxide nanoparticles against dermatophytic lesions of cattle. Romanian J Biophys. 2013; 23(3):191-202.

48- Pandey VS. Effect of Thiabendazole and tincture of iodine on cattle ringworm caused by *Trichophyton verrucosum*. Trop Anim Hith Prod.1979; 11: 175-178.

UNDER PEER REVIEW

49- Kirmizigul AH, Gokce E, Buyuk F, Erkilic EE, Celebi O, Gulmez A, Citil M. Effectiveness of the local application of 1% tioconazole in the treatment of bovine dermatophytosis, Kafkas Univ Vet Fak Derg.2013; 19 (Suppl-A):A191-A194.

50- Kirmizigul AH, Gokce E, Ozyildiz Z, Buyuk F, Sahin M. Topical use of enilconazole (10%) in the treatment of bovine dermatophytosis: Clinical,mycological, and histopatological findings. Kafkas Univ Vet Fak Derg. 2009; 15 (2):273-277.

51- Cam Y, Koc AN, Silici S, Gunes V, Buldu H, Onmaz AC, Kasap FF. Treatment of dermatophytosis in young cattle with propolis and Whitfield's ointment, Vet Record.2009; 165(7):57-58.

52- Karabulut E, Canpolat I. The Treatment of Ringworm with Silver Nitrate Pencil in Cattle: Only One Application. IOSR J of Agri and Vet Sci. 2016; 9(9): 34-36.

53- Oldenkamp EP. Natamycin treatment of ringworm in cattle in the United Kingdom. The Veterinary Record. 1988; 105:5554–5556.

54- Jameel GH, Minnat TR, Humadi AA, Al-Ezzy AIA. Hematological and Histopathological effects of ivermectin in treatment of ovine dermatophytosis in Diyala province-Iraq, International J of Sci and Res. 2014; 3(11): 1389-1394.

55- Jameel GH, Ahmed AA, Jalil OK, Dawood WS. Ivermectin activity in treatment of cattle dermatophytosis. Diyala Agri Sci J. 2015;7 (1): 30 – 40.

56- Rochette F, M. Engelen M, Vanden- Bossche H. Antifungal agents of use in animal health – practical applications. J. vet. Pharmacol. Therap. 2003; 26: 31–53,.

57- Aamodt O .Vaccination of Norwegian Cattle against Ringworm . Zoonoses and public hlth. 1982; 29(6): 451-456.

58- Gudding R, Naess B. Vaccination of cattle against ringworm caused by *Trichophyton verrucosum*. Am J Vet Res. 1986; 47(11):2415-7.

59- Lund A, Bratberg AM, Næss B, Gudding R. Control of bovine ringworm by vaccination in Norway. Vet Immunol Immunopathol. 2014; 15:37-45.

60- Jalil WI. Clinical and epidemiological investigation of bovine dermatophytosis in Diyala ProvinceAl-Anbar J Vet. Sci.2017; 10 (2):38-44.

UNDER PEER REVIEW

61- El-Ashmawy WR, Abd ELHafez E, Abd El Saeed H. Clinical Study on Dermatophytosis in Calves with *in vitro* Evaluation of Antifungal Activity of Bergamot oil. Advan in Anim and Vet Sci. 2015; 3(1):34-39.

UNDER PEER REVIEW