

### UNILATERAL TEMPOROMANDIBULAR JOINT ANKYLOSIS – REPORT OF A CASE

#### ABSTRACT:

Ankylosis of TMJ is the bony or fibrous fusion of articular components of joint. Ankylosis of TMJ can lead to facial deformity, which worsens with growth, having a negative influence on the psychological development of the patient. The present case report is of a 58-year-old female patient who reported with an inability to open mouth which was diagnosed as unilateral true fibrous ankylosis. This case was treated by interpositional gap arthroplasty followed by physiotherapy. Since TMJ ankylosis may go unnoticed for a long time, early intervention is mandatory for proper growth and function of the mandible

**KEYWORDS:** *Temporomandibular joint, Fibrous ankylosis, Trauma*

#### INTRODUCTION:

Temporomandibular joint is a unique, complex, diarthrodial synovial joint which provides both hinging and gliding movements. Disorders involving temporomandibular joint involves several clinical conditions that involves the temporomandibular joint, muscles of mastication and associated structures<sup>1</sup>. Temporomandibular joint ankylosis is one of the types of the temporomandibular joint disorder that leads to restriction of mouth opening from partial reduction to complete immobility of jaw<sup>1</sup>. Ankylosis is a Greek word which means 'stiff joint'<sup>2</sup>. American academy of orofacial pain[AAOP] defined ankylosis of TMJ as restriction of movements due to intracapsular fibrous adhesions, fibrous changes in capsular ligaments[fibrous ankylosis] and osseous mass formation resulting in fusion of articular components[osseous ankylosis]<sup>5</sup>.

Ankylosis of TMJ is most commonly associated with trauma, local or systemic infection, systemic diseases such as Rheumatoid arthritis, psoriasis, ankylosing spondylitis<sup>2</sup>. Depending upon the severity and age of presentation, the patient manifests with trismus, compromised mandibular growth, malocclusion and facial deformity which may influence aesthetics, oral hygiene, mastication and speech leading to psychological distress<sup>3</sup>. Here we describe a case of unilateral fibrous ankylosis of TMJ in a 58 year old female patient.

30 **CASE REPORT:**

31 A 58 years old female patient reported to the Department of Oral Medicine and Radiology  
32 with a chief complaint of reduced mouth opening since 7 years. Patient. Patient gives a history of  
33 trauma to facial skeleton due to a car accident 7 years back. Patient related a history of progressive  
34 restriction of mouth opening. History of pain in right ear region and aggravated while opening and  
35 closing mouth. No history of any other systemic illness or relevant medical history. No family history  
36 of congenital disorders. No par functional habits were reported.

37 On Extraoral examination, there was no facial asymmetry. Deviation of the mandible to the  
38 right side while opening mouth. No clicking sounds were heard on opening, closing and lateral  
39 movements. Tenderness was present on palpation of the right side of TMJ with limited maximum  
40 interincisal mouth opening [20 mm]. The profile of the patient appeared convex.

41 Patents blood profile showed that she was anemic with haemoglobin being 7 gm%.  
42 Rheumatoid factor test was done to rule out rheumatoid arthritis and was negative.

43 Radiographic examination comprised of panoramic radiograph and computed tomograph,  
44 which revealed lack of structural organisation, wide condylar head on right side and obliteration of  
45 right TMJ space.

46 Based on clinical as well as radiographic findings, a diagnosis of unilateral true right bony  
47 ankylosis was confirmed. The surgical plan for enhancing mouth opening included interpositional  
48 gap arthroplasty followed by physiotherapy. After three months, the mouth opening was increased  
49 to 35 mm.

50 **DISCUSSION:**

51 TMJ ankylosis is a bony or fibrous union of the condyle of the mandible, and mandibular  
52 fossa of temporal bone<sup>1</sup>.most common etiological factor for TMJ ankylosis is trauma which can lead  
53 to intraarticular hematoma along with scarring and formation of excessive bone leads to  
54 hypomobility of joint<sup>3</sup>. It can also be primarily due to congenital defect or secondary to  
55 infections,(otitismedia, or heterogenous infection), post-surgical malunion, trauma or systemic  
56 conditions like ankylosing spondylitis, rheumatoid arthritis etc<sup>3</sup>.

57 Limited movement of the mandible may reflect a TMJ disorder or disorder of masticatory  
58 muscles.TMJ ankylosis may be classified according to site [intra /extra articular], type of tissue  
59 involved [bony, fibrous /fibro-osseous tissue] and based on degree of fusion [complete/ incomplete].  
60 Kazanjian also classified it as true/false ankylosis<sup>7</sup>. True ankylosis results in osseous or fibrous

61 adhesion between surfaces of TMJ, within the limits of the articular capsule. False ankylosis results  
62 from diseases that are not directly related to the joint<sup>2</sup>.

63 Ajike and Omisakin reviewed 26 cases of ankylosis in a span of 9 years with a mean age at  
64 presentation as 14.9 years with female predilection<sup>12</sup>. Hameed et al., in their study, found gender  
65 distribution to be 60.4% males and 39.6% females<sup>13</sup>. Gupta et al., in their study, found that the most  
66 common age group for TMJ ankylosis was 11-15 years<sup>14</sup>. In all the above studies, trauma was the  
67 most frequent aetiology similar to our case.

68 Clinically, In unilateral ankylosis there is obvious facial deformity, deviation of chin towards  
69 affected side. Inability to open the jaws, absent condylar movements on affected side. In Unilateral  
70 ankylosis, the lower jaws shifts towards the affected side on opening of the mouth. Flatness or  
71 fullness on affected side. Crossbite on ipsilateral side. Class II malocclusion on affected side.

72 Radiographic evaluation is essential and critical in evaluating and treating patients with TMJ  
73 ankylosis<sup>6</sup>. The use of computed tomography is helpful to define the extent of ankylosis as well as  
74 the relationship of ankylotic mass to important associated structures<sup>5,9</sup>.

75 The principal surgical methods include simple gap arthroplasty, interpositional arthroplasty  
76 and total joint replacement with a prosthesis. A seven step protocol has been developed for the  
77 treatment of TMJ ankylosis

- 78 1. Aggressive resection of bony or fibrous ankylotic mass.
- 79 2. Dissection and stripping of temporalis muscle, scar release from the ramus and ipsilateral  
80 coronoidectomy.
- 81 3. Contralateral Coronoidectomy and stripping of the masseter, medial pterygoid and temporalis  
82 muscle.
- 83 4. New joint lining is constructed.
- 84 5. Reconstruction of the condyle with costochondral graft.
- 85 6. Rigid fixation of the graft.
- 86 7. Early mobilization and aggressive physiotherapy.<sup>15</sup>

87  
88 Treatment should be initiated as soon as the condition is diagnosed with the main objective  
89 of re-establishing joint function and harmonious jaw function<sup>16</sup>. The surgical plan for enhancing  
90 mouth opening included interpositional gap arthroplasty followed by physiotherapy It is of prime  
91 importance that physiotherapy is taken into consideration to improve the mouth, opening further and  
92 prevent re-ankylosis.

93 In the present case, chewing exercises were started on the second day after surgery, which  
94 significantly increase the degree and ease of mouth opening..In the present case there is significant  
95 improvent in the anterior- posterior position of the mandible and noticeable increase iin mouth  
96 opening since the release of ankylosis.

97

## 98 **CONCLUSION:**

99 TMJ ankylosis is one of the most frequent pathologies concerning facial skeleton. Patients  
100 afflicted with this condition bear problems ranging from limited mouth opening to psychological  
101 distress. It poses functional as well as an aesthetic problem. Since TMJ ankylosis goes unnoticed  
102 for a long period of time, early intervention is mandatory, which helps to restore physical,  
103 psychological and emotional health of the patient.TMJ examination reveals first clinical symptoms  
104 and thus help an oral physician for early diagnosis and management of the underlying multiorgan  
105 disorder.

## 106 **Legends:**

107 Fig1: patient's extraoral view showing limited mouth opening

108 Fig2: patients right lateral profile

109 Fig3: panoramic radiograph showing lack of structural organisation and reduced joint space on the  
110 right side

111 Fig 4 CT image showing obliteration of right TMJ space

112 Fig 5: Image showing resection of the ankylosing mass

113 Fig 6: mouth opening after six months: 35 mm

## 114 **REFERENCES:**

115 1. Bhat C, et al., Temporomandibular joint fibrous ankylosis-A Case report. Journal of applied dental  
116 and medical sciences 2016; 2[1]: 2454-2288.

117 2. Ankita Raj, Amrita Raj, Amit Pandey, Saket Nigam, Shailendra S. Chauhan. A  
118 temporomandibular joint ankylosis Case report. Journal of Evolution medical and dental sciences  
119 2014; 3[6]: 4155-4159

- 120 3. Srivastava H, Hegde K, Nair P, Gharote H, Gupta N, Chand PH. Temporomandibular joint  
121 ankylosis-a case of double trouble. International journal of contemporary Medicine and surgery and  
122 Radiology.2016; 1[1]:21-24
- 123 4. Rishiraj B, Mc Fadden LR Treatment of the temporomandibular joint ankylosis Case report.  
124 Journal of the Canadian Dental Association 2001; 67[11]:659-663.
- 125 5. Ortigosa C et al., Bilateral asymptomatic fibrous ankylosis of temporomandibular joint associated  
126 with rheumatoid arthritis: A Case report. Braz Dent J 2012; 23[6]:779-782
- 127 6. Miranda K, Carneiro AS et al., Treatment of atypical bifid mandibular condyle associated with  
128 ankylosis of the temporomandibular joint case reports in surgery 2019.
- 129 7. Felstead AM et al., surgical management of temporomandibular joint ankylosis in ankylosing  
130 spondylitis. International Journal of Rheumatology 2011.
- 131 8. Cheong R et al., congenital temporomandibular joint ankylosis: A case report and literature  
132 review. Case reports in otolaryngology 2016.
- 133 9. Casanova MS, Tuji FM, Ortega AI, Yoo HJ, Haiter Neto F, computed tomography of the TMJ in  
134 the diagnosis of ankylosis: two case reports. Med Oral Pathol oral cir bucal 2006; 11: E413-6
- 135 10. Ruparelia PB et al., Bilateral TMJ involvement in Rheumatoid arthritis. Case reports in dentistry  
136 2014; 1-5.
- 137 11. Sodhi A, Naik S et al., rheumatoid arthritis affecting the temporomandibular joint. Contemp Clin  
138 Dent 2015, 6[1]:124-127.
- 139 12. Ajike SO, Omisakin OO. Temporomandibular joint ankylosis in a Nigerian teaching hospital. Est  
140 Indian Med J.2011;60:172-6.
- 141 13. Hameed H, Alamger, Shad S, Din Q. Etiology, clinical features and radiological features of  
142 temporomandibular joint ankylosis. Pak Oral Dental Journal.2013; 33:26-30.

143 14. Gupta VK, Mehrotra D, Malhotra S, Kumar S, Agarwal GG, Pal US. An epidemiological study of  
144 temporomandibular joint ankylosis. Natl J Maxillofac Surg. 2012; 3:25—30.

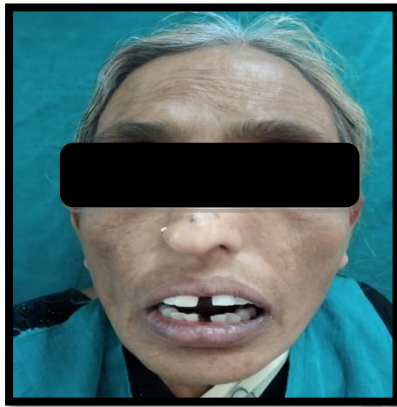145

146 15. Kaban LB, Perrott DH, Fisher K. A protocol for management of temporomandibular joint  
147 ankylosis. J Oral Maxillofac Surg 1990;48:1145-51;

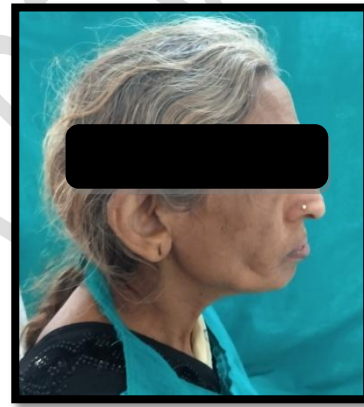148

149 16. sharad chand, Amit Gaur, Tasveer Fatima, Bharat Shukla, Gourab Das. Temporomandibular joint  
150 ankylosis in young adult. A Case report. IJSS case reports and reviews 2015; 2[1]:13-16.

151



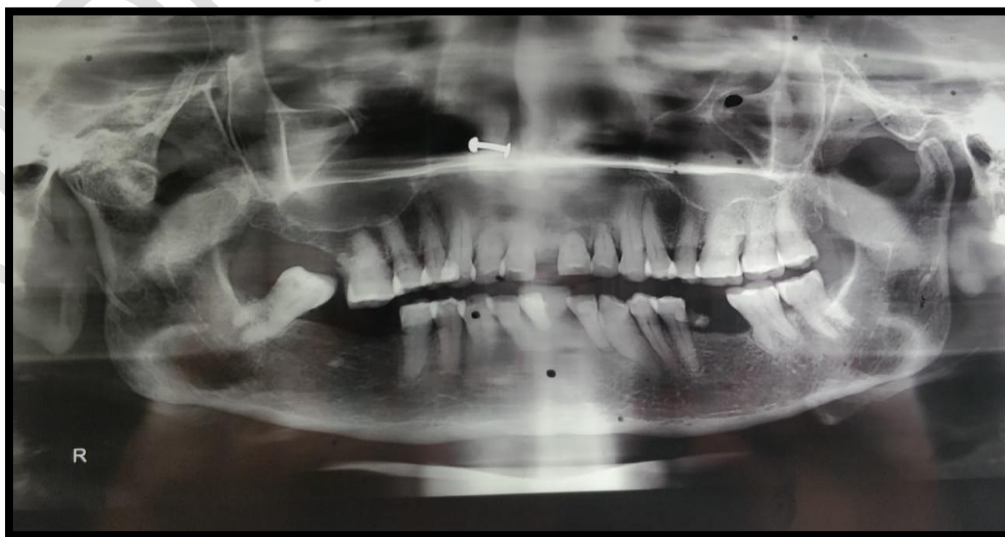152



153

Fig 1

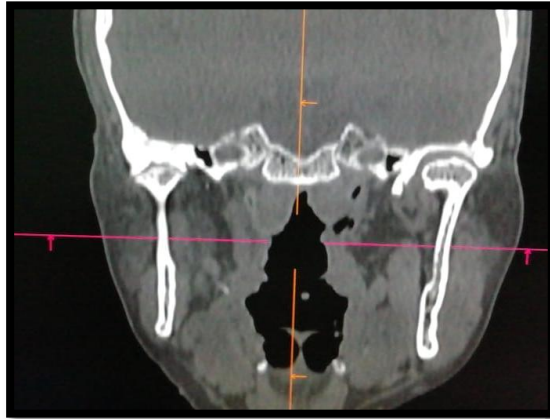
Fig 2



154

155

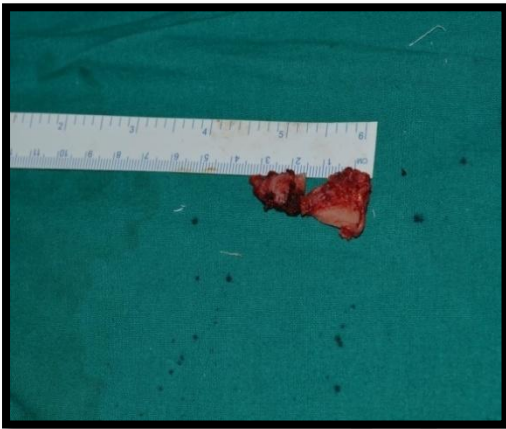Fig 3



156

157

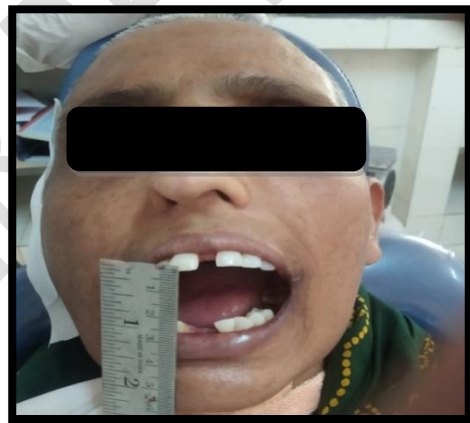Fig 4



158

159

Fig 5



160

161

162

Fig 6