

THE EFFECT OF ETHANOLIC EXTRACT OF *GARCINIA KOLA* ON THE TESTES OF ADULT MALE WISTAR RATS

ABSTRACT

Introduction: *Garcinia kola* has been used in the treatment of a wide range of diseases and its importance in folkloric medicine is eminent. This study investigated the histological effect of ethanolic extract of *G. kola* on the Testes of Male Wistar Rats.

Materials and Methods: A total of twenty (20) male Wistar rats weighing 170-240 g were used and were randomly divided into four groups of five animals each. Group A served as Control, group B received 300 mg/kg of the extract of *G. kola*, group C received 600 mg/kg of the extract of *G. kola* and group D received 900 mg/kg of the extract of *G. kola*. The treatment lasted for 28 days and on the 29th day the animals were sacrificed and their testes harvested, weighed and fixed in 10% formal saline for histological studies. Data was analysed using one-way ANOVA and SPSS version 2.0.

Results and Conclusion: There was a significant decrease ($P < 0.05$) in the relative testicular weight of animals in group D. Histopathological findings showed mild degeneration of the interstitial cell of leydig and disorganization of the seminiferous tubule in group B, group C showed moderate degeneration and arrest of spermatogenesis and moderate apoptosis of the interstitial cell of leydig while group D showed moderate to severe degeneration with severe arrest of the spermatogenesis and moderate apoptosis of the interstitial cell of leydig. Chronic administration of ethanolic extract of *Garcinia kola* has the potential of causing testicular damage and probably infertility.

Keywords: *Garcinia kola*, testes, wistar rats

INTRODUCTION

Garcinia kola belongs to the family clusiaceae/guttiferae and is found mainly in the tropical forest region of Central and West Africa (Uko et al., 2001). It is predominant in the rainforest belt of southern Nigeria (Agada and Braide 2009) and is considered a wonder plant as every part of it has been found to be of medicinal importance (Burkill, 1985). *G. kola* is commonly called as “bitter kola” because of its bitter taste or “male kola” due to its aphrodisiac properties (Iwu et al., 1999). In Nigeria it is called “Orogbo” in Yoruba, “Aku ilu” in Igbo and “Namijin goro” in Hausa (Burkill, 1985). It is a highly desired product due to its highly perceived medicinal attributes and the fact that it does not result in indigestion when consumed in high quantity (Dalziel 1937).

The plant is used in folklore remedies for the treatment of ailments such as liver disorder, diarrhoea, laryngitis, bronchitis, and gonorrhea (Charity et al., 2012). Iwu et al. (1999) also reported the usefulness of the plant in the treatment of jaundice, high fever and as purgative. The seed is masticatory and used to prevent and relieve colic, chest colds, and cough and can as well be used to treat headache. Kolaviron, the predominant constituent in *G. kola* seeds, contains biflavanones (GB1, GB2 and kolaflavanone) and has been reported to prevent hepatotoxicity mediated by several toxins (Akintonwa and Essien 1990; Farombi et al., 2005). The plant's nut contains a high proportion of tannins and guttiferin (Etkin, 1981). Previous studies have shown *G. kola* to have neuroprotective effect (Adeshina et al., 2012), sexual enhancement (Uko et al., 2001), hepatoprotective activity (Alade and Ani, 1990), increase in testosterone production due to its antioxidant properties (Isaac et al., 2013).

Sexual health is an important component of an individual's quality of life and well-being (WHO, 2000). Unfortunately, it is a problem often neglected by the health practitioners as they strive to deal with life threatening complications of disease. The chronic consumption of *G. kola* has for long been traditionally claimed to improve sexual performance in men among other benefits (Iwuji and Herbert, 2015). However, there is need to investigate the histological effect of *G. kola* on testes on male wistar rats.

MATERIALS AND METHODS

ANIMALS

Twenty (20) adult Male Wistar Rats weighing 170-240g were procured from the animal house of the Department of Anatomy, Nnamdi Azikiwe University, Anambra State. The animals were kept in standard cages at a room temperature of $27\pm 2^{\circ}\text{C}$ and maintained with normal laboratory chow (Grower feed) and water *ad libitum*. They were acclimatized for a period of two weeks before administration of ethanolic extract of *G. Kola* seed which lasted for a period of 28 days. The animals were kept on 12hours light and dark cycles. Ethical approval on animal act right was obtained from the University animal care committee which is in compliance with the National regulation for animal research.

PREPARATION OF G. KOLA SEED EXTRACT

G. kola seed was obtained from a local market in Nnewi, Anambra state and authentication was confirmed by the herbarium officer of Botany Department, Nnamdi Azikiwe University, Awka, Anambra State.

The outer coats were removed and the seed washed in running tap water in a basin to remove dirt, cut into pieces and were air dried under ambient temperature. The dried seeds were ground into coarse powder using local grinder. 50 g of the dried seed was macerated in 1000 ml of 95% ethanol for 48 hours and then filtered using Whitman No 1 filter paper. The filtrate was concentrated using a rotatory evaporator and was further dried using a laboratory oven at 45°C into a gel-like form. The extract was preserved in a refrigerator at 4°C for further usage.

ADMINISTRATION OF THE EXTRACT

The extract was administered orally, once daily between 6 am to 8 am and lasted for a period of 28 days. The animals were divided into four groups of five rats each. Group A served as Control and received only distilled water and laboratory chow, Group B received 300 mg/kg of the ethanolic extract of *G. kola*, Group C received 600 mg/kg of the ethanolic extract of *G. kola* and Group D received 900 mg/kg of the ethanolic extract of *G. kola*. The animals were anaesthetized with diethyl ether in an enclosed container after 24 hours of the last administration. The testes were harvested, weighed and stored in 10% formal saline for histological analysis.

Histological Analysis

The testes from the control and treated animals were fixed in 10% formal saline. The tissues were processed by passing them through ascending grades of alcohol and then cleared in xylene after which embedding in paraffin wax was carried out. 3-5µm of the sections was obtained using rotatory microtome. The sections were deparaffinised, hydrated and stained using haematoxylin and eosin (H&E) dye. They were later mounted using neutral dibutylphthalate xylene (DPX) medium for microscopic examination at x400 magnification.

Statistical Analysis

Data was analysed using Statistical Package for Social Sciences (SPSS) software (V20, USA). The results were presented as Mean \pm standard error of mean (SEM). One way Analysis of Variance (ANOVA) was used to determine the significance of difference in the means of all parameters. Post-hoc Fisher's LSD multiple comparison was done and data were considered significant at $P < 0.05$.

RESULTS

Analysis of the testicular weight (**Table 1**) showed a statistically significant decrease ($P < 0.05$) in group D compared to other groups. However, there was an increase in group C but not significant ($P > 0.05$) when compared to the control.

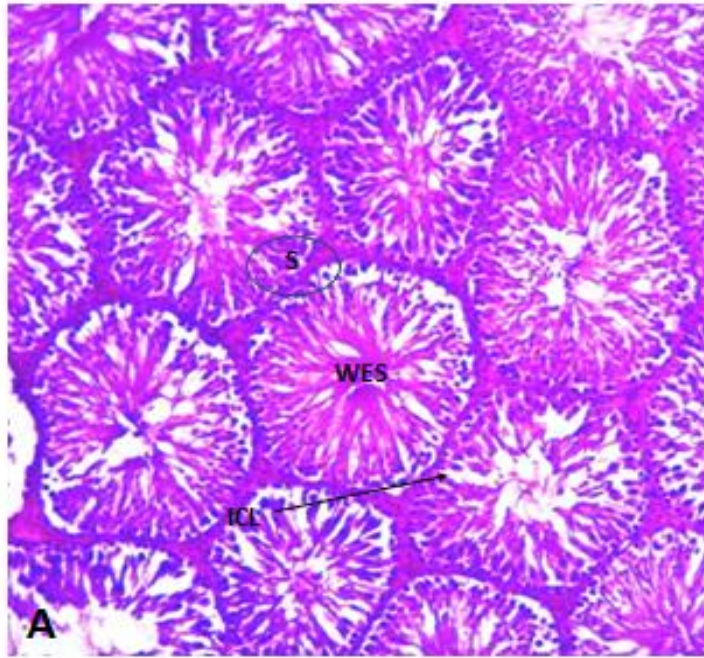
Table 1: The effect of ethanolic extract of *G. kola* seed on testicular weight.

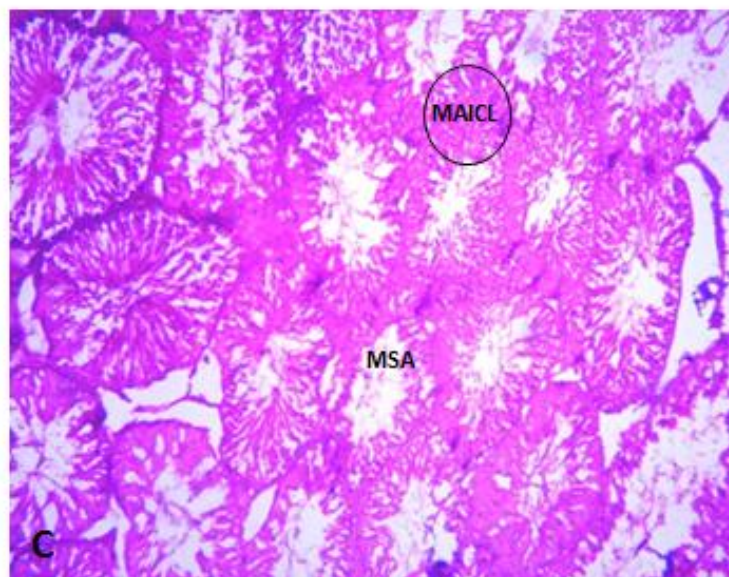
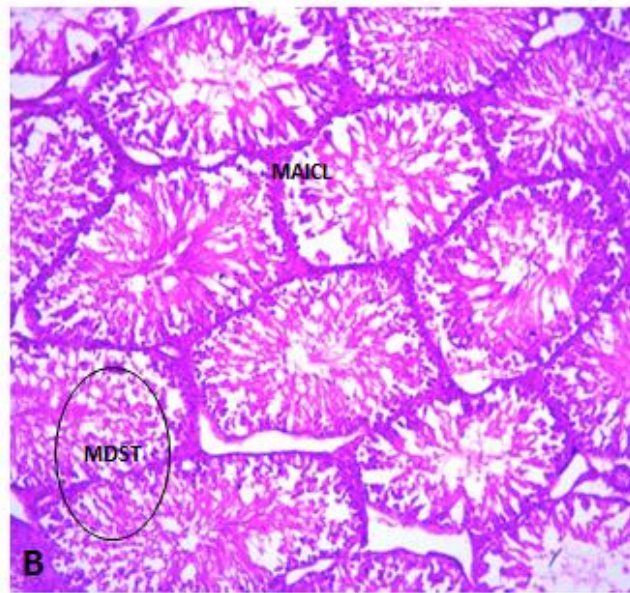
GROUPS		MEAN \pm SEM	P-VALUE	F-VALUE
Relative Testicular weight (g)	Group A	1.37 \pm 0.13		
	Group B	1.33 \pm 0.01	0.743	
	Group C	1.47 \pm 0.09	0.435	47.908
	Group D	0.25 \pm 0.01	0.000*	

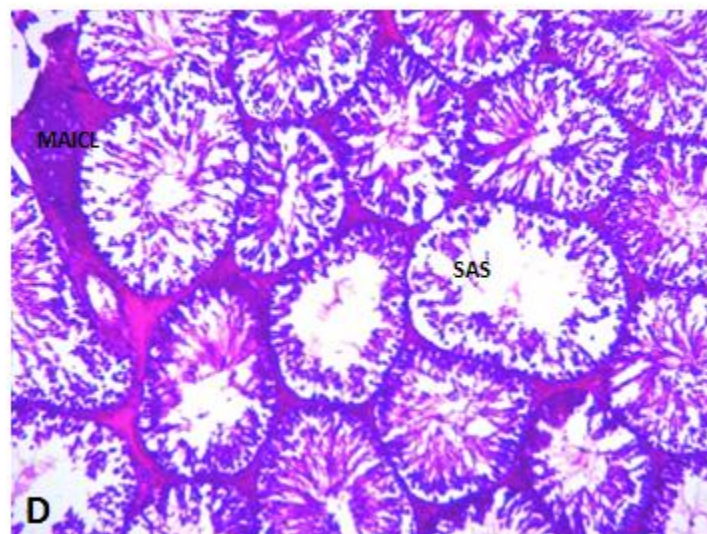
*= $P < 0.05$

Photomicrograph sections of the testes in Group A showed normal testicular architecture with seminiferous tubule (S) that are lined with interstitial cells of the leydig (ICL) and well enhanced spermatogenesis (WES). The overall feature appears normal (**Plate A**). Group B administered with 300 mg/kg of *G. Kola* showed mild degeneration with mild apoptosis of the interstitial cell of leydig

(MAICL) and mild disorganization of the seminiferous (MDST) (**Plate B**). Group C administered with 600 mg/kg of *G. Kola* showed moderate degeneration with moderate arrest of the spermatogenesis leydig (MAS) and moderate apoptosis of the interstitial cell of leydig (MAICL) (**Plate C**). Group D administered with 900 mg/kg of *G. Kola* showed moderate to severe degeneration with severe arrest of the spermatogenesis (SAS) and moderate apoptosis of the interstitial cell of leydig (MAICL) (**Plate D**).







DISCUSSION

Infertility is a global problem, with a global prevalence rate of 10.5% and second most prevalent health care problem in sub-Saharan Africa (Chinnoch, 1996).

Findings from table 1 showed that the extract caused a significant reduction in testicular weight administered at high dose; the reason for this decrease is not well understood. This is in agreement with that of Agbai et al (2013) who reported a dose dependent decrease in testicular weight after administration of 100, 200 and 300 mg/kg body weight of *G. kola*. However, this result contradicts the reports of Hope et al., (2016) who reported a no effect on the testicular body mass following administration of *G. kola*. Ralebona et al (2012) also reported that 200 mg/kg and 400 mg/kg of ethanolic extract of *G. kola* caused a significant increase in testicular weight with no significant change in the weights of accessory reproductive organs.

Histopathological findings from this study revealed that chronic consumption of ethanolic extract of *G. kola* seed caused disorientation of the cytoarchitecture of the testes. It has been reported that components of *G. kola* seeds exerts toxic effects on the sertoli cells which also interferes with spermatogenesis (Naiho, 2004). It is possible that these components could also have impact on the leydig cells. This study corresponds with the work of Ofoego et al., (2015) who reported a slight disorientation and interstitial congestion of the cells, and normal interstitial space with few numbers of matured spermatozoa and regeneration of the germinal epithelium following administration of ethanolic Extract of *G. kola*. It is also in line with Isaac et al., (2013) who reported that ethanolic extract of *G. kola* did not prevent the toxic effect of lead on the seminiferous tubular cells rather it worsened the toxic effect after two weeks of administration.

CONCLUSION

In conclusion, the investigation revealed that chronic consumption especially at higher doses of ethanolic extract of *G. kola* seed could result to testicular damage and probably lead to infertility.

ETHICAL APPROVAL

All authors hereby declare that principles of laboratory animal care (NIH publication No. 85-23, revised 1985) were followed as well as specific national laws where applicable. All experiments have been examined and approved by the appropriate ethics committee.

REFERENCES

- ADESHINA, J., FAKUNLE, P.B. and SHITU O., 2012. Neuroprotective effect of Aqueous Extract of *Garcinia Kola* on monosodium glutamate induced cerebellar cortical Damage in Adult Wistar Rats. *European Journal of Medicinal Plants*. Vol. 5, no. 1, pp. 13 -22.
- AGADA, P.O., and BRAIDE, V.B., 2009. Effect of dietary *Garcinia kola* seed on selected serum electrolytes and trace metals in male albino rats. *Nigerian Journal of Physiological Sciences*. Vol. 24, no. 1, 53-57.
- AGBAI E.O., OFOEGO U.C., NWANEGWO C.O., NWODO F.N. (2013). Increased doseconcentration of ethanolic extract of *Garcinia kola* seed impairs reproductivefunction in adult male albino wistar rats. *Journal of Science andMultidisciplinary Research*, 5(1): 197-210
- AKINTOWA, A., and ESSIEN A. R., 1990. Protective effects of *Garcinia kola* seed extract against paracetamol-induced hepatotoxicity in rats. *J. Ethnopharmacol*. Vol. 29, pp. 207-211
- AKPANTAH, A.O., OREMOSU, A.A., NORONHA, C.C., EKANEM, T.B. and OKANLAWON, A.O., 2005. Effects of *Garcinia kola* seed extract on ovulation, oestrous cycle and foetal development in cyclic female sprague - Dawley rats. *Nigerian Journal of Physiological Sciences*. vol. 20, no. 1, pp. 58-62.
- ALADE, A. and ANI, R. E., 1990. Protective effects of *Garcinia kola* seed extract against paracetamol-induced hepatotoxicity in rats. *Journal of ethnopharmacology*. Vol. 29, no. 2, pp. 207–211.
- CHARITY, U.O., UWAIFOH, A., CHARLSE, I.I., WILLIAMS, A. A. and KERRY, E.A., 2012. The effect of chronic ingestion of crude *Garcinia kola* on the histology of the liver. *Pelagia Research Library European Journal of Experimental Biology*, vol. 2, no. 2, pp. 404-409.
- CHINNOCH, P., 1996. Reproductive health. *African Health*, vol. 18, pp. 3-19.
- DALZIEL, J.M. 1937. The useful plants of west tropical Africa, being an appendix to the flora of West Africa

- by Hutchinson, J and J.M. dalziel. The crown Agent for the colonies
- BURKILL, H.M., 1985. The Useful Plants of West Tropical, volume 4. 2nd ed. Royal Botanical Gardens
- ETKIN, N.L. 1981. A Hausa herbal pharmacopoeia: biomedical evaluation of commonly used plant medicines. J. Ethnopharmacol. Vol. 4, pp. 75-98.
- FAROMBI, E.O., ADEPOJU, B.F., OLA-DAVIES, O.E. & EMEROLE, G.O., 2005. Chemoprevention of aflatoxin B1-induced genotoxicity and hepatic oxidative damage in rats by kolaviron, a natural biflavonoid of *Garcinia kola* seeds. - European Journal of Cancer Prevention vol.14, no. 3, pp. 207-214.
- HOPE, K.O., CHURCHILL, J.I., and GODWIN, N., 2016. Effects of *Garcinia Kola* Extract on the Testicular Sperm Reserve of Adult Male Guinea Pig *The FASEB Journal* vol. 30, no.1, pp. 23.
- ISAAC, J.A, AJADI, M.B and AKINLOYE, O., 2013. Modulatory effects of kolaviron (*Garcinia kola* extract) on spermogram and reproductive system of adult male wistar rats in lead acetate induced toxicity. Journal of Toxicology and Environmental Health Sciences Vol. 5, no. 7, pp. 121-130
- IWU, M.M., DUCAN, A.R. and OKUNJI, C.O., 1999. New antimicrobial of plant origin. In: J. Janick, eds. Perspective on new crops and new uses. Alexandria, ASHA press, pp. 457 -621.
- IWUJI, T.C. and HERBERT, U., 2015. Haematological and serum biochemical characteristics of rabbit bucks fed diets containing *G. kola* seed meal. Journal of Natural Resources Research.vol. 5, no. 3, pp. 79-84
- OFOEGO, U.C., OLEWUIKE, C.G., EZEJINDU, D.N., EKWUJURU, E.U. and AKUDIKE, C.J., 2015. The Effect of Ethanolic Extract of *Garcinia Kola* on the Sperm Parameters and Histology of the Testis of Male Wistar Rats. Advances in Life Science and Technology. Vol.33, pp. 2224-7181.
- RALEBONA N, SEWANI-RUSIKE C.R., NKEH-CHUNGAG B.N. (2012).Effects of ethanolic extract of *Garcinia kola* on sexual behaviour and sperm parameters in male Wistar rats. African Journal of Pharmacy and Pharmacology, 6(14): 1077 – 1082. Selmanoglu, G., Hayretdags, K., Tuylu, A.O. and Sorkun, K. (2009). The effect of pollen on some reproductive parameters of male rats. PesticPhytomed, 24, 59-63
- NAIHO .A.O. (2004). Effects of *Garcinia kola* on the reproductive organ weight and histology of the testis and anterior pituitary gland of Wistar rats. J. Expt. & Clin. Anat. (3): 20-23.
- UKO, O.J., USMAN, A. and ATAJA, A.M., 2001. Some biological activities of *Garcinia kola* in growing rats. Veterinarski Arhiv. Vol. 71, 287-297.
- WORLD HEALTH ORGANISATION., 2000. Guidelines to promote proper use of alternative medicinal fact sheet No 164 and 204.

UNDER PEER REVIEW