

Medullary thyroid carcinoma metastatic to the breast: Case report

ABSTRACT

Aims: To spot the light on metastatic tumors to the breast to avoid misdiagnosis as primary breast tumors.

Presentation of the case: 45-year-old female was referred to the Oncology Department of Meet Ghmmr Oncology Center in November 2017 after total thyroidectomy followed by cervical lymph node dissection for medullary thyroid carcinoma (MTC) 1 year ago at Oncology Center Mansoura University. The panel recommended postoperative radiotherapy. One month after the end of radiotherapy, she complained of frequent headache attacks and abdominal pain. CT was done in February 2018 revealed metastasis to the brain, lung, liver and ovaries. After the fifth cycle of chemotherapy, a progressively enlarging left breast mass appeared, that proved to be metastatic MTC.

Discussion: MTC is a neuroendocrine tumor of the thyroid gland. Breast is an unusual metastatic site for MTC. Consequently, breast masses should be evaluated with caution, especially in the presence of a known primary malignancy. Histopathologic examination is the key diagnostic tool.

Conclusion: Metastasis to the breast should be considered in the differential diagnosis of a breast mass in a patient with a past history of MTC. Histopathologic examination and proper panel of immunohistochemical markers are fundamental for diagnosis to prevent unneeded surgery.

Key words: thyroid, breast, medullary, metastasis, carcinoma.

INTRODUCTION

Metastatic disease of the breast is usually secondary to malignancy in the contralateral breast. However, it is more prevalent in malignant lymphoma, malignant melanoma, and lung cancer [1]. However, the incidence of any metastasis to the breast is rare, comprising only 0.5–1.5% of breast malignancies [2]. The incidence of breast metastases may be underdiagnosed, with an autopsy series, the incidence was closer to 6% [3]. It has been reported that the rarity of metastases to the breast may be due to the replacement of the glandular tissue with connective or adipose tissues with corresponding reduction in blood flow, at the age when cancer development is most likely. On the contrary, primary breast carcinoma commonly metastasizes to the thyroid gland [4]. MTC is a neuroendocrine tumor that arises from parafollicular C cells. It is either of a sporadic fashion or inherited, which is related to germline mutations of the RET gene. Metastasis is commonly the first presentation, frequently within the neck lymph nodes, followed by the liver, lungs, and bones [5].

We present a case of a 45-year-old female presenting with a lump in the breast, which was later diagnosed as a metastasis from MTC.

CASE PRESENTATION

This is a case of 45-year-old female was referred to the Oncology Department of Meet Ghmmr Oncology Center in November 2017 after total thyroidectomy followed by cervical lymph node dissection for MTC 1 year ago at Oncology Center Mansoura University. The pathological examination

of the thyroid gland (figure 1) revealed tumor tissue arranged in nests and cords in vascular stroma. The neoplastic cells are rounded, plasmacytoid and polygonal. They have round vesicular nuclei with low mitotic figures surrounded by amphophilic cytoplasm. Lymphovascular invasion was detected. IHC was done; the neoplastic cells show positive reaction for TTF-1, calcitonin, synaptophysin, chromogranin and CEA. Thyroglobulin was negative. The diagnosis of MTC was confirmed. The cervical lymph nodes revealed metastatic deposits by similar tumor tissue.

The panel recommended postoperative radiotherapy to neck and mediastinum. This patient had no family history of MTC and no other tumors suggesting being a case of Multiple Endocrine Neoplasia syndrome. One month after the end of radiotherapy, she complained of frequent headache attacks and abdominal pain. CT scan was done in February 2018 revealed metastasis of brain, lung, liver and ovaries. She started a chemotherapy protocol of cyclophosphamide 750mg/m² on day 1, vincristine 1.4mg/m² day 1 and decarbazine 600mg/m² on day 1&2. The protocol was given every 4 cycles for 3 cycles. After 3 cycles all the lesions disappeared and so further 3 cycles were recommended.

After the fifth cycle, a progressively enlarging left breast mass appeared, from which needle biopsy was done. Sections showed monotonous rounded tumor cells, which were arranged in cords and in targetoid manner around uninvolved mammary ducts. Carcinoma in situ either ductal or lobular were not detected (Figure 2). Considering the patient past history, metastasis from MTC was suspected. However, lobular carcinoma of the breast could not be excluded. Further IHC was done (figure 3). The neoplastic cells were positive TTF-1, calcitonin, synaptophysin, chromogranin. On the other hand, it was negative for mammaglobin excluding mammary carcinoma. Consequently a diagnosis of metastatic MTC to the breast was concluded. Unfortunately, progressive deterioration of the patient general condition happened and she died in October 2018.

DISCUSSION

MTC is a neuroendocrine tumor of the thyroid gland arises from the para follicular C cells which secrete calcitonin. It accounts for 5-8% of all thyroid cancers. MTC occurs in two settings; sporadic and hereditary pattern. Hereditary MTC represent about 20 – 30% usually in the setting of multiple endocrine neoplasia type 2 (MEN 2) due to germline mutations of the RET proto-oncogene [6].

Metastasis to regional lymph nodes usually present at the time of diagnosis [7] [8]. Distant metastases outside the neck may occur in the liver, lungs, bones and, less frequently, brain and skin. Persistent hypercalcitonemia after thyroidectomy and lymph node dissection is highly related to occult distant metastases [6] [13].

Mandanas et al (2015) had performed through search on MTC metastatic to the breast in the literature. They found that 20 cases have been documented [9].

The histopathologic features of MTC are variable. It is formed of round, plasmacytoid, polygonal or spindle cells arranged in nests, cords or follicles. They have round nuclei with fine chromatin and indistinct nucleoli. The cytoplasm is amphophilic and granular. Stromal amyloid deposition and lymphovascular invasion are common. Necrosis and hemorrhage are infrequent except in large tumors. Psammoma-like bodies and mucin production can be found. As regards IHC profile, MTC cells are positive for TTF-1, calcitonin, CEA and neuroendocrine markers as chromogranin and synaptophysin. MTC cells are negative for thyroglobulin [14] [15].

Metastatic tumors of the breast are usually presented as solitary mass. There are no reliable clinical criteria to differentiate metastatic tumors from primary breast cancer. However, on literature review, a superficial circumscribed lesion in upper outer quadrant of breast with skin tethering or multiple superficial hard nodular masses should raise the concern of secondary tumor. Clear clinical history of the patient will make it easier to suspect and subsequently confirm the metastatic nature of the breast mass [10] [11].

Imaging findings are similar to those of benign tumors [12]. It is the fundamental role of the pathologist to accurately diagnose metastatic tumors to the breast to avoid unneeded surgery. The

retention of the normal histological structure of the mammary gland and lack of ductal or lobular tumors in pathological specimens are key features. Complementary IHC study can confirm the diagnosis. Both mammaglobin and GATA3 are specific markers for normal mammary tissue and primary breast carcinoma unlike the lack of staining in the metastatic tumors [18].

Concerning the medical treatment plan of our case, response to cytotoxic drugs were not durable which is in accordance with literature [16]. Cytotoxic drugs based on decarbazine achieve acceptable toxicity profile and disease stabilization without long lasting marvelous responses [16]. Although the use of tyrosine kinase inhibitors is encouraged by treatment guidelines [17]. Inavailability at Meet Ghmmr Oncology Center did not allow their use.

CONCLUSION

Metastasis to the breast from MTC is very rare. It should be considered in the differential diagnosis of a breast mass in a patient with history of MTC. Normal mammary histology and absence of carcinoma in situ are important features to be noted. Proper panel of IHC markers can lead to a correct diagnosis and prevent unneeded surgery.

DECLARATION OF PATIENT CONSENT

Written consent was obtained from the patient for publication of this case report.

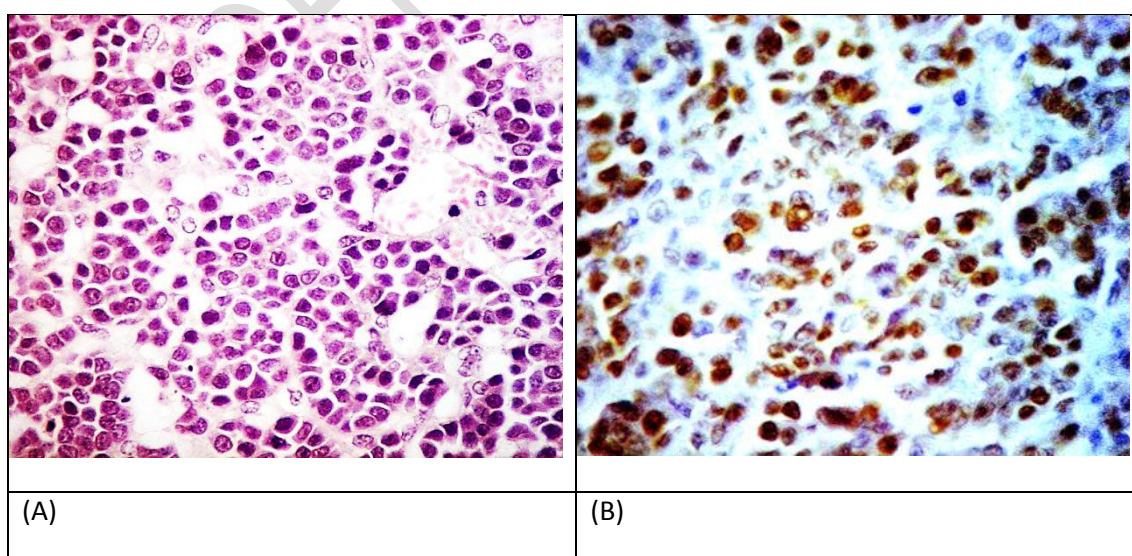
CONFLICTS OF INTEREST

The authors declare that there are no conflicts of interest.

REFERENCES

1. Akcay MN. Metastatic disease in the breast. *The Breast*. 2002 Dec 1;11(6):526-8.
2. Hajdu SI, Urban JA. Cancers metastatic to the breast. *Cancer*. 1972 Jun;29(6):1691-6.
3. Di Bonito L, Luchi M, Giarelli L, Falconieri G, Viehl P. Metastatic tumors to the female breast: an autopsy study of 12 cases. *Pathology-Research and Practice*. 1991 May 1;187(4):432-6.
4. Magers MJ, Dueber JC, Lew M, Pang JC, Davenport RD. Metastatic ductal carcinoma of the breast to the thyroid gland diagnosed with fine needle aspiration: a case report with emphasis on morphologic and immunophenotypic features. *Diagnostic cytopathology*. 2016 Jun;44(6):530-4.
5. Gajdzis M, Cassoux N, Lesnik M, Hoffmann C, Badois N, Gajdzis P, Klijanienko J. Intraocular metastasis of medullary thyroid carcinoma investigated by transscleral fine-needle aspiration. A case report and review of the literature. *Diagnostic cytopathology*. 2018 Sep;46(9):764-8.
6. Pacini F, Castagna MG, Cipri C, Schlumberger M. Medullary thyroid carcinoma. *Clinical oncology*. 2010 Aug 1;22(6):475-85.
7. Lupone G, Antonino A, Rosato A, Zenone P, Iervolino E, Grillo M, De Palma M. Surgical strategy for the treatment of sporadic medullary thyroid carcinoma: our experience. *Il Giornale di chirurgia*. 2012;33(11/12):395-9.

8. Meng K, Luo H, Chen H, Guo H, Xia W. Prognostic value of numbers of metastatic lymph node in medullary thyroid carcinoma: A population-based study using the SEER 18 database. *Medicine*. 2019 Jan;98(1).
9. Mandanas S, Margaritidou E, Christoforidou V, Karoglou E, Geranou C, Chrisoulidou A, Boudina M, Georgopoulos K, Pazaitou-Panayiotou K. Breast metastasis from medullary thyroid carcinoma in a male patient: case report and review of the literature. *Rare Tumors*. 2015 May 18;7(2):60-3.
10. Ali SZ, Teichberg S, Attie JN, Susin M. Medullary thyroid carcinoma metastatic to breast masquerading as infiltrating lobular carcinoma. *Annals of Clinical & Laboratory Science*. 1994 Sep 1;24(5):441-7.
11. Lee AH. The histological diagnosis of metastases to the breast from extramammary malignancies. *Journal of Clinical Pathology*. 2007 Dec 1;60(12):1333-41.
12. Vizcaino I, Torregrosa A, Higuera V, Morote V, Cremades A, Torres V, Olmos S, Molins C. Metastasis to the breast from extramammary malignancies: a report of four cases and a review of literature. *European radiology*. 2001 Sep 1;11(9):1659-65.
13. Algeciras-Schimmich A, Preissner CM, Theobald JP, Finseth MS, Grebe SK. Procalcitonin: a marker for the diagnosis and follow-up of patients with medullary thyroid carcinoma. *The Journal of Clinical Endocrinology & Metabolism*. 2009 Mar 1;94(3):861-8.
14. Tanwar P, Gandhi JS, Sharma A, Gupta M, Choudhary PS. Unusual metastasis of medullary thyroid carcinoma to the breast: A cytological and histopathological correlation. *Journal of cytology*. 2018 Apr;35(2):117.
15. Gardair C, Drabent P, Charveriat P, Bertheau P, Cahen-Doidy L. A misleading breast metastasis of medullary thyroid carcinoma. In *Annales de pathologie* 2019 Feb (Vol. 39, No. 1, pp. 9-13).
16. Wu LT, Averbuch SD, Ball DW, De Bustros A, Baylin SB, McGuire III WP. Treatment of advanced medullary thyroid carcinoma with a combination of cyclophosphamide, vincristine, and dacarbazine. *Cancer*. 1994 Jan 15;73(2):432-6.
17. Trimboli P, Castellana M, Virili C, Giorgino F, Giovanella L. Efficacy of Vandetanib in treating locally advanced or metastatic medullary thyroid carcinoma according to RECIST criteria. A systematic review and meta-analysis. *Frontiers in endocrinology*. 2018;9:224..
18. Sangoi AR, Shrestha B, Yang G, Mego O, Beck AH. The novel marker GATA3 is significantly more sensitive than traditional markers mammaglobin and GCDFP15 for identifying breast cancer in surgical and cytology specimens of metastatic and matched primary tumors. *Applied immunohistochemistry & molecular morphology: AIMM*. 2016 Apr;24(4):229.



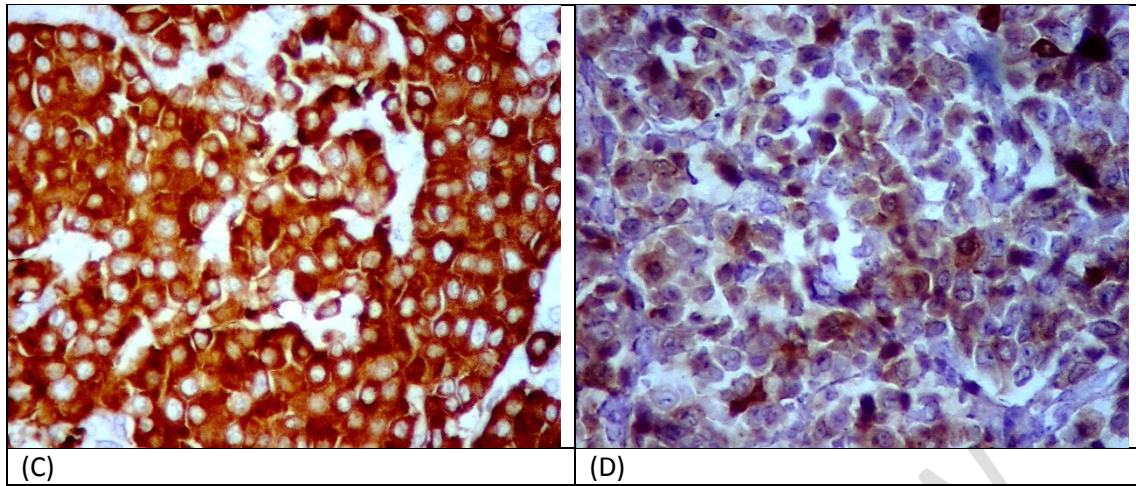


Figure 1: Thyroid gland tumor. 1. Nests and cords of neoplastic cells in vascular stroma (H&E). B nuclear staining for TTF-1. C cytoplasmic staining for synaptophysin. D cytoplasmic staining for calcitonin.

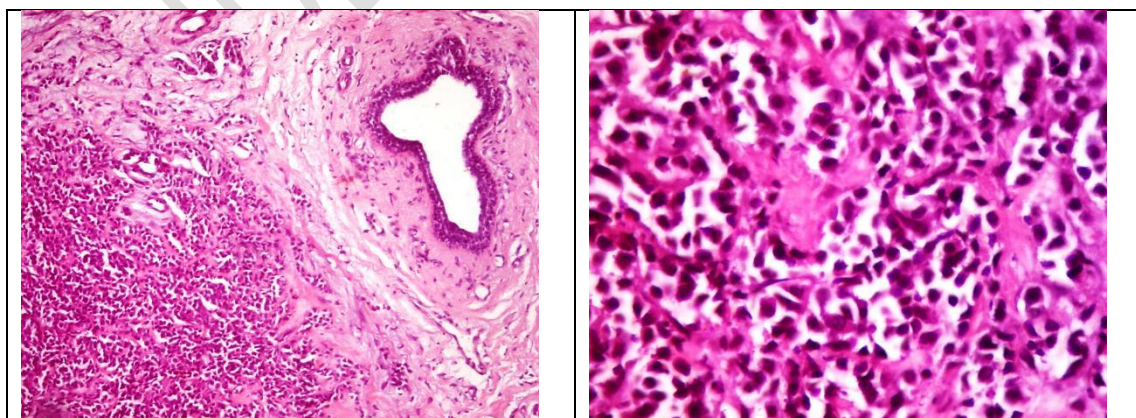


Figure 2: Metastatic breast tumor (H&E).

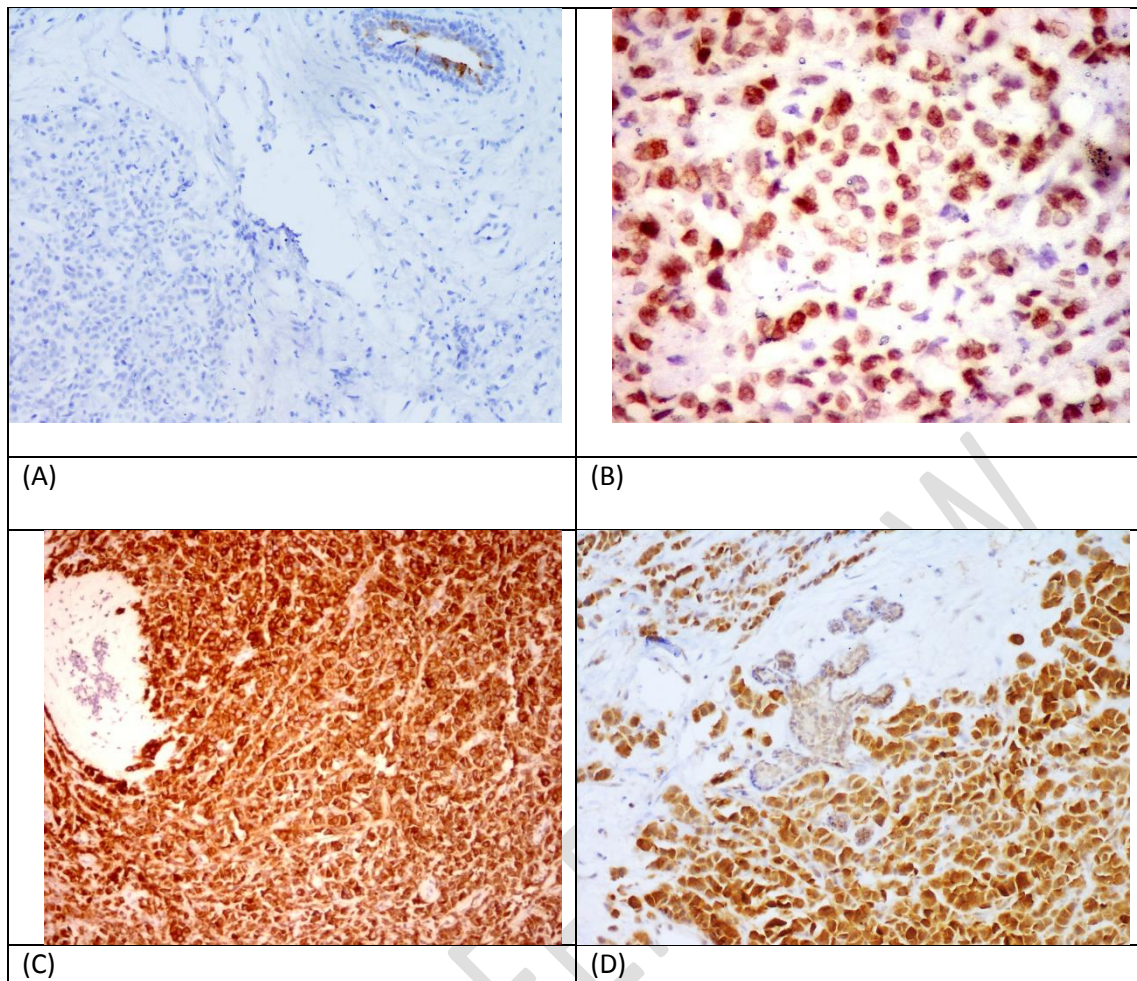


Figure 3: IHC markers of metastatic breast tumor. 3. Neoplastic cells are negative for mammaglobin. Mammary epithelium are positive. B nuclear staining for TTF-1. C & D cytoplasmic staining of the neoplastic cells for synaptophysin & calcitonin in contrast to negative mammary epithelium.