

Unilateral weakness and areflexia in a child diagnosed to have Pseudo-tumoral acute hemi-cerebellitis.

Abstract

Acute hemi-cerebellitis is an inflammatory condition, that's self-limited disease with good prognosis, which does not need treatment in most of the cases. Here we describe a child diagnosed to have acute hemi-cerebellitis with atypical presentation inform of unilateral weakness and areflexia, which never been reported before up to our knowledge.

Introduction

Acute hemi-cerebellitis is an inflammatory condition, and it is extremely rare in children. It is clinically present with headache, meningism and sometimes cerebellar signs. MRI appears with focal or diffuse signal changes in one cerebellar hemisphere with or without cerebellar swelling that may looks like a tumor radiologically (1, 2). The etiology is unknown, it can be caused by a primary infection, post-infectious or post

vaccination disorder. The most common infectious agents are varicella, measles, mumps and rubella(3, 4). It has a benign course, and a significant clinical improvement that has been noticed even in the absence of treatment, with an excellent regression radiologically (2). However, a few cases were reported to undergo a surgical intervention due to brainstem compression or acute hydrocephalus (5-7). Acute cerebellar ataxia and acute cerebellitis are another entity with an overlap between both of them. The acute cerebellar ataxia characterized by truncal, appendicular, and gait ataxia, nystagmus, dysarthria, and hypotonia. It happens suddenly and resolve over time with normal neuro-image. Unlike acute cerebellitis, it is more severe with less favorable prognosis and abnormal neuro-image, clinically it appears with altered level of consciousness, hydrocephalus, raised intracranial pressure, and focal neurological deficit (8). In fact, the acute

hemi-cerebellitis considered as variant of acute cerebellitis but unilateral.

Case Presentation

Four years old girl medically free presented with irritability, vomiting, fever and right side weakness for seven days. The vomiting and the fever continued for three days then resolved and the right-side weakness started affecting her upper and lower limbs, she could not bear weight by herself, only with support. The weakness over four days was progressing, then became static. Reaching the point that she cannot raise her arm above her shoulder. She was most of the time crying, refuse any one to come close to her, not distracted by her toys as before. The following aspects of history were unremarkable including: upper respiratory tract infection symptoms, contact with sick patient, or animals, abnormal movement, or loss of consciousness, cyanosis or shortness of breath, fecal or urinary incontinence, trauma. Her immunization: was complete. Developmentally: she has normal motor and cognitive function for her age. Nutritional, allergy and family history were unremarkable.

On examination: Vital signs were all normal. She looks well, not in distress but irritable. There were no meningeal sings. Her cranial nerve examination was normal. Her motor examination showed: Upper limb right: 3/5, Upper limb left: 5/5, Lower limb right: 4/5, Lower limb left: 5/5, her tone was normal in the left side, but reduced in right side. There is an absent knee reflex bilateral and an equivocal planter response, her gait was unsteady with drift to the right side, sensory examination was unremarkable.

Our differential diagnosis include meningitis, vasculitis, arterial stroke, deep venous thrombosis, tumor, and ADEM (Acute disseminated encephalomyelitis).

The patient was admitted and a full septic work up was done including lumber puncture. Then she started on antibiotics. Over the whole period of admission, she was vitally stable and afebrile. Later, her cultures came to be negative, so the antibiotics were discontinued.

NCS was normal, MRI brain and spine showed: unilateral right cerebellar abnormal FLAIR and T2 signal intensity with cortical swelling. No enhancement post-contrast administration. Most likely representing pseudo-tumoral hemi-cerebellitis (figure 1).

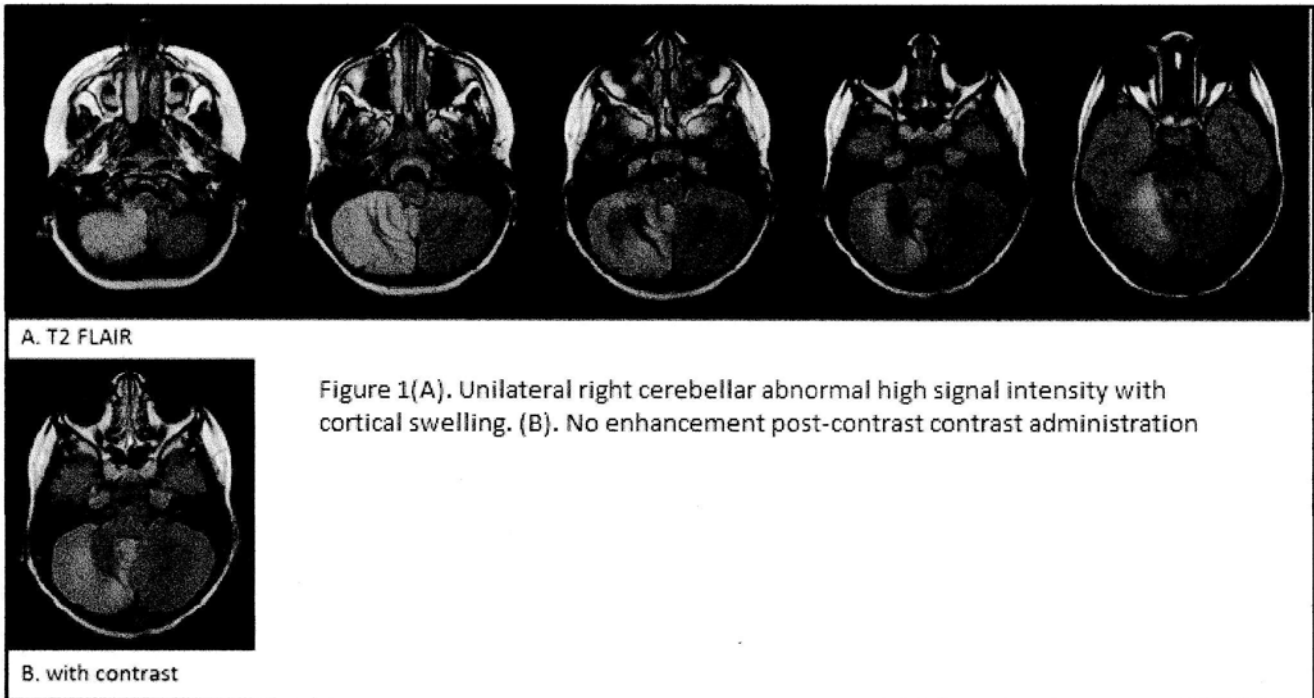
Patient had significant clinical improvement with help from physiotherapy and occupational therapy.

Her other parts of investigations like; CBC, chemistry, renal profile, liver profile, ESR, CRP, ASOT, CPK, toxicology screen, all unremarkable, CSF showed normal white blood cell, protein, and glucose. Viral study from blood was negative for Measles, Rubella, hepatitis, Varicella-zoster virus, Brucella Abortus/Brucella Melitensis, Cytomegalovirus, Epstein-Barr virus, Herpes simplex virus one and two. Viral study from nasopharyngeal aspirate was also negative for Influenza A Virus, Influenza B Virus, Human Adenovirus, Parainfluenza virus 1, Parainfluenza virus 2, Parainfluenza virus 3, Parainfluenza virus 4, Human Rhinovirus, Respiratory Syncytial Virus A, Respiratory Syncytial Virus B, Metapneumovirus, Human Coronavirus 229E, Human Coronavirus NL63, Human

Coronavirus OC43, Human Bocavirus (HBoV), and Human Enterovirus (HEV).

After approximately 1 week the patient were discharged with significant improvement, and she was seen after 2

weeks in the clinic, the patient was completely back to her baseline with normal neurological examination.



Discussion.

Our patient had unique presentation of the disease, in form of: unilateral weakness and areflexia. It has been postulated to divide the clinical presentation into two categories, the first one is cerebellar signs including ataxia, dysarthria, diplopia, nystagmus, intentional tremor, dysmetria and headache, and the second one is headache with other signs related to increased intracranial pressure but no cerebellar signs, the first group represent the majority in around 71.4% of the patients, the second group it accounts for 28.6% (2). However, our patient did not express headache, and initially she had irritability, vomiting and fever which explain the infectious cause.

Acute hemicerebellitis can be associated with viral or bacterial infection in approximately 24% of the children and some patients have had positive serological results for *Epstein-Barr Virus*, *Influenza A virus*, *Salmonella Typhi*, *Varicella Zoster Virus*, and *Coxiella Burnetii* (1, 2). In this patient, all viral study as mentioned before were negative.

There were no clear sings of cerebellur involvement in form of ataxia, dysarthria, diplopia, nystagmus, intentional tremor or dysmetria, in fact she had unilateral weakness and areflexia.

There was no clear reason for the weakness and not reported before up to our knowledge.

The third unusual sign was the absence of both knee reflexes. In fact, the only role of cerebellum in the reflex arc is that just few of the impulses from the spindle receptors

through the arc after entering the dorsal horn goes to the cerebellum via the dorsal spinocerebellar tracts which play a critical role in cerebellar-cortical-spinal feedback loops to control balance and coordination which does not explain areflexia (9).

Our patient had unilateral right cerebellar abnormal FLAIR and T2 signal intensity with cortical swelling and no enhancement. However, it was not one of the differential because of the atypical presentation and the diagnosis was reached by MRI, that emphasized the role of MRI in such a patient.

Two studies explained the radiological findings in hemicerebellitis patients (10, 11) and vermis involvement has been described in (22.7%) of patients with hemicerebellitis, all of them were younger than 15 years of age and all had unilateral cerebellar swelling, in our patient there was no vermis involvement.

For the treatment, it is reported that, steroid can be effective in shortening the duration of the disease, and in some patients, it can improve the long-term outcome (2). In case the patient had severe headache or disturbance of the level of consciousness together with cerebellar swelling on MRI steroid and mannitol use are both recommended, but if the patient show severe obstructive hydrocephalus or signs of brainstem compression, management will be surgical (1, 3), however most of the patient do not require any treatment.

The prognosis is excellent but ipsilateral hemicerebellar atrophy may develop in up to 50% of cases, and a minority of them may have persisting fine motor and/or neurocognitive sequelae (1).

References

1. Lechón FC, Rodríguez AD, Cerdá SIS, Khabra K, de Prada I, García-Peñas JJ, et al. Hemicerebellitis: report of three paediatric cases and review of the literature. *European journal of paediatric neurology*. 2014;18(3):273-81.
2. Rodríguez-Cruz PM, Janet-Signoret S, Miranda-Herrero MC, Barredo-Valderrama E, Vázquez-López M, Ruiz-Martín Y, et al. Acute hemicerebellitis in children: case report and review of literature. *European journal of paediatric neurology*. 2013;17(5):447-53.
3. Sawaishi Y, Takada G. Acute cerebellitis. *The Cerebellum*. 2002;1(3):223-8.
4. Horowitz MB, Pang D, Hirsch W. Acute cerebellitis: case report and review. *Pediatric neurosurgery*. 1991;17(3):142-5.
5. Jabbour P, Samaha E, Lahoud GA, Koussa S, Abadjian G, Nohra G, et al. Hemicerebellitis mimicking a tumour on MRI. *Child's Nervous System*. 2003;19(2):122-5.
6. Levy EI, Harris AE, Omalu BI, Hamilton RL, Branstetter IV BF, Pollack IF. Sudden death from fulminant acute cerebellitis. *Pediatric neurosurgery*. 2001;35(1):24-8.
7. Van Lierde A, Righini A, Tremolati E. Acute cerebellitis with tonsillar herniation and hydrocephalus in Epstein-Barr virus infection. *European journal of pediatrics*. 2004;163(11):689-91.
8. Desai J, Mitchell WG. Acute cerebellar ataxia, acute cerebellitis, and opsoclonus-myoclonus syndrome. *Journal of child neurology*. 2012;27(11):1482-8.
9. Lichstein PR. *The medical interview*. 1990.
10. De Bruecker Y, Claus F, Demaerel P, Ballaux F, Scirot R, Lagae L, et al. MRI findings in acute cerebellitis. *European radiology*. 2004;14(8):1478-83.
11. Omeis IA, Khoshyomn S, Braff SP, Maugans TA. Idiopathic lymphocytic cerebellitis. *Pediatric neurosurgery*. 2002;36(1):52-3.