

PROTECTIVE EFFECTS OF AQUEOUS EXTRACT OF *Carica papaya* LEAF ON THE LIVER OF STREPTOZOTOCIN (STZ)-INDUCED DIABETIC ADULT WISTAR RATS

ABSTRACT

Carica papaya Linn.(Family: *Caricaceae*) is a perennial, herbaceous plant used traditionally among the Yoruba tribe of Nigeria for the treatment of various human and veterinary diseases including malaria, hypertension, diabetes mellitus, hypercholesterolemia, Jaundice, intestinal helminthiasis. Therefore, this study was designed to assess some of the effects of aqueous extract of *Carica papaya* leaf on the liver of Streptozotocin(STZ)-induced diabetic adult wistar rats.

Experimental diabetes was induced by intraperitoneal injection of 60mg/kg STZ freshly dissolved in 0.1M Sodium Citrate at P^H buffer at 4.5. Hyperglycemia was confirmed four days after injection by measuring the tail vein blood glucose level with an Accu-Check Sensor Comfort Glucometer (Roche, Mexico City).Only the animals with fasting blood glucose levels ≤ 200 mg/dl were considered diabetic.A total number of 48 adult wistar rats weighing between 100 -250 g of both sexes were used for this project. The rats were acclimatized to the experimental room having temperature of 25°C. Four groups were used for this study, group A served as the control which were fed with feeds and water *ad libitum* daily for six weeks and group B,C &D were induced with 60mg/kg of STZ after which were diagnosed of diabetes after 4 days of induction. Group B served as the diabetic control group and were fed with only feed and water *adlibitum* daily for six weeks whereas, group C and D were treated with different doses of *C.papaya* extract (1.5 and 3.0mg/100mL) as drinking water daily for six week and were sacrificed by cervical dislocation and the liver was removed and weighed before fixing in 10% formol saline for histological procedures.

The result showed a significant decrease in body weight of diabetic -induced rats ($P<0.05$) while the body weights increased significantly ($P<0.05$) in diabetic induced rats treated with 1.5 and 3.0g/100mL of the aqueous extract of *Carica Papaya* leaves when the initial and final weights of the rats were compared at the end of treatment. However, the liver weights increased significantly ($P<0.05$) in diabetic induced rats when compared with the diabetic rats treated with extract. The aqueous extract of *Carica papaya* (1.5 and 3.0g/100mL) significantly decreased ($P<0.05$) blood glucose levels in diabetic treated rats. There was significant increase in serum biomarker enzymes: ALT, AST and ALP in diabetic rats (Group B) at $P<0.05$ when compared with control rats (Group A). Conversely, biomarker hepatic enzymes: ALT, AST and ALP decreased significantly ($P<0.05$) in diabetic rats treated with 1.5 and 3.0g/100mL aqueous extract of *Carica papaya* leaves when compared with both Group A and Group B. The histological section of the liver of diabetic rats treated with 3.0g/100mL aqueous extract of *Carica papaya* leaves showed improvement in hepatic histo-architecture as the extract ameliorated hepatic morphological disruption occasioned by induced diabetes in wistar rats.

This study concluded that aqueous extract of *carica papaya* leaf ameliorated hepatic induced damage in the liver of Streptozotocin (STZ)-induced diabetic adult wistar rats

KEYWORDS: aqueous extract, *Carica papaya* leaf, Diabetes, STZ, glucose level, ameliorates Liver

INTRODUCTION

Diabetes mellitus is a hereditary, metabolic, degenerative disease of the pancreas which is characterized by hyperglycemia, glucosuria, hyperlipidemia, negative nitrogen balance and sometimes ketonuria. It is caused by inability of the tissues to carry out normal metabolism of carbohydrates, fats and protein due to an absolute or relative lack of insulin. Diabetes mellitus often referred to simply as diabetes, is a condition in which the body either does not produce enough, or does not properly respond to insulin, a hormone produce in the pancreas. Insulin enables the cells to properly respond to its own insulin, does not make enough insulin, or both.

This causes glucose to accumulate in the blood, often leading to various complications (Tierney *et al.*, 2002, Rother, 2007). Diabetes is a complex metabolic disorder characterized by persistent hyperglycemia resulting from defects in insulin secretion, insulin action or both. It is associated with complication like polyurea, polyphagia, polydipsia, ketosis, nephropathy and cardiovascular disorder (Richard, 2004).

Diabetes mellitus (DM) is a common disorder associated with increased morbidity and mortality and can be defined as a group of metabolic diseases characterized by chronic hyperglycemia due to defective insulin secretion, insulin action, or both, resulting in impaired carbohydrate, lipid, and protein metabolism (Andreoli *et al.*, 1990).

Carica papaya Linn. (Family; Caricaceae) is a perennial, herbaceous plant, with copious milky latex reaching to 6-10 meters tall. Its erect stem is about 30cm thick and roughened with leaf scars (Duke, 1984). The unripe fruit is used traditionally among the Yoruba tribe of Nigeria for the treatment of various human and veterinary diseases including malaria, hypertension, diabetes mellitus, hypercholesterolemia, jaundice, intestinal helminthiasis (Gill, 1992) and for the management of sickle cell anaemia (Ogunyemi *et al.*, 2008).

Papaya is a powerhouse of nutrients and is available throughout the year. It is a rich source of three powerful antioxidant vitamin C, vitamin A and vitamin E; the minerals, magnesium and potassium; the B vitamin pantothenic acid and folate and fiber. In addition to all this, it contains a digestive enzyme-papain that effectively treats Causes of trauma, allergies and sports injuries (Dawson, 1997). Several studies have reported the existence of 306 plants or fruits used as herbal remedies for diabetes. Among them lies *Carica papaya*, an herbaceous plant, member of the small family Caricaceae. This plant is widely cultivated for its edible pleasant fruit, which provides good nutritional value and easy digestion. (Dawson, 1997)

Carica papaya Linn. (Family; Caricaceae) is a perennial, herbaceous plant, with copious milky latex reaching to 6-10 meters tall. Its erect stem is about 30cm thick and roughened with leaf scars (Duke, 1984). The unripe fruit is used traditionally among the Yoruba tribe of Nigeria for the treatment of various human and veterinary diseases including malaria, hypertension, diabetes mellitus, hypercholesterolemia, jaundice, intestinal helminthiasis (Gill, 1992) and for the management of sickle cell anaemia (Ogunyemi *etal.*, 2008). *Carica papaya* contains an enzyme known as papain which is present in the bark, leaves and fruit. (Dawson, 1997).

Comment [BE1]: Succinctly put *C. papaya* after the first

Comment [BE2]: remove

Diabetes mellitus is a condition at which the pancreas no longer produces enough insulin or cells stop responding to the insulin that is produced, so that glucose in the blood cannot be absorbed into the cells of the body. Symptoms include frequent urination, lethargy, excessive thirst, and hunger (Nathan *et al.*, 2002). People with diabetes are at increased risk of cardiovascular, peripheral vascular and cerebrovascular disease (WHO, 2009).

Diabetes causes considerable mortality and morbidity. It has no cure but effective control of blood sugar level is beneficial, especially in terms of prolonging normal life and reducing complications (Aguwa, 1998). Diet and exercise cannot reverse or prevent type 1 diabetes. Currently, type 1 diabetes can be treated only with insulin, while monitoring the blood glucose level using blood testing monitors and treatment must be continued indefinitely (Lambert & Bringley, 2002).

Hypoglycemia may lead to seizures and episodes of unconsciousness (WHO, department of Non –communicable Surveillance 1999). Type 1 diabetes are fatally treated with exogenous insulin. Injection is the traditional and still most common method for administering insulin, injection, indwelling catheters and inhaled insulin and these are served experimental methods as well. All replace the missing hormone formally produced by new non –functional beta cells in the pancreas. In recent years, pancreas transplant has been used to treat type 1 diabetes. Islet cell transplant is also being investigated and has been achieved in mice and rats and in experimental trials in human as well (Patrick, 2008).

Type 2 diabetes is the most common type. In the early stage of type 2 diabetes, the predominant abnormality is reduced insulin sensitivity. At this stage, hyperglycemia can be reversed by a variety of measures and medications that improve insulin sensitivity or reduce glucose production by the liver. (Rotella *et al.*, 2013). Type 2 diabetes is due to primarily lifestyle factors and genetics. A number of lifestyle factors are known to be important to the development of type 2 diabetes, including obesity (defined by a body mass index of greater than thirty), lack of physical activity, poor diet, stress and urbanization. Excess body fat is associated with 30% of cases in those of Chinese and Japanese descent, 60 -80% of cases in those of European and African descent, and 100% of Pima Indians and Pacific islanders (Rotella *et al.*, 2013).

Comment [BE3]: what is the essence of this statement here?

Comment [BE4]: Wrong . ith should be (WHO, 1999)

MATERIALS AND METHODS

Materials

48 wistar rats of varying body weights between 100g-250g, Plastic experimental cage, distilled water, feeds(growers marsh), sensitivity weighing scale, sensitivity weighing balance, permanent marker, broom, parker, gloves, water bath, microtome, containers for dyes, Streptozotocin (STZ), Glucometer, *Caricapapaya* leaves, Specimen bottle, EDTA bottle, 10% formol saline, Heamatoxylin and Eosin. The study was carried out at the animal house of Faculty of Basic Medical Sciences, LAUTECH, Ogbomoso, Oyo State.

Comment [BE5]:

Sample collection

Freshly cut matured leaves of *Carica papaya* were procured from Taiwo's Hostel, Under G area, outside the campus of Ladoke Akintola University of Technology, Ogbomoso, and were identified and authenticated in the department of Pure and Applied Biology. The leaves were rinsed severally with clean tap water to remove dust particles and debris and thereafter allowed to completely drain. The collected leaves were then chopped into bits on a chopping board and air dried at room temperature 25°C -30°C for three weeks before taking to the experimental site.

Preparation of the aqueous extract of *Carica papaya* leaves

The air dried leaves were pulverized using electric blender into powdery form and then carried to the Food Science and Engineering Department (Lipid Room), Ladoke Akintola University of Technology, Ogbomoso, for aqueous extraction. 200gms of the powdered leaves were extracted by soaking it into a 2.0 litres of distilled water for 24 hours and mixed properly. The resultant mixtures were filtered with cheesecloth and the filtrates were then concentrated in a vacuo maintained at the low temperature (37-40)°C to about one tenth the original volume using a rotary evaporator. The concentrates were allowed in a water bath (40°C) for complete dryness of aqueous extracts of *Caricapapaya* leaves. The filtrate was evaporated to the volume of 660mls then refrigerated at 2-8°C till the time it was used for the experimentation (Juarez *et al.*, 2012).

Induction of diabetes

Experimental diabetes was induced by intraperitoneal injection of 60mg/kg STZ freshly dissolved in 0.1M Sodium Citrate at P^H buffered at 4.5. Hyperglycemia was confirmed 4 days

after injection by measuring the tail vein blood glucose level with an Accu-Check Sensor Comfort Glucometer (Roche, Mexico City).Only the animals with fasting blood glucose levels ≤ 200 mg/dl were considered diabetic.

Grouping of animals

The animals were grouped into 4 groups namely;

GROUP A	12	Normal Control
GROUP B	12	Diabetic- Control
GROUP C	12	Diabetic-Treated With Aqueous Extract
GROUP D	12	Diabetic-Treated With Aqueous Extract

Administration of aqueous extract of *caricapapaya* leaves

The experimental animals are grouped and administered as follows;

- ❖ Animals in Group A were given feeds and water ad libitum daily for six weeks.
- ❖ Animals in Group B induced with 60mg/kg STZ were given feeds and water ad libitum daily for six weeks.
- ❖ Animals in Group C induced with 60mg/kg STZ were administered with 1.5g/100ml of *Caricapapaya* extracts daily for six weeks.
- ❖ Animals in Group D induced with 60mg/kg STZ were administered with 3.0g/100ml of *Carica papaya* extracts daily for six weeks.

Blood collection and blood glucose measurement

Blood sample was withdrawn from the tail vein and tested using glucose test strips and glucometer after an overnight fast.

Experimental design

In order to determine the hypoglycemic effect of *Caricapapaya leaves* in diabetic rats, oral doses of *Caricapapaya* aqueous extracts (1.5 and 3.0g/100mL) were administered as drinking water *adlibitum* (Perez *et al*, 2003).All treatments were administered as drinking water for period of six weeks after which the rats were sacrificed by means of cervical dislocation. The

rats were dissected and the liver of each sacrificed experimental rat in each group was harvested. The livers were weighed before fixing them in the 10% formal saline in sample bottles for analysis.

Tissue processing

The tissues were allowed to fix in 10% formal saline for 48 hours, tissues were grossed and cut into smaller pieces of 3 mm thick in pre-labeled tissue cassette. They were processed using Automatic tissue processor (LEICA TP1020) where they passed through various reagents including Alcohol (of various concentrations starting from 70%, 80%, 90%, and two 100% or absolute alcohol) for dehydrations, two changes of xylene and three changes of molten paraffin wax set at 65 degree centigrade. The processing time was 12 hours (Carleton, 1967).

Embedding

The tissues were embedded in paraffin wax by burying the tissues in a metal mold containing molten paraffin wax and were allowed to form paraffin blocks, read for microtome (Carleton, 1967).

Haematoxylin and eosin staining techniques

Methodology of AST, ALT AND ALP

ASSAY OF AST AND ALT (Bergermeyer et al., 1978)

PRINCIPLE

This assay is based on the principle that AST and ALT catalyze the transfer of amino group from L-aspartate/L-alanine to α -ketoglutarate to yield oxaloacetate/pyruvate respectively.

Oxaloacetate/pyruvate can oxidise NADH to NAD⁺ in the presence of malate dehydrogenase/lactate dehydrogenase. The decrease in absorbance at 340nm in a spectrophotometer (Genesys 10-S, USA) due to the oxidation of NADH is monitored kinetically and is proportional to AST/ALT activity.

REAGENTS

1. Reagent 1 – Buffer

Tris (80 mmol/l pH 7.8)

L-aspartate or L-alanine (240 mmol/L)

MDH ≥600 U/L

LDH ≥600 U/L

2. Reagent 2 – Substrate

2-oxoglutarate (12 mmol/L)

NADH (0.18 mmol/L)

3. Working reagent

Four parts of reagent 1 were mixed with one part of reagent 2.

PROCEDURE

To 100µl of serum, 1000 µl of working reagent was added. The tubes were mixed well and the absorbance was read after 60 seconds and the change in absorbance was measured for 2 minutes at 340nm in a spectrophotometer (Genesys 10-S, USA).

AST/ALT activity is expressed as IU/L.

ASSAY OF ALP (Schlebusch et al., 1974)

PRINCIPLE

At alkaline pH, ALP catalyzes the hydrolysis of p-nitrophenyl phosphate to Yellowcoloured p-nitro phenolate and phosphate; the change in absorbance measured at 415nm is directly proportional to the enzyme activity.

REAGENTS

1. p-nitrophenyl phosphate (PNPP)
2. Buffer

The working reagent was prepared by mixing one vial of PNPP substrate with 5.0ml buffer.

PROCEDURE

To 20 μ l of serum, 1.0ml of working reagent was mixed and after one minute, the increase in absorbance was measured at 415nm in a spectrophotometer (Genesys 10-S, USA). The ALP activity is expressed as IU/L.

Statistical analysis

Data were expressed using Graphpad prism 6. Data were expressed as mean \pm Standard error of mean (Mean \pm S.E.M). Means, values were compared using one-way non-parametric t-test. P- value less than 0.05(P <0.05) were taken to be statistically significant. All graphs were drawn with Excel 2007 except in Chart 4.5 where Graphpad prism 6 was used

RESULTS

Group A(Control) increases from (141.7-160.4), Group B(Diabetic) decreases from (165.5-85.00), Group C increases from (138.6-161.4), Group D increases from (179.2 -204.2)^aRepresents significant decrease at P<0.05 when compared with Group A (control),^bRepresents significant increase at P<0.05 when compared with Group B(diabetic),^cRepresents significant increase at P<0.05 when compared with Group A(Control) &^dRepresents significant decrease at P<0.05 when compared with Group B(Diabetic).

Group B shows a significant decrease in weight at $P < 0.05$ at final weight, Group C and Group D show a significant increase in weight at $P < 0.05$ at final weight when compared with Group B and only significantly increase in Group D at $P < 0.05$ at final weight when compared with Group A.

TABLE 1: MEAN \pm S.E.M OF THE BODY WEIGHTS (G) OF THE RATS BEFORE AND AFTER THE TREATMENT

GROUPS	INITIALWEIGHT(g)	FINAL WEIGHT(g)	% WEIGHT GAIN OR LOSS
GROUP A(Control)	141.7 \pm 5.618	160.4 \pm 4.825	13.20
GROUP B(Diabetic)	165.5 \pm 7.282 ^c	85.00 \pm 7.638 ^a	-48.64
GROUP C(Low dose)	138.6 \pm 6.182 ^d	161.4 \pm 9.148 ^b	16.45
GROUP D(High dose)	179.2 \pm 7.189 ^c	204.2 \pm 5.180 ^{bc}	13.95

Values are expressed as Mean \pm S.E.M of the initial and final body weights of the rats using student t-test.

The results showed a significant weight gain in Group A, C & D, while there was a significant weight loss in Group B diabetic-rats. Group B shows a significant decrease in weight at $P < 0.05$ at final weight, Group C and Group D show a significant increase in weight at $P < 0.05$ at final weight when compared with Group B and only significantly increase in Group D at $P < 0.05$ at final weight when compared with Group A.

TABLE 2: MEAN \pm S.E.M OF THE LIVER WEIGHT AFTER TREATMENT

GROUPS	LIVER Mean \pm S.E.M(g)	RELATIVE LIVER WEIGHT (%)
GROUP A(Control)	3.278 \pm 0.4372	2.04
GROUP B(Diabetic)	5.219 \pm 0.4086 ^a	6.14
GROUP C (Low dose)	4.175 \pm 0.4244	2.59
GROUP D(High dose)	4.893 \pm 0.3595 ^b	2.40

Values are expressed as Mean \pm S.E.M of the Organ weights (Liver) of the rats using student t-test.

There was a significant (^a) increase in the organ weight in group B (diabetic) rats at P<0.05 when compared with the mean weight of group A (control). Conversely, there was a significant decrease (^b) in the organ weight in group C and D rats at P<0.05 when compared with Group B (Diabetic). There was no significant increase in weights of Organ in Group C and Group D at P <0.05 when compared with Group A (control).

TABLE 3: SHOWING MEAN \pm S.E.M OF ALT, AST AND ALP IN SERUM OF WISTAR RATS AFTER TREATMENT.

GROUPS	ALT MEAN \pm S.E.M(U/L)	AST MEAN \pm S.E.M(U/L)	ALP MEAN \pm S.E.M(U/L)
GROUP A(Control)	28.13 \pm 3.888	154.6 \pm 2.481	15.23 \pm 2.353
GROUP B(Diabetic)	66.94 \pm 6.606 ^a	225.1 \pm 18.26 ^a	25.73 \pm 0.5041 ^a
GROUP C(1.5g/mL)	49.58 \pm 5.775 ^{b,c}	179.9 \pm 4.695 ^{b,c}	20.23 \pm 0.9359 ^b
GROUP D(3.0g/mL)	40.04 \pm 4.722 ^{b,c}	170.5 \pm 4.958 ^{b,c}	16.45 \pm 0.3915 ^b

Values are expressed as Mean \pm S.E.M of the ALT, AST & ALP in serum of the wistar rats using student t-test.

^aRepresents significant increase at $P < 0.05$ when compared with Group A(control), ^bRepresents significant decrease at $P < 0.05$ when compared with Group B(diabetic), ^cRepresents significant increase at $P < 0.05$ when compared with Group A(control).

Alanine aminotransferase (ALT)

ALT activity showed a significant increase in group B, group C & group D when compared with group A(Control) at $P < 0.05$ and also a significant decrease in ALT activity in group C and group D when compared with group B (diabetic) at $P < 0.05$.

Aspartate aminotransferase (AST)

AST activity showed a significant increase in group B, group C & group D when compared with group A(Control) at $P < 0.05$ and also a significant decrease in AST activity in group C and group D when compared with group B (diabetic) at $P < 0.05$.

Alkaline phosphatase (ALP)

ALP activity showed a significant increase in group B when compared with group A(Control) at $P < 0.05$ and also a significant decrease in ALP activity in group C and group D when compared with group B (diabetic) at $P < 0.05$. However, there is increase in ALP activity in group C and group D but not significant ($P > 0.05$).

CHART 4.4: Showing the serum analysis of ALT, AST & ALP (U/L)

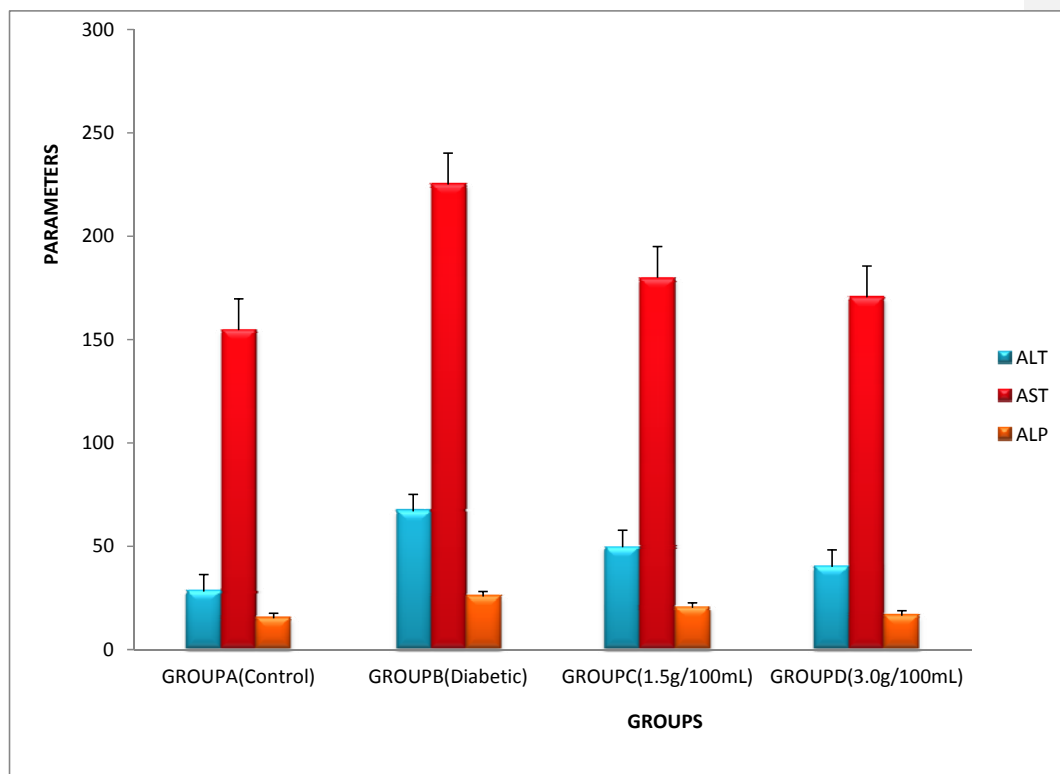
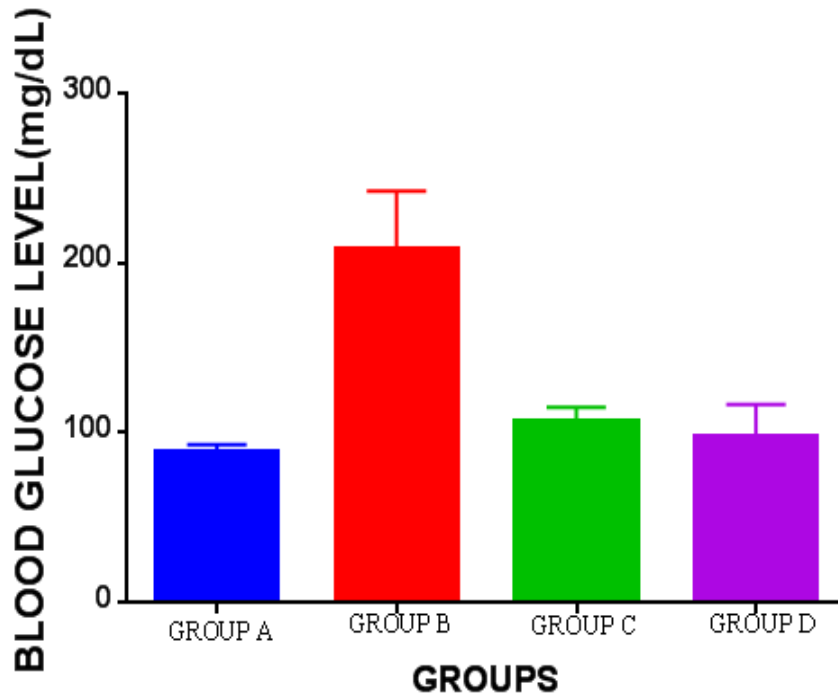


TABLE 4: SHOWING MEAN \pm SEM OF BLOOD GLUCOSE LEVEL OF WISTAR RATS AFTER TREATMENT.

WEEKS	GROUP A Mean \pm S.E.M	GROUP B Mean \pm S.E.M	GROUP C Mean \pm S.E.M	GROUP D Mean \pm S.E.M
WEEK 0	99.42 \pm 1.288	174.5 \pm 60.45 ^a	105.5 \pm 8.539	117.0 \pm 7.627
WEEK 5	88.48 \pm 4.674	206.5 \pm 61.04 ^a	97.75 \pm 5.154	77.75 \pm 1.250 ^b
WEEK 6	82.09 \pm 3.706	234.0 \pm 47.43 ^a	115.3 \pm 6.303 ^b	95.75 \pm 2.626 ^b

^aRepresents significant increases at $P < 0.05$ when compared with Group A (control), ^bRepresents significant decrease at $P < 0.05$ when compared with Group B (diabetic)

CHART .5: SHOWING THE BLOOD GLUCOSE LEVEL



HISTOLOGICAL EVALUATIONS

GROUP A (Control) Rats

The histological sections of control rats given feeds and water ad libitum for 42 days showed normal liver architecture, liver central veins are not occluded or congested, sinusoids are normal, no infiltration of inflammatory cells seen within the liver parenchyma, and hepatocytes appear normal with normal morphology, no haemorrhage in H and E Stain.

GROUP B (Diabetic Control) Rats

The histological sections of Group B induced with 60mg/kg Streptozotocin for 42 days showed enlarged central vein, distortion in the arrangement of cells around the central vein; periportal fatty infiltration (PFI) with focal necrosis of hepatocytes also showed enlarged sinusoids with fatty infiltration in (X400) in H & E stain.

GROUP C (treated group)

Group C rats induced with 60mg/kg Streptozotocin were treated with 1.5g/100mL of aqueous extract of *C.papaya* for 42 days and the histological section showed normal central vein, diminished disruption of hepatocytes, enlarged sinusoids with perivenous fatty infiltration in H & E stain.

GROUP D (treated group)

Group D rats induced with 60mg/kg Streptozotocin were treated with 3.0g/100mL of aqueous extract of *C.papaya* for 42 days and the histological section of the liver of this group features central veins which are not occluded or congested, sinusoids are normal, no infiltration of inflammatory cells seen within the liver parenchyma, hepatocytes appear normal with normal morphology, no haemorrhage in H and E Stain.

PHOTOMICROGRAPH PLATES OF HISTOLOGICAL EVALUATIONS

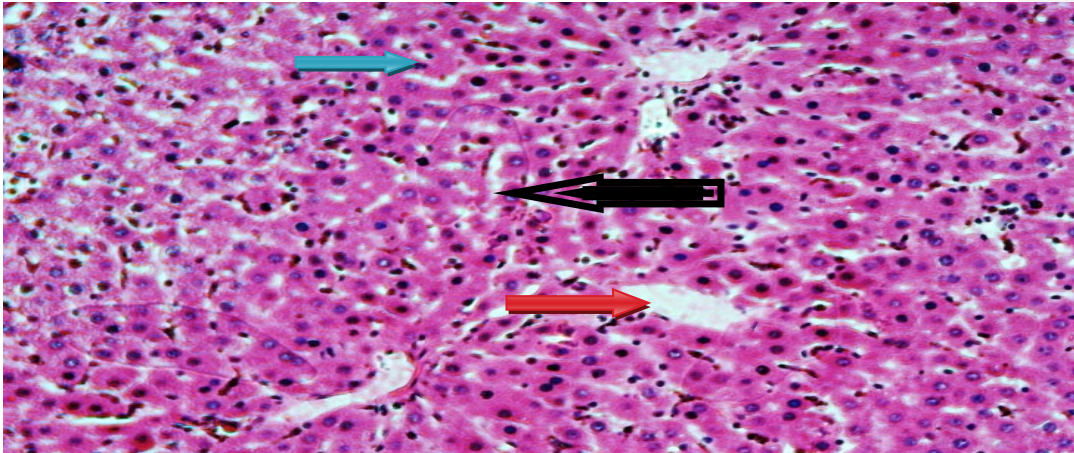


PLATE 1 (Control) GROUP A

A photomicrograph of liver sections in control group (Group A) given feeds and water ad libitum for the whole period of administration (42days) showing the normal liver microarchitecture, central vein (Red arrow), sinusoids (Black arrow), Hepatocytes (Blue arrow), no haemorrhage and there is no infiltration of inflammatory cells. X100) H&E stained

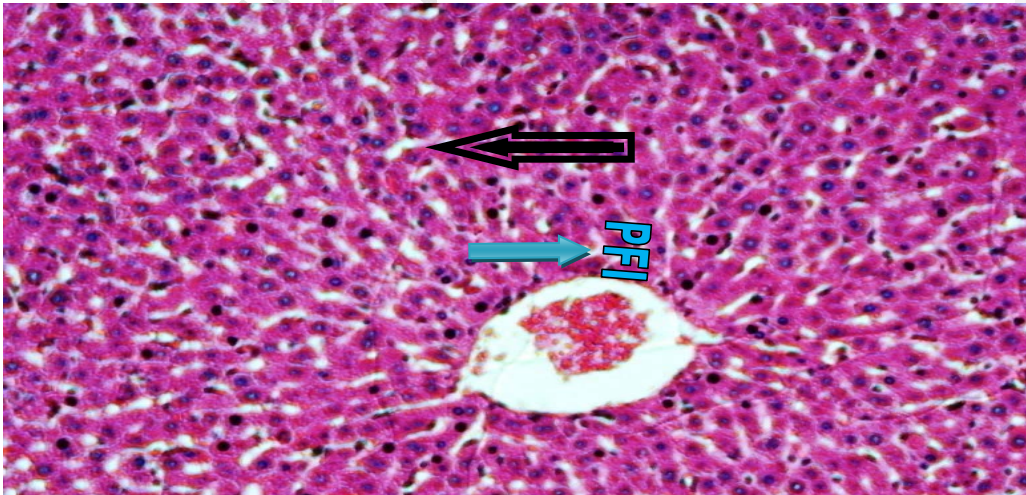


PLATE 2 (Diabetic control) GROUP B

A photomicrograph of liver sections of Group B treated with 60mg/kg Streptozotocin (STZ) for 42 days showing enlargement of central vein, distortion in the arrangement of cells around the central vein (Red arrow), periportal fatty infiltration (PFI) with focal necrosis of hepatocytes (Blue arrow) and also shows enlarged sinusoids with fatty infiltration (Black arrow) (X100) H&E stained

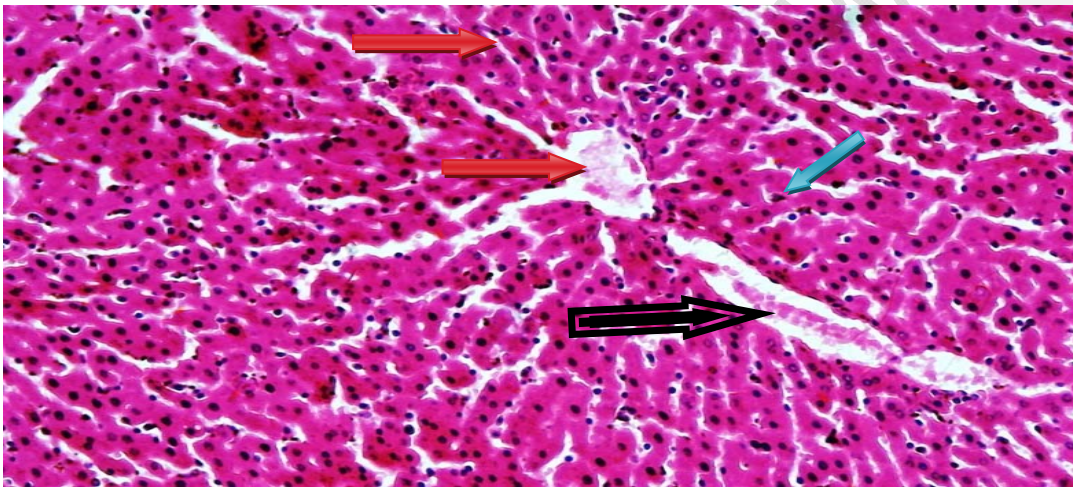


PLATE 3 (LOW DOSE TREATED GROUP) (1.5g/100mL)

A photomicrograph of liver sections of Group C induced with 60mg/kg STZ and treated with 1.5g/100mL of *Carica papaya* leaves extract for 42 days showing normal central vein (Red arrow), reduced distortion in the histology of the hepatocytes (Blue arrow), enlarged sinusoids with perivenous fatty infiltration (Black arrow). (X100) H&E stained

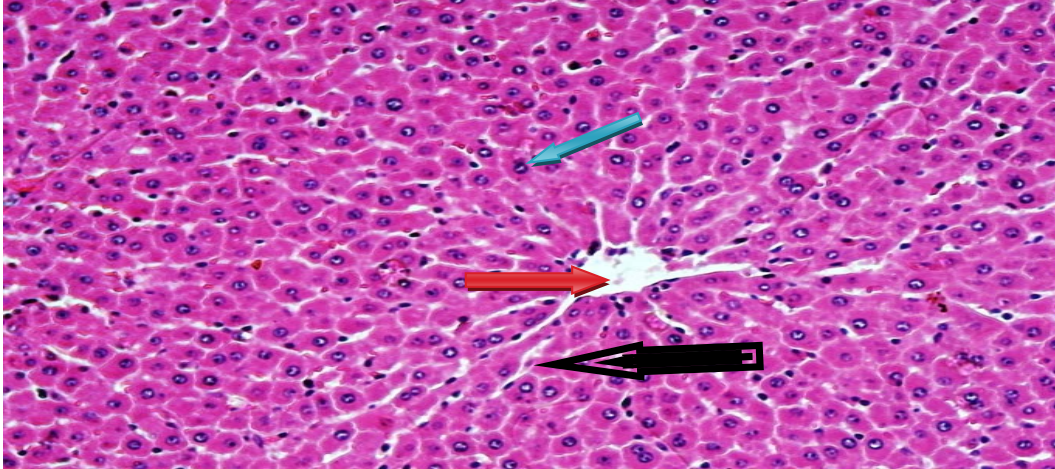


PLATE 4 (HIGH DOSE TREATED GROUP) (3.0g/100mL)

A photomicrograph of liver sections of Group D induced with 60mg/kg STZ and treated with 3.0g/100mL of *Carica papaya* leaves extract for 42 days showing normal liver microarchitecture of hepatocytes(Blue arrow), sinusoids(Black arrow) and central vein(Red arrow) no haemorrhage and there is no infiltration of inflammatory cells compared with Group A(Control).(X100) H&E stained

DISCUSSION

The intraperitoneal induction of Streptozotocin(STZ) to experimental rats has been shown to cause significant increase in the blood glucose levels(bgls) four days after induction .STZ is widely used to induce insulin-dependent diabetes mellitus(type 1 diabetes) in experimental animals because of its toxic effects on islet beta cells (Punithavathi *et al.*,2008 ;Fadilloglu *et al.*,2008). The diabetogenic action of STZ is the direct result of irreversible damage to the pancreatic beta cells resulting in degranulation and loss of capacity to secrete insulin (Gu *et al.*, 1997).The incidence and severity of lesions produced by STZ in pancreas, liver, kidney, and GIT, progressively increased with time from one to six weeks post treatment (Piyachaturawat *et al.*, 1988). The observations and results of the present study demonstrated that streptozotocin(STZ) was effective in producing severe hyperglycemia in experimental animals and this is in agreement with the findings of Kim, 2006, Habibuddin *et al.*,2008; Lee *et al.*, 2008; Heidari *et al.*, 2008).

The use of conventional medical approach of simply using insulin and oral drugs to control diabetes mellitus is not only costly but inadequate, boring and lack compliance; thus patients exposure to long term complication remains a risk (Okolie *et al.*, 2008). In response to World Health Organization (WHO), drawing attention to the use of herbal medicine as being of great importance to the health of individuals and communities (Adebanjoet *al.*, 2006). Many traditional medicines in use are derived from medicinal plants minerals and organic matter. Some wild herbs and species have been shown to be most effective, relatively non-toxic and have substantial scientific documentation to attest to their efficacy in diabetes management (Okeke, 1998).

The 42 days sub-acute studies have shown an association between hyperglycemia and decreased body weight of diabetic rats in support of Zafar & Naeem, (2010). The present study was designed to observe some of the effects that aqueous extract of *Carica papaya* leaf could have on the histology of liver of STZ-induced diabetes, to assess its effects on mean weight of rats, mean and relative weight of liver, blood glucose level and serum analysis of liver AST, ALT & ALP in adult wistar rats.

The body weight of the animals in Group A (Control Group) considerably increases in weight, the diabetic treated groups (Group C & D) with 1.5g/100mL and 3.0g/100mL of *Carica papaya* extract respectively showed significant increase in body weight after treatment when compared with control non-diabetic rats at $P < 0.05$ (Table 1 and Chart 1).

The aqueous extract of *Carica papaya* maintained the body weight of the diabetic treated rats with 1.5 and 3.0g/100mL aqueous extract of *Carica papaya* leaves respectively (Table 1 & Chart 1) except during Week 1 and Week 2 where the body weight decreases but increase in weight was observed from Week 3 to Week 6 which may be attributed to hypoglycemic properties of the extract. Table 1 & Chart 1 also showed significant decrease in weight in Group B (diabetic) and it could be due to many factors such as loss of appetite, increased muscle waste and loss of tissue proteins, this occurred in reference to Junod *et al.*, 1969. It may also be concluded that the reduction in body weight was associated with increase in the relative weight of liver as observed in this study which was similarly reported by Zafar *et al.*, (2009).

The result showed significant weight gain among the groups (Table 2 & Chart 2) except in Group B where there was weight loss, weight loss is a main sign of diabetes but its mechanism is not clear. It could be due to many factors such as loss of appetite, increased muscle waste and loss of tissue proteins, when comparing the weight of the rats before and after administration and this was supported by the report of Zafar *et al*, (2010).The significant weight gain reported in Group C and Group D occurred as previously reported in the findings of Juarez *et al*(2012).

An increase (hypertrophy) in the weight of liver in relation to the body weight was observed in Group B (diabetic) rats compared with control non-diabetic rats (Group A) despite the fact that the mean weight of rats in Group B decreased and this agreed with the findings of Merzouk *et al*, (2000) and Ohno *et al*. (2000). The resultant effects of these findings resulted in reduction in the relative weight of liver of diabetic rats treated with 1.5g/100mL and 3.0g/100mL *Carica papaya* extract compared with the control.

This study showed that the administered *Carica papaya* leaf aqueous extract(1.5and 3.0g/mL) in group C and D diminished significantly(P <0.05) the observed increased blood glucose in diabetic group B rats in a pattern as earlier reported by Shen *et al.*, 2010, Gepts *et al.*, (1981).In addition, this extract exhibited an antioxidant action and was not hepatotoxic at these doses (1.5 and 3.0 g/100 mL). This hypoglycemic effect is similar to the one reported for other plants (Gupta *et al*, 2004). Such effect may be explained in part by either a decrease in the rate of intestinal glucose absorption or an increase in peripheral glucose utilization. In this line, some authors have ascertained increased catabolism of glucose due to GLUT4 translocation to the plasma membrane in muscle and brown adipose cells, with up regulation of the uncoupling protein-1 in brown adipose tissue and hepatic gluconeogenesis, causing as a result of hyperinsulinemia or enhancement of peripheral glucose utilization and this is also in support of Juarez *et al* (2012).

Histological findings showed normal histoarchitecture in the control group. Photomicrograph plates of Group A (Plate 1) reflects normal hepatocytes separated by sinusoids. The central veins show normal histoarchitecture, no haemorrhage and there is no infiltration of inflammatory cells seen within the liver parenchyma.

The histological section of Group B (diabetic control) showed enlarged central vein, peri-portal fatty infiltration (PFI) with focal necrosis of hepatocytes also shows enlarged sinusoids with fatty

infiltration in Plate 2 and histological section recorded by Juarez et al, (2012) features fat and glycogen content in hepatocytes of diabetic rats under PAS staining.

The hypoglycemic actions of *Carica papaya* extract (1.5 and 3.0g/mL) is supported by the improvement in the histological features of fat content in hepatocytes of diabetic rats and features normal histological section of liver, however, 1.5g/mL *Carica papaya* extract still features some lesions and this observation was not consistent with report of Juarez *et al*, (2012) that 1.5g/mL suggest the aqueous extract of *Carica papaya* at low dose 1.5 g/100 mL regulates bile transit and hepatic function in diabetic rats, but at high doses it could be hepatotoxic (3.0 g/100 mL), whereas the result of these studies showed normal histological section under 3.0g/100mL of *Carica papaya* extract compared to the control group.

We can therefore, deduce that extract of *C.papaya* leaves at a regulated high dose is more hepatoprotective than low dose.

Moreover, significant elevation of hepatic serum biomarker enzymes such as Aspartate aminotransferase(AST), Alanine aminotransferase(ALT) & Alkaline phosphatase(ALP) was observed in Group B(66.94 ± 6.606 , 225.1 ± 18.26 , 25.73 ± 0.5040 U/L, respectively) when compared with Group A (28.13 ± 3.888 , 154.6 ± 2.481 , 15.23 ± 2.353 U/L, respectively) at $P < 0.05$.has been similarly reported in the previous work of Piyachaturawat *et al.*,(1991), indicating impaired liver function that may be due to hepatic damage induced by hyperglycemia(Table 4) and this is in support of precious observation made Perez *etal*, (2003). In the present study, our results showed that *Carica papaya* treatment of diabetic-induced rats (1.5 and 3.0g/100mL) respectively gave a significant decrease in serum aminotranferases activities (ALT and AST) in diabetic treated rats(Group C and Group D) when compared with Group A and B at $P < 0.05$ and only significant reduction in ALP activity when compared with Group B at $P < 0.05$, which was similarly supported by Juarez *et al*,(2012).

CONCLUSION

This study concluded that the hepatoprotective and hypoglycemic activities of the aqueous extract of the *Carica papaya* leaves in STZ –induced hepatotoxicity may involve its antioxidant and free radical scavenging activities. Also, the results of this study has shown the rationale for

the folkloric use of the aqueous extract of *Carica papaya* leaves in the treatment of liver disorders that may occur as a result of diabetes mellitus most especially type 1 diabetes. However, further research is required to enhance understanding of its potential therapeutic action and to corroborate findings from this study.

REFERENCES

1. Ayoola(2010). A phytochemical and nutrient evaluation of *Carica papaya* leaves IJRRAS, 5(3).
2. [AguwaNze\(1998\): Therapeutic basis of clinical pharmacy in the Tropic published by Snaop press \(Nig\) Ltd Enugu, Nigeria \(5th edition\) pg 120-122.](#)
3. Andreoli, T.E., C.C. Carpenter, F. Plum and L.H. Smith. 1990. *Diabetes mellitus*. In: Cecil Essential of Medicine, J. Dyson, (Ed.), 2nd Edn., WB Saunders, Philadelphia, 1: 496-505.
4. Adebajo AC, Ayoola OF, Iwalewa EO, Akindahunsi AA, Omisore ND, Adewummi CO, Adenowo TK (2006). Anti – trichomonal, biochemical and toxicological activities of methanolic extract and some carbazole alkaloids isolated from the leaves of *Murraya Koeniyi* growing in Nigeria, *Phytomedicine*, B, 13: 246-254..
5. Bartoli E, Fra GP, Carnevale Schianca GP (2011). "The oral glucose tolerance test (OGTT) revisited." *European journal of internal medicine* 22 (1): 8–12. Doi: 10.1016/j.ejim.2010.07.008 .PMID 21238885.
6. Bennett, R. A. & Pegg, A. E. Alkylation of DNA in rat tissues following administration of Streptozotocin. *Can. Res.*, 41:2786-90, 1981.
7. [Richard, Bolli, GB, Di Marchi, Park, G Det al, insulin analogues and their potential in the management of diabetes mellitus. Diabetologia 2003; 42: 1151-1167. Cross Ref /Pubmed/Scopus\(276\).](#)
8. Campbell S, McLaren EH, Danesh BJ: Rapidly reversible increase in insulin requirement with interferon. *Br Med J* 313: 92, 1996.

Comment [BE6]:

Comment [BE7]: wrong

9. Campbell PJ, Carlson MG. Impact of obesity on insulin action in NIDDM. *Diabetes* 1993; 42: 405 -10.
10. Carpenter Mw, Coustan DR : Criteria for screening tests for gestational diabetes. *Am J ObstetGynecol* 144: 768-773, 1982
11. Carleton H. (1967). Carleton histology technique. Oxford university press, 4th Edition: pp 33. changes in rats exposed to lead. *Alcohol* 120, 9-17.
12. Catrpanzis. Cotran, VincyKurney, tucker Collins pathology Basis of Disease (16th edition) 1994; pg 50-52.
13. Complications (DCCT/EDIC) Study Research Group (December 2005). "Intensive diabetes treatment and cardiovascular disease in patients with type 1 diabetes". *The New England Journal of Medicine* 353 (25): 2643–53. doi:10.1056/NEJMoa052187. PMC 2637991. PMID 16371630
14. Duke JA, 1984, Borderline herbs. CRC Press. Boca raton, Florida, USA.
15. Dobson, M. (1776). "Nature of the urine in diabetes". *Medical observations and inquiries* 5: 298-310.
16. Defronzo RA, Bonadonna RC, Ferrannini E. Pathogenesis of NIDDM. In Alberti KGMM, Zimmet P, Defronzo RA, eds. *International textbook of diabetes mellitus* 2nd edn. Chichester. John Wiley, 1997: pp 635-712.
17. Defronzo RA, Bonadonna RC, Ferrannini E. Pathogenesis of NIDDM. In Alberti KGMM, Zimmet P, Defronzo RA, eds. *International textbook of diabetes mellitus* 2nd edn. Chichester. John Wiley, 2001: pp 635-712.
18. Defronzo RA, Bonadonna RC, Ferrannini E. Pathogenesis of NIDDM. In Alberti KGMM, Zimmet P, Defronzo RA, eds. *International textbook of diabetes mellitus* 2nd edn. Chichester. John Wiley, 2003: pp 635-712.
19. Dawson, emma (1997). The medical properties of the papaya, *carica papaya* L. (online). At; Hyperlink URL; <http://ww.siu.edu/ebil>.
20. Desser L, et al. Oral therapy with proteolytic enzymes decreases excessive TGF-beta levels in human blood. *Cancer ChemotherPharmacol* 2001;47:S10-5.
21. Desser L, Zavadova E, Herbacek I. Oral enzymes as additive cancer therapy. *Int J Immunotherapy*. 2001;17(2-3-4):153-161.

22. Engelgau MM, Geiss LS, Saaddine JB, Boyle JP, Benjamin SM, Gregg EW, Tierney EF, Rios – Burrows N, Mokdad AH, Ford ES, Imperatore G, Narayan KM: the evolving diabetes burden in the united states. *Ann intern Med* 2004, 52: 468 -474.
23. Fadillioglu, E.; Kurcer, Z.; Parlakpinar, H.; Iraz, M. &Gursul, C. Melatonin treatment against remote open injury induced by renal ischemia reperfusion injury in diabetes mellitus. *Arch. Pharm. Res.*, 31(6):705-12,2008.
24. Goodner CJ, waike BC, Koerker DJ, et al. insulin, glucagon and glucose exhibit synchronous, sustained oscillations in fasting monkeys. *Science* 1977; 195: 177.
25. Gepts W, Lecompte PM: The pancreatic islets in diabetes. *Am J Med* 1981, 70:105–115.
26. Gill LS, 1992. *Carica papaya* L. In:Ethnomedicinal uses of plants in Nigeria. Benin City: UNIBEN Press, pp: 57 - 58. ISBN: 978-2027-20-0
27. Gupta R, Sharma AK, Sharma MC, Gupta RS: Antioxidant activity and protection of pancreatic β -cells by Embelin in streptozotocin-induced diabetes. *J Diabetes* 2012, 4:248–256..
28. Inderbir Singh; Textbook of Human Histology (6th edition, 2011) Irvine, F. R. 1961.
29. Jennifer Mayfield (1998) Diagnosis and classification of diabetes mellitus new criteria published by American Academy of family physician's pg 21.
30. Juarez- Rejop et al., Hypoglycemic effect of carica papaya leaves in STZ –induced diabetic rats. *BMC Complementary and Alternative Medicine* 2012 12:236.
31. Junod A, Lambert AE, Stauffacher W, Renold AE: Diabetogenic action of streptozotocin: relationship of dose to metabolic response. *J Clin Invest* 1969, 48:2129–2139
32. Keith L. Moore, Arthur. F. Dalley, Anne M.R Agur 2010.
33. Kumar, U., Abbas, A. K. & Fausto, N. Pathological Basis of Diseases. Saunders.
34. Philadelphia, Pennsylvania, USA, 2004, 1525pp.
35. King H, Aubert RE, Herman WH. Global burden of diabetes, 1995-2025; prevalence, numerical estimates and projections. *Diabetes Care* 1998; 21(9): 1414-31.
36. Kim, J. D.; Kang, S. M.; Seo, B. I.; Choi, H. Y.; Choi, H. S. & Ku, S. K. Anti-diabetic activity of SMK001, a poly herbal formula in streptozotocin-induced diabetic rats: therapeutic study. *Biol. Pharm. Bull.*, 29(3):477-82, 2006.
37. Lippincott William 2009: Lippincott's illustrated reviews pharmacology 4th edn. Pg 255.

38. Lebovitz, H.E., 1994. Oral Anti-Diabetic Agents. In: Joslin's Diabetes Mellitus. Khan, C.R. and G.C. Weir, (Eds). 13th Edn., Lea and Febiger, Philadelphia, 29: 508-524.
39. Laios K, Karamanou M, Saridaki Z, Androustos G (2012). "Aretaeus of Cappadocia and the first description of diabetes". *Hormones* 11 (1): 109–113. PMID 22450352.
40. LM Tierney, SJ McPhee, MA Papadakis (2002). *Current Medical Diagnosis and Treatment International Edition* New York: Lange Medical Books / McGraw-Hill pp 1203-15.
41. Lee, S. I.; Kim, J. S.; Oh, S. H.; Park, K. Y.; Lee, H. G. & Kim, S. D. Antihyperglycemic effect of *Fomitopsis pinicola* extracts in streptozotocin-induced diabetic rats. *J. Med. Food*, 11(3):518-24, 2008.
42. Liang Y, Cushman SM, Whitesell RR, Matschinsky FM. GLUT1 is adequate for glucose uptake GLUT 2. Deficient insulin releasing beta-cells. *Horm Metab Res* 1997; 29:255.
43. Mooy JM, Grootenhuys PA, de Vries H, Valkenburg HA, Bouter LM, Kostense PJ et al. Prevalence and determinants of glucose intolerance in a Dutch population. The Hoorn study. *Diabetes Care* 1995; 18: 1270-73.
44. Merzouk, H.; Madani, S.; Chabane, Sari, D.; Prost, J.; Bouchenak, M. & Belleville, J. Time course of changes in serum glucose, insulin, lipids and tissue lipase activities in macrosomic offspring of rats with Streptozotocin induced diabetes. *Clin. Sci. (Lond)*, 98(1):21-30, 2000.
45. Nathan DM, Cleary PA, Backlund JY, Genuth SM, Lachin JM, Orchard TJ, Raskin P, Zinman B; Diabetes Control and Complications Trial/Epidemiology of Diabetes Interventions and Complications (DCCT/EDIC) Study Research Group (December 2005). "Intensive diabetes treatment and cardiovascular disease in patients with type 1 diabetes". *The New England Journal of Medicine* 353 (25): 2643–53. doi:10.1056/NEJMoa052187. PMC 2637991. PMID 16371630.