

Minireview Article

Biochemical and histological Study on the Effects of Curcumin and/or DDB on Rats Drinking Ethanol Alcohol

Abstract

The therapeutic effects of curcumin and/or DDB on rats drinking alcohol were evaluated in the present study. Albino Wister rats drinking 20% ethanol in drinking water were treated with curcumin (100mg/kg body weight) and /or DDB (50mg/ kg body weight) mixed in diet for 8 weeks. ALT and AST enzymes were significantly reduced in rat drinking alcohol and treated with DDB or curcumin compared with rats drinking alcohol ($p < 0.05$). On the other hand, in case of mixed treatment with curcumin and DDB, AST enzyme was elevated significantly compared with rat drinking alcohol ($P < 0.05$). GGT enzyme was reduced after treatment of alcohol drinking rats with curcumin or DDB in comparing with alcohol drinking rats. MDA concentration in liver homogenate significantly reduced in rats drinking alcohol and treated with DDB compared with rats drinking alcohol ($p < 0.05$). However, serum MDA showed a significant reduction in rats drinking alcohol and treated with curcumin compared with rats drinking alcohol ($P < 0.05$). Histopathological studies revealed liver tissue damage after alcohol administration, however an improvement in liver tissue after treatment with curcumin and DDB. In conclusion, curcumin and DDB can influence and improve the impaired antioxidant defense mechanisms resulted from ethanol and combined treatment with curcumin and DDB has no effects.

Key word: antioxidant, curcumin, DDB.

Introduction

Oxidative stress and decreased antioxidant status induced by ethanol metabolism play a major role in the causation of alcohol toxicity and damage (Dey and Cederbaum, 2006). Curcumin (diferuloylmethane), an aromatic yellow compound isolated from the root of curcuma longa, is a chemopreventive agent with a multiple mechanism of action (Surh, 2002 & Duvoix et al., 2004) and has been described in traditional Chinese medicine for treatment of different inflammatory disorders, anti-infectious, antifibrotic and anticancer activities in cells and animal disease and exerts beneficial effects in animal models of liver injury and cirrhosis (Goel et al., 2008 Epstein et al., 2010; Aggarwal, 2010).

Rong et al., 2012, showed that chow-fed mice that were administered high amounts of ethanol (4 g/kg/day) were protected against oxidative stress by curcumin treatment. There is as well evidence that curcumin reduces inflammation through the inhibition of NF- κ B in ethanol-treated rats (Nanji et al., 2003). However, both oxidative stress and inflammation are secondary effects that occur in response to chronic alcohol intoxication due to the accumulation of metabolic byproducts from the alcohol metabolism. To date, the effect of curcumin supplementation on the alcohol metabolism enzyme activity in animals that are intoxicated daily is unknown (Rivera-Espinoza and Muriel, 2009). preceding studies have typically used high doses of curcumin, which translate into human doses (N8 g/day). Curcumin also known to trigger apoptosis in cancer cells at high concentrations (Epstein et al., 2010) and may even promote or exacerbate liver damage at high doses in mice (Zhao et al., 2012).

Comment: original article :[1Office]Comment or mini review?

Commenr: On title without :[2Office]Comment short word

Commenr: what's the :[3Office]Comment meaning short word

Commenr: what'e latin :[4Office]Comment name

Commenr: please see :[5Office]Comment guidelines in writing references

Commenr: On italic style? :[6Office]Comment

Commenr: please see :[7Office]Comment guidelines in writing references

Commenr: please see :[8Office]Comment guidelines in writing references

Commenr: please see :[9Office]Comment guidelines in writing references

Commenr: please see :[10Office]Comment guidelines in writing references

Commenr: please see :[11Office]Comment guidelines in writing references

However, it is unclear whether lower curcumin doses are sufficient to promote hepatoprotective effects against excessive daily alcohol intake.

Dimethyl diphenyl bicarboxylate (DDB) is a synthetic mimic of the natural product Schisandrin C, a component of Fructus Schisandrae chinensis (Shen et al., 1987). It has been registered as liver support medication in China (Lee, 2002) and it is currently used for treatment of chronic viral hepatitis B and C in Asia (Sun and Liu, 2005) and in Egypt (Salama et al., 2004 and Montasser, 2001). The aim of the present study is to determine the physiological and histological changes in rats drinking alcohol and treated with curcumin and/or DDB.

Materials and methods

The present study was conducted on thirty male albino Wistar rats, weighing 200-230g of each rat that were obtained from Helwan animal station, Ministry of Health, Egypt. Animals were allowed to adapt for two weeks and housed in animal house of Zoology Department of Damietta faculty of Science, Damietta University, Egypt. Rats were divided into 5 groups each of 6 animals, **Control group**: rats given normal diet and water for 8 weeks, **Ethanol group**: rats were given 20% ethanol in drinking water for 8 weeks, **Ethanol & curcumin group**: rats were given 20% ethanol in drinking water and curcumin 100mg/kg body weight mixed in diet for 8 weeks, **Ethanol & DDB group**: rats were given 20% alcohol in drinking water and DDB 50mg/kg body weight mixed with diet for 8 weeks, **Ethanol & curcumin & DDB group**: rats were given 20% alcohol in drinking water, curcumin 100mg/kg body weight and DDB 50mg/kg body weight mixed with diet for 8 weeks. At the end of the 8th week, rats were starved overnight, then sacrificed and blood samples were collected and centrifuged for serum separation. The large lobe of liver was cut and divided into two parts, one fixed in formalin and the other fixed in Zinker solution for histopathological studies.

I-Physiological studies:

1-Malondialdehyde (MDA):

MDA in serum and liver tissue homogenate were determined by the methods of Stock and Donnady, (1971) and Uchyama and Mibara, (1978) respectively. The method depends on the reaction between malondialdehyde and thiobarbituric acid (TBA) to form a colored complex which is measured at 520 nm and 532 nm. The difference between the two values represents MDA concentration.

2-Determination of ALT and AST enzymes:

The method was done according to the method of Reitman and Frankel (1957).

3-Determination of GGT enzyme:

γ -glutamyl transferase catalysis is the transfer of a γ -glutamyl group from γ -glutamyl-3-carboxy-4-nitroanilide to glycylglycine with the formation of L- γ -glutamyl-glycylglycine and 5-amino-2-nitrobenzoate. The amount of 5-amino-2-nitrobenzoate formed, measured colorimetrically at 405 nm which is proportional to the enzyme activity present in the sample (IFCC, 1983).

II-Histopathological study

1-H/E stain:

Liver tissue specimens were fixed in 10% formalin and embedded in paraffin wax and 5 micrometer thickness were cut. Sections were stained with H/E stain according to Duray and Willington, (1967).

2-Masson trichrome stain:

The method was done according to Carlton, (1976). Briefly, liver specimens were fixed in Zinker solution for 24 hr's, washed in 50% alcohol and treated with

Comment: please see :[13Office]Comment guidelines (Capital letter)

Comment: please without :[14Office]Comment number in each heading and see guidelines

diluted iodine solution, then washed in 3% sodium thiosulphate. Sections were stained firstly with haematoxylen, then with Masson A solution for 5 minutes. They were washed in distilled water and stained with Masson B solution for 5 minutes and differentiated in 1% phosphomolybdic acid for 5 minutes, stained with 2.5% fast green solution for 2 minutes, then differentiated in 1 % glacial acetic acid. Sections were dehydrated, cleared in xylene and mounted with DPX.

III-Statistical analysis:

Student –T test was performed using the statistical program package, SPSS, version 14. Degrees of significance were as follow, significant, $P<0.05$; highly significant, $P<0.01$ and extremely significant, $P<0.001$.

Results

Liver enzymes:

The activity of AST enzyme was increased significantly in rats drinking alcohol. After treatment with curcumin and DDB, the activity of AST enzyme was decreased significantly ($P<0.05$) compared with the alcohol drinking rats. However, after mixed treatment with DDB and curcumin the activity was increased compared with alcohol drinking rats as well as alcohol drinking rats and treated with curcumin or DDB (**Table,1**). ALT enzyme was decreased significantly in rats drinking alcohol and treated with DDB compared with alcohol drinking alcohol.

Malondialdehyde of serum and tissue homogenates:

Table(1) indicates that. The level of malondialdehyde was elevated significantly in rats drinking alcohol($P<0.05$), but after treatment with curcumin and DDB, the level of malondialdehyde was decreased compared with alcohol drinking rats.

In case of mixed treatment with curcumin and DDB, the level of MDA was decreased significantly compared with normal group and those drinking alcohol ($P<0.05$).

In liver tissue homogenate, A significant increase was observed in rat drinking alcohol as well as rat drinking alcohol but treated with a mixture of curcumin and DDB compared with normal rats **Table(1)**. However, no significant differences were observed between other groups and normal group.

GGT:

GGT enzyme activity, was significantly elevated in rats drinking alcohol compared with normal rats ($P<0.05$). On the other hand, in rats drinking alcohol and treated with curcumin and/or DDB, the levels were decreased significantly ($P<0.05$), (Figure, 3).

Lipids and Cholesterol:

Table(2) indicates that. The level of malondialdehyde was elevated significantly in rats drinking alcohol($P<0.05$), but after treatment with curcumin and DDB, the level of malondialdehyde was decreased compared with alcohol drinking rats.

In the case of mixed treatment with curcumin and DDB, the level of MDA was decreased significantly compared with normal group and those drinking alcohol ($P<0.05$).

Commenr: please see :[15Office]Comment
paragraph spacing as guidelines

Commenr: please see :[16Office]Comment
guidelines in writing result. In each table may have
much parameter result. Don't rewriting much tables

In liver tissue homogenate, A significant increase was observed in rat drinking alcohol as well as rat drinking alcohol but treated with a mixture of curcumin and DDB compared with normal rats **Table(1)**. However, no significant differences were observed between other groups

Discussion

It is well known that, prolonged alcohol intake resulted in alcoholic liver disease worldwide (**Lieber, 2004**). Alcohol metabolism byproducts promote the development of steatosis that can progress to hepatitis, fibrosis, cirrhosis, liver failure and/or hepatocellular carcinoma (**Seth et al., 2011**). Liver aminotransferases (ALT & AST) are sensitive indicators for the hepatic function and their excessive leakage into the blood circulation is usually associated with impaired hepatocellular function and designates the disruption of integrity of hepatic cell membranes (Patrick-Iwuanyanwu et al., 2007 ; Wafay et al., 2012).

In the present study ALT and AST enzymes activity were elevated in rat drinking alcohol. At the same time the activity of GGT enzyme also elevated in rat drinking alcohol. This may be due to increased permeability, damage and/or necrosis of hepatocytes in ethanol treated rats. The histopathological findings of the present study cleared that, alcohol drinking results in alteration of normal architecture of liver tissue and deposition of collagen fibers around the central vein(**Haung et al., 2005, Uzzun et al., 2005 and Hussein 2007**)

Together with the above findings in the present study, GGT enzyme activity was increased significantly in rats drinking ethanol compared with normal rats. **Lee et al., (2004)** suggested that, serum GGT within its normal range might be an early and sensitive enzyme related to oxidative stress. These results agree with that of **Husein et al., (2007)**, who found that, ethanol administration increases the level of GGT as well as those findings of **Kode et al., (2007)**. **Rukkumani et al., (2004)**, reported that, the increased activity of GGT is suggestive of severe hepatic injury during alcohol ingestion.

The excess byproducts of alcohol metabolism can cause oxidative stress, lipid peroxidation and inflammation and promote fat accumulation through the inhibition of the cellular energy regulator AMP-activated protein kinase (AMPK) (**Chen et al., 2010**). The present data indicated that, MDA elevated after drinking alcohol. These results agree with that of **Das and vasudevan, (2007)** in which ethanol treatment results in the depletion of GSH level, elevation of MDA and hydroxyl radical causing

modification of all biological structures and consequently resulted in serious malfunction of cells and tissues.

Curcumin is a poly phenolic compound isolated from the rhizomes of *Curcuma longa* (turmeric). This compound exhibits a wide range of anti-fibrotic properties, including anti-epithelial-mesenchymal transition, anti-apoptosis, anti-oxidation, and anti-inflammation properties (Zhou et al., 2014).

In the present study, treatment of alcoholic rats with curcumin leads to reduction of ALT and AST enzyme activity and improvement of histopathology of liver tissue such as reduced morphological changes and decreases the degree of necrosis and fibrosis and decreased collagen fibers around portal vein. These findings agree with other studies that conducted with other hepatotoxic substances such as CCl₄ and paracetamol (**Fu et al., 2008 and Kumar et al., 2008**).

Various pathways play a role in ethanol induced tissue injury, including, production of acetaldehyde protein adducts (**Tuma et al., 1996**), formation of 1-hydroxyle free radical (**knecht et al., 1993**) and changes in cellular oxidized NAD⁺, NADH (**Loher, 2000**). Treatment of alcoholic rats with curcumin significantly improved the level of GGT enzyme. This result confirm the result of **Rukkumani et al., (2004)**, who found that administration of curcumin improved the antioxidant status and thereby prevented the damage to the liver and decreases GGT activity. This is mainly because of the antioxidant sparing action of curcumin (**Rukkumani et al., 2004**).

Ethanol exposure resulted in reactive oxygen species(ROS) generation, malondialdehyde elevation(MDA), glutathione(GSH) depletion and antioxidant system impairment, which were significantly reversed by curcumin treatment(**Girish et al., 2009**) such results were observed in the present study in which the level of malondialdehyde was elevated after alcohol consumption .

Curcumin is a compound derived from the spice turmeric, a spice that is a potent antioxidant, anti-carcinogenic, and anti-hepatotoxic agent (**Kuo et al., 2012**) and could ameliorate ethanol-induced hepatocytes oxidative stress in vitro(**Rong S et al., 2012**). In vivo, it has been found that, curcumin ameliorate the evident release of cellular alanine aminotransferase (ALT) and aspartate aminotransferase (AST) Balb/c mice. Also (**Rong S et al., 2012**) concluded that, curcumin provided protection against chronic ALD and the mechanism might be related to the alleviation of

oxidative damage. This was explained by the reduction of MDA in rats drinking ethanol and treated with curcumin. The findings of Lee et al.,(2013) indicates that low doses of curcumin may protect against liver damage caused by chronic alcohol intake and a high-fat diet partly by modulating the alcohol metabolic enzyme activity . Therefore, curcumin may provide a promising natural therapeutic strategy against liver diseases. The results of Ronga et al., (2012), showed that curcumin attenuated ethanol-induced histopathological changes of liver and ameliorated the evident release of cellular alanine aminotransferase (ALT) and Aspartate aminotransferase(AST) .

At the same time, in the present study, treatment of alcoholic rats with DDB also significantly reduces the serum level of GGT. However treatment with mixture of curcumin and DDB elevate the level of GGT.

References

- Aggarwal BB. 2010** Targeting inflammation-induced obesity and metabolic diseases by curcumin and other nutraceuticals. *Annu Rev Nutr*;30:173–99.
- Bruck, R.; Ashkenazi, M.; Weiss, S.; Goldiner, I.; Shapiro, H.; Aeed ,/ H.; Genin, O.; Helpern, Z. and Pines, M. (2007).** Prevention of liver cirrhosis by curcumin. *Liver Int.*, 27(3):373-383.
- Chen Z, Li Y, Yu C, Shen Y, Xu L, Xu C, et al. 2010.** A cohort study of the effect of alcohol consumption and obesity on serum liver enzyme levels. *Eur J Gastroenterol Hepatol*;22: 820–5.
- Das SK, Vasudevan DM (2007).** Alcohol-induced oxidative stress. *Life Sci.*, 81(3):177-87.
- Dey, A. and Cederbawn, A (2006).** Alcohol and Oxidative Liver injury. *Hepatol.*, 43: S63-S74
- Drury, R.A.B. and Walligton, E.A. (1967).** *MaUn Carlton's Histological techniques.* Oxford University Press, 4th ed, p: 129.
- Duvoix, A.; Blasius, R.; Delhalle, S.; Schnekenburger, M.; Morceau, F.; Henry, E.; Dicato, M. and Diederich, M. (2004).** Chemopreventive and therapeutic effect of curcumin. *Cancer Lett .*, 215: 1-10.
- Epstein J, Sanderson IR, Macdonald TT. 2010** Curcumin as a therapeutic agent: the evidence from in vitro, animal and human studies. *Br J Nutr*;103:1545–57.

Comment: please see :[17Office]Comment guidelines in writing references about vol, Ed, page, without bold letter and DOI in all references

- Fu Y, Zheng S, Lin J, Ryerse J, Chen A. (2008).** Curcumin protects the rat liver from CCl₄-caused injury and fibrogenesis by attenuating oxidation stress and suppressing inflammation. *Mol Pharmacol.*;73:399–409.
- Girish C, Koner BC, Jayanthi S, Ramachandra Rao K, Rajesh B, Pradhan SC. (2009).** Hepatoprotective activity of picroliv, curcumin and ellagic acid compared to silymarin on paracetamol induced liver toxicity in mice. *Fundam Clin Pharmacol.* 23(6):735-45.
- Goel A, Kunnumakkara AB, Aggarwal BB. (2008).** Curcumin as 'curecumin': from kitchen to clinic. *Biochem Pharmacol.*;75:787–809.
- Goldberg, D.M. and Watts, C. (1965).** Serum enzyme changes as evidence of liver reaction to oral alcohol. *Gastroenterol.*, 49: 256-261.
- Huang, C.C.; Chen, J.R.; Liu, C.C.; Chen, K.T.; Shieh, M.J. and Yang, S.C. (2005).** Effects of long-term ethanol consumption on jejunal lipase and disaccharidase activities in male and female rats. *World J Gastroenterol.* 11(17): 2603-2608.
- Hussein, J.S. Oraby, F.S. and El-Shafey, N. (2007).** Antihepatotoxic effect of Garlic and Onion Oils on Ethanol-induced Liver Injury in rats. *J. Appl. Sci. Res.*, 3(11): 1527-1533
- IFCC (1983).** Methods for the measurement of catalytic concentration of enzymes Part 4. IFCC method for γ -glutamyltransferase. *J Clin. Chem. Clin. Biochem.* 21: 643-646.
- Knecht, K.T.; Thurman, R.G. and Mason, R.P. (1993).** Role of superoxide and trace transition metals in the production of α -hydroxyethyl radical from ethanol by microsomes from alcohol dehydrogenase-deficient deer mice. *Arch. Biochem. Biophys.*, 303: 339-348.
- Kode, A.; Rajagopalan, R.; Penumastha, S. V. and Menon, V. P. (2007).** Role of an Aminothiazole Derivative on Ethanol-Induced Toxicity. *Toxicol, Mechanisms and Methods*, 17(1): 33-40.
- Kumar, D.S. and Vasudevan, D.M. (2007).** Alcohol-induced oxidative stress. *Life Sci.*, 3: 177-187.
- Kuo JJ, Chang HH, Tsai TH, Lee TY. (2012).** Curcumin ameliorates mitochondrial dysfunction associated with inhibition of gluconeogenesis in free fatty acid-mediated hepatic lipoptosis. *Int J Mol Med.* 10.3892/ijmm.1020.

- Lee, K.H. (2000):** Research and future trends in the pharmaceuticals, development of medicinal herbs from Chinese medicine. *Public Health Nut.*, 3: 515-522.
- Lieber CS. (2004).** Alcoholic fatty liver: its pathogenesis and mechanism of progression to inflammation and fibrosis. *Alcohol*;34:9–19.
- Marsano, L. and McClain, C.J. (1989):** Effects of alcohol on electrolytes and minerals. *Alcohol. Health Res. World*, 13(3): 255- 260.
- Montasser, M.F. (2001):** Clinical and laboratory studies of DDB in treatment of chronic hepatitis C: 4-Combination therapy with amantadine hydrochloride, a pilot study in Egypt. *Ain Shams Med.*
- Nanji AA, Jokelainen K, Tipoe GL, Rahemtulla A, Thomas P, Dannenberg AJ. 2003.** Curcumin prevents alcohol-induced liver disease in rats by inhibiting the expression of NF-kappa B-dependent genes. *Am J Physiol Gastrointest Liver Physiol*;284: 321–7.
- Park, E.1.; Jeon, C.H.; Ko, G.; Kim, J. and Sohn, D.H. (2000):** Protective effect of curcumin in rat liver injury induced by carbon tetrachloride. *J. Pharm. Pharmacol.*, 52: 437-440.
- Radosavljević T, Mladenović D, Vučević D. (2009):** The role of oxidative stress in alcoholic liver injury. *Med Pregl.* 62(11-12):547-53.
- Reitman, S. and Frankel, S. (1957):** A colorimetric method for the determination of serum glutamate oxaloacetic and glutamate pyruvic transaminases. *Am. J. Clin. pathol.*, 28(1): 56-63.
- Rivera-Espinoza Y, Muriel P. 2009.** Pharmacological actions of curcumin in liver diseases or damage. *Liver Int*;29:1457–66.
- Rong S, Zhao Y, Bao W, Xiao X, Wang D, Nussler AK, et al. 2012.** Curcumin prevents chronic alcohol-induced liver disease involving decreasing ROS generation and enhancing antioxidative capacity. *Phytomedicine*;19:545–50.
- Rong S, Zhao Y, Bao W, Xiao X, Wang D, Nussler AK, Yan H, Yao P, Liu L. (2012):** Curcumin prevents chronic alcohol-induced liver disease involving decreasing ROS generation and enhancing antioxidative capacity. *Phytomedicine.* ;19(6):545-50.
- Rukkwnani, R.; Aruna, K.; Varma, P.S.; Rajasekaran, K.N. and Menon, V.P. (2004):** Comparative effects of curcumin and an analog of curcumin on alcohol and PUF A induced oxidative stress. *J Pharm. Pharmaceut. Sci.*, 7(2):

274-283.

- Salama, H.M.; Amer, A.R.; Hammad, O.M. and El-Sayed, W.F. (2004):** Effect of DDB monotherapy and in combination with amantadine hydrochloride and ribavirin in patient with chronic hepatitis C virus infection. *Sci. J.Med. J. ESCA, fE.*, 16: 1.
- Seitz, H.K.; Salaspuro, M.; Savolainen, M.; Haber, P.; Ishii, H.; Teschke, R.; Moshage, H. and Lieber, C.S. (2005):** From Alcohol Toxicity to Treatment. *Alcohol. Clin. Exp. Res.*, 29: 1341-1350.
- Seth D, Haber PS, Syn WK, Diehl AM, Day CP. (2011).** Pathogenesis of alcohol-induced liver disease: classical concepts and recent advances. *J Gastroenterol Hepatol*; 26:1089–105.
- Shen, D.G.; Araki, M.; Higuchi, I.; Matsumoto, K.; Tarnai, M.; Liu. K.T. and Sugita, H. (1987):** The effect of DDB on dystrophic hamsters an in vivo and in vitro study. *Muscle and Nerve*, 10: 391- 396.
- Sun, H. and Liu, G.T. (2005):** Chemopreventive effect of dimethyl dicarboxylate biphenyl on malignant transformation of WB-F344 rat liver epithelial cells. *Acta. Pharmacol. Sin.*, 26: 1339-1344.
- Surah, YJ. (2002):** Anti-tumor promoting potential of selected spice ingredients with antioxidative and anti-inflammatory activities: a short review. *Fd. Chem. Toxicol.*, 40: 1091-1097.
- Uchiyama, M. and Mihara, M. (1978):** Determination of I malonaldehyde precursor in tissues by the thiobarbituric acid test. *Anal. Biochem.* 86: 271-278.
- Uzun, H.; Simsek, G.; Aydin, S.; Unal, E.; Karter, Y.; Yelmen, N. K.; L//Vehid, S.; Curgunlu, A. and Kaya, S. (2005):** Potential effects of L-NAME on alcohol- induced oxidative stress. *World J. Gastroenterol.*, 11(4): 600-604.
- Zhao HL, Song CH, Chai OH. 2012.** Negative effects of curcumin on liver injury induced by alcohol. *Phytother Res*;26:1857–63.
- Table (1): Serum and liver tissue MDA and total proteins of rats dinking ethanol and treated with CCM and / or DDB for 8 weeks .**

groups	Serum MDA Mean ± SD	liver MDA Mean ± SD	Serum total protein g/dl
Normal control (n=6)	0.008 ±0.0008	0.08 ±0.019	8.19±0.89
Ethanol drinking (n=6)	0.01±0.001 P1=0.0003	0.10±0.007 P1=0.034	6.91±0.36 P1=0.008
Ethanol & Curcumin (n=6)	0.007±0.002 P1= NS P2=0.008	0.091±0.04 P1=NS P2=NS	8.29±0.29
Ethanol & DDB (n=6)	0.01 ± 0.001 P1=0.016 P2=NS	0.08 ± 0.02 P1= NS P2=0.0233	7.52±.29 P2=0.009
Ethanol& Curcumin & DDB (n=6)	0.009 ± 0.002 P1=NS P2=NS	0.14 ± 0.06 P1=0.0341* P2=NS	7.09±0.59 P1=0.03

Comment: please see :[18Office]Comment guidelines as open tables style and mark as heading in each tables

Comment: all numbers in :[19Office]Comment 2 decimal except for p 3 decimal

P1 compared with normal group. P2 compared with ethanol drinking group.* significant.**highly significant.*** Extremely significant.

Table (2): Serum activity of liver enzymes of rats dinking ethanol and treated with CCM and / or DDB.

Groups	ALT (IU/L) Mean ± SD	AST (IU/L) Mean ± SD	GGT(U/L) Mean ± SD
Normal	37.0 ± 8.29	51.5 ± 6.69	1.02±0.20
Ethanol	44.0 ± 8.29 P1=NS	69.6 ± 6.44 P1=0.0008	1.5 ±0.45 P1=0.04
Ethanol & CCM	39.0 ± 7.89 P1=NS P2=NS	56.5 ± 3.99 p1=NS p2=0.0018**	0.83±0.46 P1=0.40 P2=0.03
Ethanol & DDB	26.20 ± 2.04 p1=0.0005*** p2=0.0111***	60.2 ± 5.73 p1<0.0367* p2<0.0243*	0.83±0.43 P1=0.37 P2=0.02
Ethanol & CCM & DDB	38.0 ± 7.18 P1=NS P2=NS	80.1 ± 3.87 p1=0.0001* p2=0.0063*	1.39±0.10 P2=0.70

P1 compared with normal group. P2 compared with ethanol drinking group.* significant.**highly significant.*** Extremely significant.

Table(3) Serum total lipids, cholesterol and triglycerides of rats dinking ethanol and treated with CCM and / or DDB.

Mice groups	Total lipids	Cholesterol	Triglycerides
Normal control (n=6)	0.34 ±0.043	60.3 ±9.75	43.9 ±4.44
Ethanol drinking (n=6)	0.4±0.072 <i>P1=NS</i>	60.8±8.11 <i>P1=NS</i>	59.5±6.41 <i>P1=0.0041</i>
Ethanol& Curcumin (n=6)	0.47±0.035 <i>P1=0.0001</i> <i>P2=0.0324</i>	60.9±4.58 <i>P1=NS</i> <i>P2=NS</i>	60.8±5.51 <i>P1=0.0002</i> <i>P2=NS</i>
Ethanol & DDB (n=6)	0.52 ± 0.034 <i>P1=0.0001</i> <i>P2=0.0022</i>	61.4± 10.3 <i>P1=NS</i> <i>P2=NS</i>	51.1± 6.34 <i>P1=0.0465</i> <i>P2=0.0457</i>
Ethanol& Curcumin & DDB (n=6)	0.35 ± 0.041 <i>P1=NS</i> <i>P2=NS</i>	57.6± 9.48 <i>P1=NS</i> <i>P2=NS</i>	56.9± 7.59 <i>P1=0.0049</i> <i>P2=NS</i>

P1 compared with normal group.

P2 compared with ethanol drinking group.

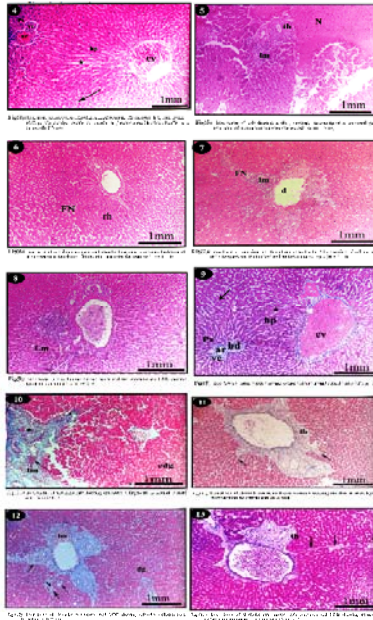
* significant.

**highly significant.

*** Extremely significant.

Figure, 3

Biochemical and histological Study on the Effects of Curcumin.



Comment: can you show ;[20Office]Comment the information of Biochemical and histological with arrow sign?