

**Biochemical, Histopathological and Mutagenic
Changes Following the Co-Administration of
Anthelmintic and Antimalarial Drugs in Wistar
Rats**

ABSTRACT

Aim

To determine the effects of antimalaria and anthelmintic drugs combination in the incidence of histopathological alteration and biochemical modulations in liver and kidney of albino rats.

Place and duration of study

The study was undertaken at the Zoology Department University of Lagos Akoka Lagos Nigeria.

Methodology

A total of twenty (25) Male adult albino rats of 13-15 weeks old were divided into 5 groups of 5 rats each and daily oral administration of human therapeutic doses of praziquantel (PZQ 50mg/kg body weight) separate and in combination with ivermectin (IVM 0.4mg/kg body weight), albendazole (ALB 15mg/kg body weight) and Artemether-lumefantrine (ACT 140mg/kg body weight) was administered with the group which serve as the control receiving 1ml distilled water. Toxic effects due to these treatments were investigated using histopathological, biochemical and mutagenic indices at day 8th and 15th of the study.

Result

Biochemical assessment revealed significant reduction in AST, ALT, ALP and potassium in the treatment group compared to the control. Increase in the level calcium, Albumin and bicarbonate were also observed in treatment groups. Histopathological assessment of the liver showed a general incidence of focal inflammation along the portal tract area, but did not show any differential severity across treatment groups except for single PZQ treatment group which were characterized by fatty infiltration. A general occurrence of mesangial damage and glomerula injury was observed in kidney tissues. Renal lesions were more severe in single PZQ +IVM treatment groups while mild lesions characterized renal tissue from PZQ+ACT treatment groups. Mutagenic effects as indicated by the high incidence of sperm head abnormalities was recorded across combination treatments especially in PZQ+IVR and PZQ+ ACT groups.

Conclusion

Findings suggest that combination therapies are synergistic and could result in nephrotoxicity, antidiuretic effects, dehydration and mutagenicity at human therapeutic doses.

Keywords: Nephrotoxicity, Praziquantel, Combination-therapy, Human therapeutic doses, sperm head abnormalities

1.0 INTRODUCTION

17 The rise in global disease burden has seen an increased therapeutic use of drugs with
18 unknown/poorly understood toxic potential [1]. Many of such implicated drugs include those
19 with adaptable therapeutic applications, which often characterize interventions for public
20 health issues like parasitic infections [2]. Recent reports indicate that parasitic and infectious
21 diseases account for about 25% with a bulk of these incidences occurring in Africa,
22 Southeast Asia and Eastern Mediterranean regions [2][3]. Some of the most documented
23 incidences include high incidence of soil-transmitted helminthes infections among children
24 [4] and maternal and infant mortality cases worldwide attributable to malaria annually
25 particularly in Africa [5].

26 Aside fundamental factors like drug availability and costs, current therapeutic use and
27 clinical discretion exercised during the application of antiparasitic drugs are largely guided by
28 the increased incidence of drug-resistant parasites, and the characteristic narrow options of
29 medications for parasitic infections [5][6]. Over time adaptive interventions for helminthic
30 diseases and protozoan infections have included single-dose, safe, and relatively cheap
31 drugs to drugs with a broad-spectrum activity, but with the incidence of drug-resistant
32 pathogen species, elucidation and subsequent insight into the mechanisms underlying
33 intrinsic and acquired drug-resistance has resulted in drug repurposing and development of
34 rational combination therapies to overcome toxicity and resistance [7].

35 The therapeutic administration of drugs and combination therapies have however
36 demonstrated potential for tissue injury or toxicity even when introduced within specified
37 therapeutic ranges [8][1]. Such toxicity may result not only from direct toxicity of the primary
38 compound but also from a reactive metabolite or from an immunologically-mediated
39 response affecting particular cells or tissues [9] which in turn could result in pathological
40 outcomes [10]. Other studies have implicated the administration of drug combinations with an
41 increased production of Reactive Oxygen Species (ROS) [11]. Post-drug intake effects in
42 organs have been a key strategy for monitoring and determining drug-related toxicities [12].
43 It is against this background that this study investigated the role of antimalaria and

44 anthelmintic drug combinations in the incidence of histopathological alterations and
45 biochemical modulations in liver and kidney of Albino rats and also observing possible
46 mutagenic changes.

47 **2.0 MATERIALS AND METHOD**

48 **2.1 Test animals**

49 A total of twenty-five (25) male adult albino rats (*Rattus norvegicus*) Wistar strain of 13-15
50 weeks old with an average weight of $180\text{g}\pm 20$ were used for the studies. The animals were
51 purchased from an animal farm located in Ikorodu Lagos Nigeria and were maintained in the
52 laboratory for 15 days with cross ventilation at controlled room temperature ($27\pm 2^\circ\text{C}$) and
53 relative humidity (40-60%) with a 12-hour light and dark cycle to acclimatize in the laboratory
54 before the commencement of exposure period. All the rats were housed in conventional
55 plastic cages. These standard cages were bedded with dry wood shavings, which were
56 changed every 2 days to prevent maggotry. The animals were provided daily with fresh
57 supply of standard feeds weighing 150g and water *ad libitum*.

58 **2.2 Drug treatment and Sample preparations**

59 Praziquantel (PZQ), Albendazole (ALB), Ivermectin (IVM) and Artemether-Lumefantrine (A-
60 L) were used for study. The praziquantel tablet manufactured by BDH industries limited
61 Mumbai india was purchase from a local pharmacy in Lagos Nigeria. Ivermectin Mectizan® a
62 product of Merck & Co., Inc., Whitehouse station, New Jersey, USA was obtained from D-hub
63 pharmacy Ikeja. Albendazole (Zentel) manufactured by SmithKline Beecham laboratories
64 pharmaceuticals France and Artemether-Lumefantrine (Lonart Ds) manufactured by Bliss
65 GVS pharmacy limited India was purchased from the University of Lagos community
66 pharmacy. The drugs were grounded separately with mortar and pestle, weighed and
67 measured at different concentration depending on the mean body weight of the experimental
68 groups.

69 **2.3 Experimental Design**

70 Before exposure physical parameters such as laboratory temperature and humidity was
71 determined. The human therapeutic dose for each drugs PZQ, IVM, ALB and ACT are
72 50mg/kg, 0.4mg/kg, 15mg/kg, and 140mg/kg body weight respectively. For the experiment
73 there were 5 groups containing 5 rats (Table 1).

74
75

Table 1: Exposure group and treatments

S/N	GROUPS	MEAN WEIGHT OF RATS (g)	DRUG ADMINISTERED
1	Control	141.2	1ml distilled water
2	PZQ alone	182.4	Praz 9.12mg
3	PZQ + IVM	190	Praz 9.5mg +Ivr 0.08mg
4	PZQ+ ALB	166	Praz 8.3mg + Abz 2.49mg
5	PZQ + ACT	147.8	Praz7.39mg +ACT 20.7mg

76

77 **2.4 Drug administration**

78 The administration of drugs commenced 15 days after acclimatisation as described by Ismail
79 *et al* [13] using oral route for 15 days for all groups except for group 5 in which ACT was
80 administered at the last 3 days of exposure, after which they were sacrificed 24hrs after the
81 last dose was administered based on the methodology by [14]. Animals were weighed after
82 acclimatisation on the first day of exposure and the record served as the initial body weight
83 (Day 0). The procedure was repeated on the 8th day of exposure and before sacrificing at the
84 expiration of the required time of exposure and value obtained served as the final body
85 weight. The animals were observed daily for any clinical sign or behavioral changes.

86

87 **2.5 Collection of blood and tissues**

88 Blood specimen was collected in lithium heparin bottles and fluoride oxalate bottles. Liver,
89 kidney and the cauda epididymis were excised. The cauda epididymis was used for

90 mutagenicity examination. The internal organs were placed in a plain bottle and Buoin's fluid
91 added to preserve the specimen for histopathological examination.

92 **2.6 Biochemical analysis**

93 The method according to [15][16][17] was used to determine the biochemical parameters.
94 Blood sample collected during heart excision of rats was used for quantitative determination
95 of protein, albumin, alanine aminotransferase (ALT), aspartate aminotransferase (AST) and
96 alkaline phosphatase (ALP), urea, total bilirubin and creatinine, inorganic phosphate,
97 cholesterol, fasting glucose, Na⁺, K⁺, Ca⁺⁺ and Cl⁻ using standard kits.

98 **2.7 Histological Preparations**

99 Representative liver tissue of each group was excised, trimmed of fat and other connective
100 tissue and prepared for histological studies. The tissue samples were fixed using 10%
101 normal saline for 24 hours and were later transferred into alcohol to remove excess water.
102 Thin section (4-5m) were cut and stained with hematoxylin and eosin (H&E) stain. Thereafter
103 the slides were examined under CX21 Olympus microscope of magnification of 40X
104 objective and their photomicrograph taken with a Canon (Meville, NY) Power Shot G2 digital
105 camera.

106 **2.8 Mutagenicity Assay**

107 Mutagenicity was determined from sperm head abnormalities. Four (4) male rats were
108 sacrificed for each group by cervical dislocation after anesthetization. The caudaepididymis
109 excised from the male rat were placed in a Petri-dish containing 1ml of physiological saline
110 and then minced and teased carefully well with fine scissors and forceps to release the
111 spermatozoa. After gentle pipetting, the suspension is separated from the tissue fragments
112 and a drop of 1% Eosin Y solution in the ratio (10: 1) was added to the suspension for 30
113 minutes. Air-dried smears were prepared on clean, grease-free glass slides using another
114 clean slide angularly positioned at 45° to spread the drop through the whole length of the
115 slide. The slides were then coded, randomized and cytologically examined under a binocular

116 light microscopy with 400x magnification. Sixteen separate slides were prepared for each
117 group for sperm examination. For each group, 2000 sperm cells were assessed for
118 morphological aberration according to the criteria of [18]. The percentage abnormality of the
119 sperm cells in the rats was calculated by using the mean value of the group.

120 % abnormality = $\frac{\text{Total no of abnormal sperm cells}}{\text{Total no of sperm cells}} \times 100$

121

122 **2.9 Statistical Analysis**

123 All data were expressed as mean \pm standard deviation. One-way analysis of variance
124 followed by Dunnett T₃ post hoc test was used for determining the statistical significance of
125 the data. A probability level of less than 5% ($p < 0.05$) was considered significant in all
126 instances. All statistical tests were performed with SPSS 21 version package and originlab
127 version 9.0.

128

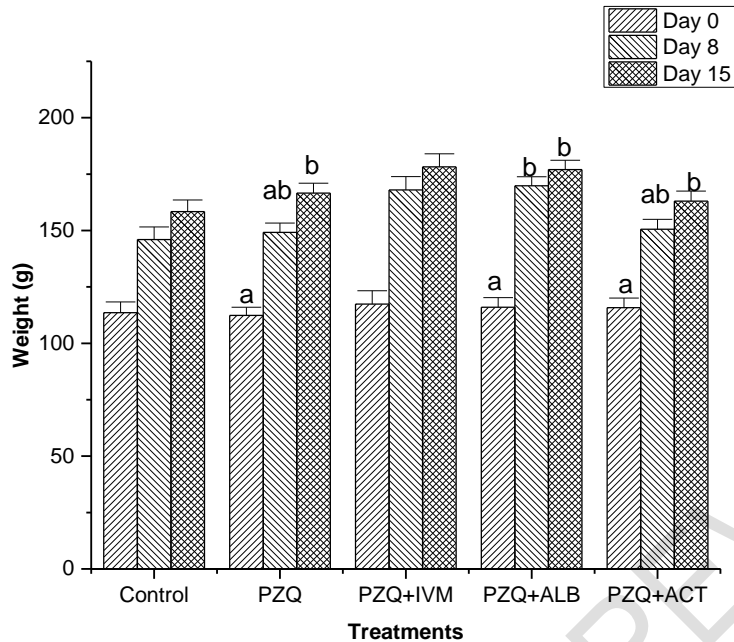
129

130 **3.0 RESULTS**

131

132 **3.1 Weight change across drug-treatment groups**

133 Change in weight of experimental animals was assessed at 8th and 15th day intervals during
134 the treatment period. Findings showed that exposure groups showed the highest weight
135 change occurred in the drug-treatment groups particularly in single praziquantel exposure
136 and Albendazole combinations. Both treatment groups showed higher significant weight
137 difference at the beginning and end of the experiment when compared to control and Praz +
138 ACT treatment group (Figure 1).



139

140 **Figure 1: Weight change across control and drug treatment groups (bars within the same group**
 141 **with the same alphabet are not significantly different, where error bar=standard error)**

142

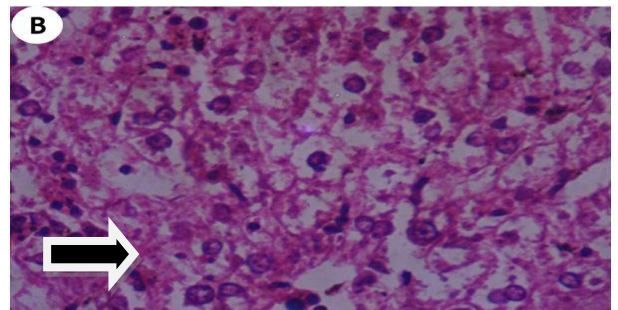
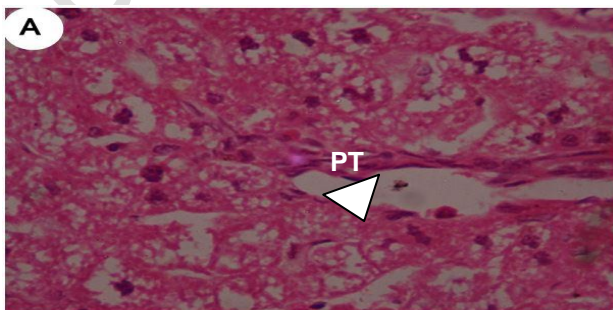
143 3.2 Histopathology

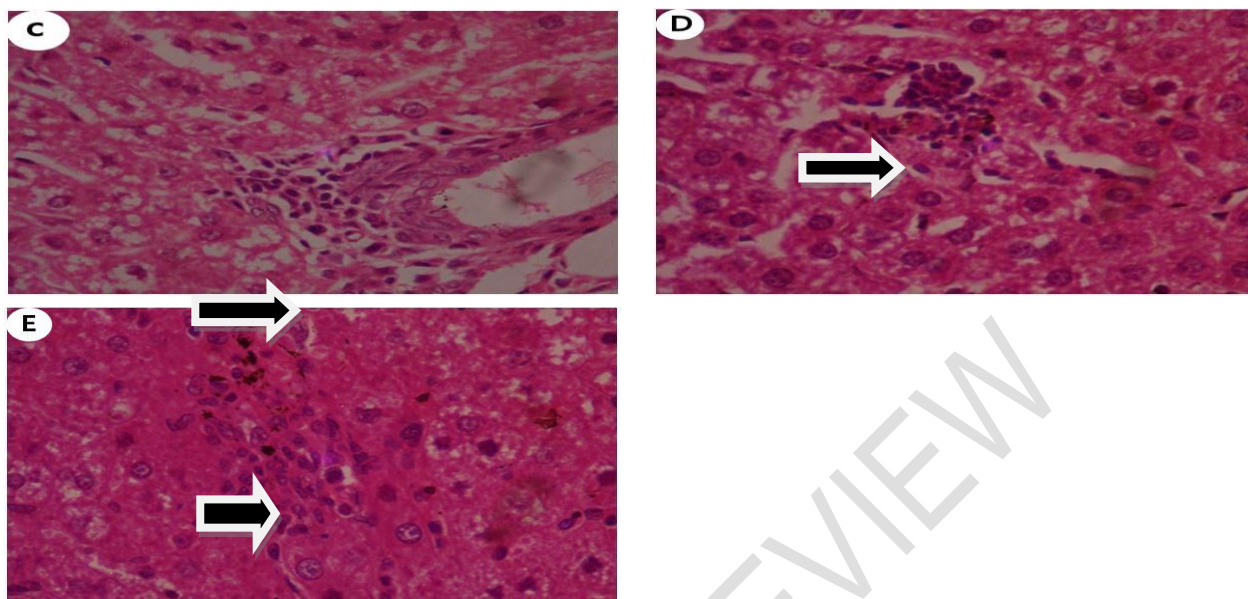
144

145 Histopathology for liver on slides C, D, E, show focal inflammation with subtle features of
 146 hepatocyte loss. Appearance of these cells suggests focal loss which can be through
 147 apoptosis/necrosis (Figure 2).

148 For the kidney sample, Plate A which is the control showed subtle features of lobulation of
 149 the glomeruli. While Plates B and C i.e. PZQ and PZQ+IVM administered rats respectively
 150 showed significantly higher levels of severity compared to plates D and E (Figure 3).

151 levels of severity compared to plates D and E (Figure 3).





152

153 Figure 2: A: Histological section of liver tissue of control albino rats showing normal hepatocytes, bi-
 154 nucleated cells, cytoplasm and nucleus surrounded by a nuclear membrane and nucleolus around the
 155 portal tract area (PT) (arrow head) (Magnification X40) B: Histological sections of liver of albino rat
 156 administered PZQ showing fatty infiltrations (long arrow) C: Histological section of liver of albino rat
 157 administered PZQ+IVM showing focal inflammation (long arrow) around hepatic portal tract area with subtle
 158 features of hepatocyte loss. D: Histological sections of liver tissue of albino rat administered PZQ+ALB
 159 showing focal inflammation (long arrow) with subtle features of hepatocyte loss. E: Histological section of
 160 liver tissue of albino rat administered PZQ+ACT showing focal inflammation (short arrow) with subtle
 161 features of hepatocyte loss.

162

163 3.3 Biochemical Analysis

164 Liver enzyme profile across experimental groups showed that at least one treatment group
 165 have significantly lower levels of AST, ALT and ALP (Table 2). Also result of analysis
 166 showed that drug-treatment groups showed significantly higher levels of albumin compared
 167 to the control while creatinine was higher in serum of control animals. Other biomolecule
 168 variables such as glucose, urea and cholesterol did not differ significantly between drug-
 169 treatment groups and control (Table 2).

170 Electrolyte profile analysis depicted that ALB+IVM combination treatments showed
 171 significantly higher levels of sodium ion in serum compared to the control, while all treatment
 172 groups showed significantly lower levels of potassium ion compared to the control. All
 173 treatment groups showed significant elevated levels of calcium ion in serum compared to the

174 control while all treatment groups except the ACT combination treatment group showed
 175 significantly lower levels of phosphate ion in serum compared to the control. Bicarbonate ion
 176 levels were significantly elevated in treatment groups compared to the control while
 177 significant loss of chlorine ion in serum was recorded in the IVM drug-treatment group
 178 compared to the control.

179 **Table 2: Analysis of biochemical variables in rats from control and PZQ, PZQ+IVM,**
 180 **PZQ+ALB and PZQ+ACT treatment groups.**

Drugs exposure	AST (μ/L)	ALP (μ/L)	ALT (μ/L)	GLU (mmol/l)	UR (mmol/l)	ALB (mmol/l)	CRE (mg/d)	CHO (mmol/l)
Control (μ/L)	94.40 ± 27.07	44.64±10.59	32.00±14.93	5.32 ±0.83	5.10 ±3.09	37.46±2.8	60.60±7.3	2.10±0.4
PZQ (μ/L)	44.60 ± 15.13	33.14 ± 7.58	22.80 ±7.67	5.96 ±2.38	6.58 ±1.37	40.00±2.9	52.92±3.1	2.18±0.2
PZQ+IVM (μ/L)	48.50 ± 13.17	42.25 ±4.22	23.50 ±12.38	5.40 ±3.16	4.50 ±2.57	32.04±174	39.52±2236	1.82±1.6
PZQ+ALB (μ/L)	44.60 ±13.09	38.84 ±3.81	20.80 ±2.59	5.16 ±0.59	5.89 ±1.07	39.98±0.8	51.82±4.32	2.36±0.7
PZQ+ACT (μ/L)	57.40 ± 9.13	41.42 ±4.88	25.20 ±1.79	5.06 ±1.25	6.36 ±1.16	38.44±2.6	52.18±2.27	2.32±0.9

181 AST=Aspartate aminotransferase, ALP=Alanine phosphatase ALT=Alanine aminotransferase GLU=Glucose,
 182 UR=Urea, ALB=Albumin, CRE=Creatinine, CHO=Cholesterol
 183

184
 185 **Table 3: Electrolyte variables in rats from control and PZQ, PZQ+IVM, PZQ+ALB and**
 186 **PZQ+ACT treatment groups.**

Concentration of serum electrolytes	Control (μ/L)	PZQ (μ/L)	PZQ+IVM (μ/L)	PZQ+ALB (μ/L)	PZQ+ACT (μ/L)	Reference values
Na ⁺ (mmol/l)	142.9 ±5.52	142.6±1.22	115.6±6.66	143.7 ±1.01	142.0 ± 2.35	144.33meq/l
K ⁺ (mmol/l)	7.39 ±1.95	5.32 ± 0.62	4.73 ±2.67	5.75 ± 0.36	5.83 ± 0.58	5.26meq/l
Ca ²⁺ (mmol/l)	1.68 ± 0.09	1.99 ± 0.22	1.69 ± 0.98	1.87 ± 0.18	1.88 ± 0.13	10.17mg/dl
PO ₄ ²⁺	1.42 ±0.13	1.07± 0.25	1.04 ±0.05	1.31± 0.34	1.24± 0.22	1.8-2.3
HCO ₃ (mmol/)	12.00 ±4.79	15.40±3.91	12.00 ±7.04	14.20 ± 2.59	14.00 ±4.64	18-30
Cl ²⁺	102.0 ± 2.83	100.4±1.82	82.00 ± 4.8	102.6 ± 2.70	103.6 ±1.52	103.75meq/l

187 Na⁺= Sodium, K⁺= Potassium, Ca²⁺= Calcium, PO₄²⁺= Phosphate, HCO₃= Bicarbonate
 188 Cl²⁺= Chloride
 189
 190
 191

192 **3.4 Sperm head abnormality assessment**

193

194 Five different forms of sperm head abnormality were observed in the rat during the *in vivo*

195 evaluation of the drugs. These include pin head (most prominent), no hook, hook at wrong

196 angle, amorphous and bent sperm. The pin head sperm abnormality appeared

197 predominantly in both the control and exposed group.

198

199 **Table 4; Showing abnormal sperm cell recorded in experimental rats across treatment**
200 **and control groups**

GROUP	I.D	Normal	Amorphous	Bent	Wrong angle	No Hook	Pin head	Mean abnormal sperm cell	Mean no. of sperm cells	% Abnormal sperm
CONTROL	1	1670	30	45	-	-	-	68.25±49.14 ^a	1751.8 ± 52.43 ^a	3.8
	2	1708	30	7	28	-	38			
	3	1721	2	-	-	-	2			
	4	1635	-	-	-	-	60			
PZQ	1	1773	64	-	-	-	-	356.5±246.2 ^a	1677.0±226.38 ^a	21.25
	2	1384	44	-	40	-	250			
	3	680	176	395	30	-	65			
	4	1445	67	-	135	-	160			
PZQ+IVM	1	1281	209	123	123	-	238	710.8±182.3 ^b	1561.8±607.32 ^a	45.51
	2	689	210	175	-	-	270			
	3	235	35	154	20	-	20			
	4	1199	82	144	292	25	258			
PZQ+ALB	1	640	472	-	14	-	-	581.3±126.8 ^{ab}	1397.8±254.52 ^a	41.58
	2	1026	281	4	276	-	151			
	3	869	233	15	118	-	94			
	4	731	230	89	43	-	305			
PZQ+ACT	1	731	180	134	37	-	6	809.0±410.9 ^{ab}	1676 ± 498.01 ^a	48.26
	2	972	267	224	175	-	342			
	3	849	45	240	-	-	313			
	4	908	551	247	91	-	468			

201

202

203 **3.5 DISCUSSION**

204 A number of drugs with poorly understood scope of toxicity currently constitute drug options

205 for public health interventions, particularly for parasitic diseases which have a high incidence

206 among developing nations [5][19].As such a necessary step to avert drug-related

207 biochemical disruption, pathological outcomes and mutagenic effects is to adequately

208 examine and profile the toxic potential of drugs commonly used for public health

209 interventions [1][20].

210 The biochemical modulations observed across drug-treatment groups represented in this
211 study presents very interesting findings. The characteristic concurrent increase in albumin
212 and calcium in both single PZQ drug treatment and PZQ+IVM treatment groups strongly
213 highlight dehydration of animals in the both group. Dehydration has been implicated as a
214 common cause of mild or transient hypercalcemia because when there is less fluid in the
215 blood calcium concentrations rise [21]. The possibility of dehydration was also confirmed
216 from the PCA where a negative correlation between PZQ, PZQ+IVM groups and serum
217 phosphate was depicted. The negative correlation suggests hypophosphatemia which could
218 also be diagnostic for dehydration. Also from the PCA, the positive relationship between
219 albumin and Ca in these treatment groups could be explained on the basis that albumin
220 binds calcium, thyroid hormones, fatty acids, and many drugs, keeping them in the blood
221 circulation and preventing them from being filtered out by the kidneys [22]. The importance
222 of albumin in the effectiveness and toxicity of therapeutic drugs and in drug interactions has
223 been documented [22]. Furthermore, the negative correlation of these treatment groups with
224 chloride (Cl⁻) indicates decreased chloride levels in serum of these drug treatment groups.
225 This decrease in serum chloride levels is diagnostic of tendencies towards hypochloremic
226 alkalosis. Since this is an acute drug treatment study, could be described as acute
227 hypochloremic alkalosis.

228 On the other hand, the strong negative correlation between the PZQ+ALB drug treatment
229 group with potassium ion is suggestive of hypokalemic tendencies, while its positive
230 association with sodium ion highlights hyponatremia which is also suggestive of dehydration.
231 The combination of these two conditions highlights possibilities of metabolic alkalosis.
232 Studies have shown that the kidneys compensate for loss of potassium by retaining sodium
233 in the collecting ducts at the expense of hydrogen ions (sparing sodium/potassium pumps to
234 prevent further loss of potassium), leading to metabolic alkalosis [23][24]. The strong positive
235 correlation between the PZQ+ALB treatment group and bicarbonate levels confirms the
236 possibilities of metabolic alkalosis [25]. Although this altered electrolyte levels may can be

237 attributed to the drug treatments, such patterns of electrolyte alterations may imply severe
238 deleterious outcomes to patients with individual physiological risk factors e.g. advanced age,
239 hypertension, gout and hyperuricaemia, diabetes mellitus, chronic renal failure and use of
240 diuretics. Hypercalcaemia observed in single PZQ and combinations with IVM has been
241 reported to enhance nephrotoxic drug injury by inducing pre-renal physiology [11]. Metabolic
242 alkalosis which was also diagnosed in the treatment groups can result in alkaline urine which
243 increases precipitations of drug crystals within the tubular lumen of the kidney [11][26]. In
244 general, it was inferred that the single and combination PZQ treatment groups except
245 PZQ+ACT demonstrated anti-diuretic symptoms and tendencies towards metabolic
246 disruptions.

247 Although focal necrosis and inflammation of portal tract were common features across all
248 PZQ drug combination, the absence of gradient or severity across treatment groups highlight
249 one of the non-specific possibilities of histopathological assessment. Studies have noted that
250 drug-related injury can mimic all the patterns observed in primary liver disease, making
251 unequivocal histological diagnosis difficult or almost impossible in the majority of the case
252 [9]. Findings from this study juxtaposed with relevant literature indicates that the PZQ
253 combination treatment groups were likely to depict incidence of acute hepatitis.
254 Ramachandra and Kakar [9] noted in their review of drug-induced liver disease that one of
255 the hallmarks of acute hepatocellular injury are portal and parenchymal inflammation,
256 hepatocellular injury and/or necrosis. Foci of inflammatory cells have been reported to occur
257 spontaneously in livers of rodents in prechronic studies [27]. Other studies have also
258 confirmed that inflammatory cell aggregates may be accompanied by evidence of
259 hepatocellular necrosis [28][29].

260 The fatty infiltration (steatohepatitis or steatonecrosis) observed in liver tissues from the PZQ
261 treatment demonstrates onset of liver degeneration. Drugs or their metabolites could inhibit
262 esterification of fatty-acid within the hepatocyte resulting in hepatic vesicles engorged with

263 fatty acids [30]. Such drug-related incidences have been reported for alcohol i.e. alcoholic
264 fatty disease [31] tetracycline [32] and Sodium valproate [33].

265 The more distinct pathology observed in kidney tissues across drug-treatment groups. This
266 trend is expected because pharmacokinetic studies of PZQ reveal that in spite of the large
267 absorption that occurs within the gastrointestinal tract (about 80%), only a relatively small
268 amount enters systemic circulation due to extensive first-pass metabolisms. As a result, PZQ
269 and its metabolites are mainly excreted renally within 24 h after a single oral dose, 70 to
270 80% is reportedly found in urine, but less than 0.1% as the unchanged drug [34][35]. This
271 implies that PZQ will have more interaction with the kidney compared to the liver. Reports
272 have shown that the role of the kidney as a primary eliminator of exogenous drugs and
273 toxins makes it vulnerable to develop various forms of injury [20].

274 Furthermore, the realization that PZQ is metabolized through the cytochromeP450 pathway
275 via CYP3A4 also highlights risks for the kidney. This is because CYP450 which constitutes
276 part of the renal enzyme systems favours the formation of toxic metabolites and reactive
277 oxygen species [36][35][37]. The presence of these by-products of metabolism tilts the
278 balance in favour of oxidative stress, which outstrips natural antioxidants and increases renal
279 injury via nucleic acid alkylation or oxidation, protein damage, lipid peroxidation and DNA
280 strand breaks [36][38].

281 The mild mesangial damage in single PZQ drug treatment group compared to the severe
282 mesangial damage in PZQ+IVM and PZQ+ALB treatment groups, suggests that ivermectin
283 and albendazole could enhance renal toxicity. Incidence of proximal cell tubular toxicity is
284 indicative of drug-induced nephrotoxic effects e.g. phospholipid damage, increased
285 intracellular calcium concentrations. Other effects include osmolar effects with loss of normal
286 cell contact and tubular occlusion [37][39].

287 The mutagenicity test as indicated by the occurrence of sperm head abnormality, recorded
288 high incidence of abnormality in all drug treatment groups. The higher incidence of
289 abnormality in PZQ+ IVM and PZQ+ACT were statistically significant ($P < 0.05$). The
290 predominance of pinhead sperms over all other varying types of sperm head abnormality in
291 the treated groups is consistent with reports on PZQ administered to albino mice for a period
292 of 5-8 weeks [40]. The non-significant difference in incidence of sperm head abnormalities
293 between the control group and PZQ treatment group confirms early reports on the non-
294 mutagenic potential of PZQ treatments in humans [41][42]. Considering the non-mutagenic
295 effects of PZQ demonstrated from this study and the non-mutagenic potential of IVM earlier
296 reported [43], mutagenic effects of combination therapies may be attributed to synergistic
297 interaction of the drugs.

298
299

4.0 CONCLUSION

300 Identifying drug-related risks and drug-induced injury is the key to reducing risk of damage to
301 vital organs as liver and kidney. Findings from this study depict that single praziquantel
302 administration and combinations with Ivermectin and albendazole at human therapeutic
303 doses portends risks of liver inflammation, while combination treatments are most likely to
304 induce metabolic disruptions, antidiuretic effects and likelihoods of weight gain due to
305 dehydration. Combination treatments are also likely to induce mutagenic effects as indicated
306 by higher incidence of sperm head abnormalities.

307 Since drug-related risk factors are one of many factors that influence liver and kidney
308 toxicity, more extensive profiling of common drugs options for public health interventions is
309 recommended. This will inform clinical decisions that could increase the risk factors and
310 deleterious outcomes of patients.

311 **COMPETING INTERESTS**

312

313 There is no competing interest among authors.

314

315

316 **CONSENT**

317

318 Not applicable.

319

320 **REFERENCES**

321

322 1. Perazella, MA. Renal vulnerability to drug toxicity. *Clinical Journal of the American*
323 *Society of Nephrology*, 2009. 4, 1275-1283.

324

325 2. Allarakhia, M. Open-source approaches for the repurposing of existing or failed
326 candidate drugs: learning from and applying the lessons across diseases. *Drug*
327 *Des.Dev. Ther*, 2013. 7,753-66.

328

329 3. Hotez, PJ., Molyneux, DH., Fenwick, A., Kumaresan, J., Sachs, SE., Sachs, JD.,
330 Savioli. Control of neglected tropical diseases *New England Journal of medicine*,
331 2007. 357, 1018-1027.

332

333 4. Hotez, PJ., Brindley, PJ., Bethony, JM., Kong CH., Pearce, EJ., Jacobson, J.
334 Helminth infections: the great neglected tropical disease. *The Journal of clinical*
335 *investigation*, 2008. 118, 1311-1321.

336

337 5. WHO. Global report on antimalarial drug efficacy and drug resistance: 2010. 2000-
338 2010.

339

340 6. Garcia, HH. Antiparasitic drugs in neurocysticercosis: albendazole or praziquantel?
341 *Expert review of anti-infective therapy*, 2008. 6, 295-298.

342

343 7. Andrew, KT., Fisher, G., Skinner-Adams, TS. Drug repurposing and human parasitic
344 protozoan diseases. *International Journal for parasitology: Drugs and Drug*
345 *Resistance*, 2014. 4, 95-111.

346 8. Lameire, NH., Flombaum, CD., Moreau, D., Ronco, C. Acute renal failure in cancer
347 patients. *Annals of medicine*, 2005. 37, 13-25.

348

349 9. Ramachandran, R., Kakar, S. Histological patterns in drug-induced liver disease.
350 *Journal of Clinical Pathology*, 2009. 62, 481-492.

351

352 10. Decloedt, E., Maartens G. Drug-induced renal injury: main article. *CME: Your SA*
353 *Journal of CPD: Pharmacology*, 2011. 29, 252-255.

354 11. Markowitz, GS., Perazella, MA. Drug-induced renal failure: a focus on
355 tubulointerstitial disease. *Clinica chimica acta*, 2005. 351, 31-47.

356

- 357 12. Vickers, AE., Fisher, RL. Organ slices for the evaluation of human drug toxicity.
358 *Chemico-biological interactions*, 2004. 150, 87-96.
359
- 360 13. Ismail, S. Botros, A. Metwally, S. William, A. Farghally, L. Tao, T.A. Day, J.L. Bennett
361 Resistance to praziquantel: direct evidence from *Schistosoma mansoni* isolated from
362 Egyptian villagers *Am. Soc. Trop. Med. Hyg.*, 1999. 60 pp. 932-935
363
- 364 14. Arise, R., Malomo, S. Effects of ivermectin and albendazole on some liver and
365 kidney function indices in rats. *African Journal of Biochemistry Research*, 2009. 3,
366 190-197.
- 367 15. Bitto II, Gemade M, *Afri. J. Biomed. Res*, **2001**, 9:199-209.
368
369
- 370 16. Dumas BT., Watson WA., Biggs HG. Albumin standards and measurement of
371 serum-albumin with bromocresol green. *Clin. Chim. Acta.* 31: 87- 92.
- 372 17. Young, RR., Asbury AK., Corbett JL., Adams RD. Pure pandyautonomia with
373 recovery: description and discussion of diagnostic criteria. *Brain.* 1975: 98:613-36.
374
- 375 18. Wyrobek, A. and Bruce, W. Chemical Induction of Sperm Abnormalities in Mice.
376 *Proceedings of the National Academy of Sciences of the United States of America.*
377 1975,72,4425-4429.
378
- 379 19. Loh, AH., Cohen, AH. Drug-induced kidney disease-pathology and current
380 concepts. *Ann Acad Med Singapore*, 2009. 38, 240-250.
381
- 382 20. Perazella, MA. Drug-induced nephropathy: an update. *Expert opinion on drug*
383 *safety*, 2005. 4, 689-706.
384
- 385 21. Yamasaki, K., Chuang, VTG., Maruyama, T. Otagiri, M. Albumin–drug interaction
386 and its clinical implication. *Biochimica et Biophysica Acta (BBA)-General*
387 *Subjects*, 2013. 1830, 5435-5443.
388
- 389 22. Galla, JH. IgA nephropathy. *Kidney international*, 1995. 377-387.
- 390 23. Sahay, M., Sahay, R. Hyponatremia: a practical approach. *Indian journal of*
391 *endocrinology and metabolism*, 2014. 18, 760.
392
- 393 24. Hennessey, IA., Jappa, AG. Arterial blood gases made easy, Elsevier health
394 Sciences, 2007
- 395 25. Stratta, P., Lazzarich, E., Canavese, C., Bozzola, C., Monga, G. Ciprofloxacin
396 crystal nephropathy. *American Journal of Kidney Diseases*, 2007. 50, 330-335.
397
- 398 26. Liedke, C., Luedde, T., Sauerbruch, T., Scholten, D., Streetz, K., Tacke, F., Tolba,
399 R., Trautwein, C., Trebicka, J. Weiskirchen, R. Experimental liver fibrosis research:
400 update on animal models, legal issues and translational aspects. *Fibrogenesis &*
401 *tissue repair*, 2013. 6, 1.

- 402
403 27. Harada, Y., Hatanaka, K., Kawamura, M., Saito, M., Ogino, M., Majima, M., Ohno,
404 T., Ogino, K., Yamamoto, K., Taketani, Y. Role of prostaglandinH synthase-2 in
405 prostaglandin E 2 formation in rat carrageenin-induced pleurisy. *Prostaglandins*,
406 1996. 51, 19-33.
- 407 28. Murray, KF., Hadzic, N., Wirth, S., Bassett, M., Kelly, D. Drug-related hepatotoxicity
408 and acute liver failure. *Journal of pediatric gastroenterology and nutrition*, 2008. 47,
409 395-405.
- 410 29. Kirchain and Allen, 2014
- 411
412 30. Leo, MA., Lieber, CS. Alcohol, Vitamin A, and β -carotene: adverse interactions,
413 including hepatotoxicity and carcinogenicity. *The American journal of clinical nutrition*
414 1999. 69, 1071-1085.
- 415
416 31. Lee, WM. Acute liver failure. *New England journal of medicine*, 1993. 329, 1862-
417 1872.
- 418
419 32. Konig, S., Schenk, M., Sick C., Holm, E., Heubner, C., Weiss, A., Konig, I.,
420 Hehlmann, R. Fatal liver failure associated with valproate therapy in a patient with
421 Friedreich's disease: review of Valproate Hepatotoxicity in adults. *Epilepsia*, 1999.
422 40, 1036-1040.
- 423
424 33. Ali, MH., Abramson FP., Fetterolf, DD., Cohn, VH. Metabolism studies of the
425 antischistosomal drug praziquantel using tandem mass spectrometry: Distribution of
426 parent drug and ten metabolites obtained from control and schistosome-infected
427 mouse urine. *Biological Mass spectrometry*, 1990. 19, 186-190.
- 428
429 34. Meister, I., Kovac, J., Duthaler, U., Odermatt, P., Huwyler, J., Vanobberghen, F.,
430 Sayasone, S., Keiser, J. Pharmacokinetic study of praziquantel enantiomers and its
431 main metabolite R-trans-4-OH-PZQ in plasma, blood and dried blood spots in
432 *Opisthorchis viverrini*-infected patients. *PLoS neglected tropical diseases*, 2016. 10,
433 e0004700.
- 434
435 35. Aleska, K., Matsell, D., Krausz, K., Gelboin, H., ITO, S., Koren, G. Cytochrome P450
436 3A and 2B6 in the developing kidney: implications for ifosfamide nephrotoxicity.
437 *Paediatric Nephrology*, 2005. 20, 872-885.
- 438
439 36. Cummings, BS., Schnellmann, RG. Pathophysiology of nephrotoxic cell injury.
440 *Diseases of the kidney and urinary tract. Philadelphia Lippincott Williams & Wilkins*,
441 2001. 1071-1091.
- 442
443 37. Kaloyanides, G., Bismans, J., Debroe, M. Antibiotic and immunosuppression-related
444 renal failure. *Disease of the kidney and Urogenital Tract*, edited by Schrier RW,
445 Philadelphia PA, Lippincott Williams & Wilkinson, 2001. 1137-1174.
- 446 38. Lucena, MI., Andrade, RJ., Cabello, MR., Hidalgo, R., Gonzalez-Correa, JA., De La
447 Cuesta, FS. Aminoglycoside-associated nephrotoxicity in extrahepatic obstructive
448 jaundice. *Journal of hepatology*, 1995. 22, 189-196.
- 449

- 450 39. Aduloju, R Otubajo, O., Odeigah P. An in vivo assay of the mutagenic potential of
451 praziquantel (PZQ) using sperm head abnormality test. *J Hum Ecol*, 2008. 23, 59-
452 63.
453
- 454 40. Froberg, GH. Result of toxicological studies on praziquantel. *Arzneimittel-*
455 *Forschung*, 1984. 34, 1137-1144.
- 456 41. WHO. Report of the WHO informal consultation on the use of praziquantel during
457 pregnanc. 2003.
458
- 459 42. Otubanjo, O., Mosuro, A. An in vivo evaluation of induction of abnormal sperm
460 morphology by some anthelmintic drugs in mice. *Mutation Research/Genetic*
461 *Toxicology and Environmental Mutagenesis*, 2001. 497, 131-138.

UNDER PEER REVIEW