

## Original Research Article

# Influence of Ethanolic Extracts of *Spondias Mombin* (*Anacardiaceae*) Leaves on Pituitary- Gonadal Axis of Male Wistar Rats

### ABSTRACT

**Background:** *Spondias mombin* is one of the tropical plants used locally to treat various kinds of ailment, its use as an anti-conceptive remedy in our locality had been reported.

**Objective:** The aim of this study was to establish a dose-dependent or duration effect of ethanolic leaf extract of *Spondias mombin* on the anterior pituitary cells, testes and epididymides of Wistar rats of Wistar rats.

**Materials and methods:** A total of thirty (30) matured male Wistar rats were randomly divided into five groups (n=5). Group 1 animals served as control and received vehicle (distilled water). Groups 2 and 3 were administered with 250mgkg<sup>-1</sup> body weight of extract for 4 and 6 weeks respectively, while groups 4 and 5 received 500mgkg<sup>-1</sup> body weight of extract for 4 and 6 weeks also. Animals were anaesthetized with chloroform and sacrificed at the end of administration. **Body weight, weights of reproductive organs and vital organs were evaluated.** Blood was taken from the animals for haematological and biochemical analysis. The pituitary gland, male reproductive and accessory glands were excised and fixed in 10% formalin for routine histological examination.

**Results:** The influence of ethanolic extract of *Spondias mombin* leaves on the pituitary cells and reproductive organs of male Wistar rats given 250 and 500mgkg<sup>-1</sup> body weight for 4 and 6 weeks showed loss of cytoplasmic contents and free spaces of pituitary cells, desquamation of seminiferous epithelial cells, degradation of seminiferous tubules and reduction in cells. The epididymis of the test groups showed abundant immature cells and cell debris in their lumen. The accessory glands showed homogenous pinkish fluid, glandular degeneration of the prostate and seminal vesicles with decreased structural integrity. The organ weights of the experimental animals were not significantly affected,

however, a significant ( $P < 0.05$ ) decrease in reproductive organ weights was recorded. Ethanolic extract of *Spondias mombin* on liver enzymes showed a significant protection against hepatobiliary damage.

**Conclusion:** These results suggest that *Spondias mombin* has a dose dependent and duration deleterious effect on the pituitary and reproductive organs at their cellular levels rather than on the tissue as a whole.

**Keywords:** Accessory glands, Cells, Degradation, Epithelium, Pituitary, Reproduction

## 1. INTRODUCTION

Medicinal plants still play major roles in health worldwide irrespective of the advances recorded in orthodox medicine. Interest in drugs derived from higher plants has increased considerably in the past few years with about 20-25% of modern drugs being derived from plants [1-2]. An expression in the biodiversity in number had been carried out with an estimate of 10-100 million species, out of which 2.5-7.5 million to be attributed to plants [3]; 5-105 of these plants have been scientifically evaluated for their therapeutic medicinal properties [4]. Plants have been used and are still in use in most developing countries as their main source of health care [5-6]. These plants are assumed to be safe and free from side effects since they are naturally occurring [7-8]. However, studies have shown that medicinal plants may be toxic [9-12]. These adverse effects are however less frequent when used properly in comparison to synthetic medicines [13]. A lot of these herbal plants used to treat or cure diseases locally have been found to be anticancer [14-16], anti-malarial [17-18], anti-diabetic [19-20], antihypertensive [21-22], antibacterial [23], antimicrobial [24-25], antifertility [26-27], abortifacient [28-30] etc. These claims were first made by rural users which have been authenticated by biological research. *Spondias mombin* (SpM) is one of such plants used locally to treat various kinds of ailment which biological research has supported [31-37]. We had earlier reported on scientific findings on *Spondias mombin* [38-40]. The present study was carried out to further investigate the effect of *Spondias mombin* on pituitary cells and reproductive organs of male Wistar rats based on duration of administration.

35 **2. MATERIAL AND METHODS**

36  
37 The harvesting and extraction of plant material had earlier been reported in our previous work [40]. A total of  
38 thirty (30) mature male Wistar rats (6 weeks old) were randomly divided into five groups (n=5). Rats were kept  
39 in temperature controlled room of  $25 \pm 2^\circ\text{C}$  with a 12-hour light/dark cycle under hygienic conditions and had  
40 free access to water & rat chow. The animals were acclimatized for seven days before experimental use.  
41 Ethics on the use of laboratory animals was applied and care of the animals was in accordance to the  
42 International guidelines for animal research. The methodology was approved by the Department of Human  
43 Anatomy ethical committee. Group 1 animals served as control and received vehicle (distilled water). Groups  
44 2 and 3 were administered  $250\text{mgkg}^{-1}$  body weight of extract for 4 and 6 weeks respectively, while groups 4  
45 and 5 received  $500\text{mgkg}^{-1}$  body weight of extract for 4 and 6 weeks also. The administration of extract was  
46 through oral route with the aid of an orogastric tube. Animals were anaesthetized with chloroform and  
47 sacrificed at the end of administration. Body weight, weights of reproductive organs and vital organs were  
48 evaluated. Blood was taken from the animals for haematological and biochemical analysis. The pituitary gland,  
49 male reproductive and accessory glands were excised and fixed in 10% formalin and later processed for  
50 histological examination. The pituitary gland was double stained using the bromine alcian blue-orange fuchsin  
51 green (Br.AB-OFG) method of Slidders [41] to demonstrate anterior pituitary cells. Data were expressed as  
52 Mean  $\pm$  S.E.M. Statistical analysis was carried out by one-way analysis of variance (ANOVA) with significance  
53 expressed as  $P < 0.05$ .

54 **3. RESULTS AND DISCUSSION**

55  
56  
57 The mean vital organs weight was not affected by the administration of leaf extract of SpM for 4 and 6  
58 weeks (Table 1). However, the reproductive organ weights were significantly ( $P < 0.05$ ) reduced at 6 weeks in  
59 animals administered with 250 and 500  $\text{mgkg}^{-1}$ , irrespective of a non- significant change in body weights  
60 across the five groups (Table 2). The identification of the possible harmful effects of chemical and drugs is the  
61 analysis of organ weight [42]. In this study, the organ weights and body weights of the experimental groups  
62 were not different from that of the control which points to earlier findings of the safety use of SpM extracts [43].  
63 However, reproductive organ weights were affected by extract of SpM which is indicative of the shrunken

64 characteristics observed on histopathological examination of the tissues. The red blood cell counts were  
65 increased significantly ( $P<0.05$ ) in groups 3 and 5 which received 250 and 500 mgkg<sup>-1</sup> for 6 weeks. Similarly,  
66 values for haemoglobin also significantly increased ( $P<0.05$ ) in these groups. Values of ALP reduced in  
67 groups 3 and 5 (Table 3). Enzymes have been reported to be found in tissues and blood as a result of insult to  
68 the cell or from degraded cells [44]. Activities of liver enzymes are determined in serum as indicators of  
69 biochemical changes which occur in response to treatment [45]. It had been stated that aminotransferases  
70 (ALT and AST) are indicators of hepatotoxicity and hepatocellular damage, while ALP is used in diagnosing  
71 hepatobiliary or cholestatic obstruction [46]. ALP is cardinaly involved in the transport of metabolites across  
72 cell membranes, synthesis of proteins, secretory activities and glycogen metabolism [47]. The significant  
73 ( $P<0.05$ ) decrease observed in ALP activity may imply protection against hepatobiliary damage, since most  
74 enzymes measured as indices of drug metabolism are released into bloodstream when cells are damaged or  
75 their functions are disrupted. Total protein (TP) levels did not show any significance although it increased  
76 amongst the experimental groups and control. Albumin (ALB) levels however significantly increased in the  
77 groups treated for 6 weeks as also recorded with creatinine (CRT) and urea. Proteins are important parts of all  
78 cells and tissues. Total protein test is carried out to diagnose nutritional problems and liver disease. In the  
79 experimental animals, a non-significant increase in total protein levels were observed, however, albumin was  
80 significantly increased at 6 weeks in both dosages in groups administered with 500mgkg<sup>-1</sup> of extract. The  
81 increased protein albumin levels recorded in this study indicate a possible impairment in the normal function of  
82 the liver as established by Ahmad *et al* [48] that a change in the concentration of serum protein and albumin  
83 indicate a change in normal liver function. Creatinine and urea tests are carried out to evaluate the function of  
84 the kidney. In this study, creatinine and urea levels were significantly increased in groups treated for 6 weeks.  
85 Creatinine is the major kidney function parameter and its observed high level might be as a result in the  
86 decrease of synthesis or increase functional capacity of tubular excretion [49].

87 Pituitary cells of control animals were well stained, normal and numerous on histological examination,  
88 whereas cells of experimental animals were sparse with loss of cytoplasmic contents. The effect was more in  
89 groups treated for 6 weeks recording greater loss of cytoplasmic contents and free spaces (Figure 1a-e). The  
90 testes on histopathological examination showed seminiferous tubules of control possessing epithelia with well-

91 defined Sertoli cells and germ cells at various stages of spermatogenesis. Sertoli cells showed distinct granular  
 92 cytoplasm and irregular nuclei. Lumen of seminiferous tubules contained mature sperm and numerous Leydig  
 93 cells in the interstitium (Figure 2a). Groups 2-5 animals showed dose and time duration dependent alteration  
 94 on the testes evidenced by distortion of tubular cells, prominent spaces and severe structural disorganization  
 95 (Figure 2b-e).

96 Epididymis of experimental groups showed thinness of epididymal epithelial lining compared to control  
 97 with their lumen showing cell debris, large number of immature cells and degenerated (Figure 3a-e). The  
 98 lumen of the prostate of experimental animals showed pinkish fluid and inflammatory cells (Figure 4a-e). The  
 99 presence of debris in the lumen of the epididymis may be a reflection of degenerated testicular assault  
 100 observed in the treated rats. This lesion may probably have been passed to the epididymis. Thus, it is safe to  
 101 deduce that extract of SpM has defective effect on the germ cells. The observed effect of the extract on the  
 102 accessory sex gland may also be as a result of its destructive tendency on testicular tissue that led to a  
 103 decrease testosterone production [48]; since decrease in testosterone production has been observed to have  
 104 negating effect on accessory sex glands [50]. Therefore, it is safe to state that the low testosterone reported in  
 105 our earlier work [51] may be responsible for the effect of the extract on the accessory sex glands since male  
 106 accessory sex glands are known to depend on male sex hormone for development and secretory activity [52].

107

108 Table 1: Weight of vital organs of control and experimental SpM extract treated rats.  
 109

Parameters (g)	Groups				
	1	2	3	4	5
Brain	1.85±0.25	1.82±0.05	1.77±0.14	1.73±0.23	1.72±0.28
Heart	0.82±0.05	0.76±0.02	0.72±0.03	0.70±0.06	0.68±0.24
Lungs	1.56±0.30	1.54±0.35	1.48±0.20	1.49±0.30	1.46±0.28
Thyroid	0.060±0.002	0.060±0.002	0.050±0.002	0.048±0.006	0.046±0.006
Kidney	1.80±0.28	1.78±0.22	1.72±0.29	1.70±0.20	1.70±0.24
Liver	8.26±0.80	8.00±0.78	7.95±0.80	7.64±0.75	7.62±0.82
Adrenal	0.180±0.002	0.178±0.002	0.178±0.002	0.176±0.002	0.173±0.002
Spleen	0.62±0.20	0.60±0.27	0.60±0.18	0.58±0.22	0.55±0.21

110 Values are Mean ± SEM, n=5. Extract had no significant effect on the weights of vital organs.

111

112

113

114

115

Table 2: Body and reproductive organ weights in control and treated rats.

Parameters	Groups
------------	--------

(g)	1	2	3	4	5
<b>Body weight</b>	210±2.42	208.7±3.42	214.0±2.07	204.5±3.57	210.0±1.82
<b>Testis</b>	3.20±0.75	2.75±0.43	1.43±0.36*	2.44±0.23*	1.26±0.15*
<b>Epididymis</b>	2.75±1.36	2.55±1.80	1.89±0.82*	2.24±1.08*	1.54±0.62*
<b>Seminal vesicle</b>	3.75±1.10	2.92±0.34	1.83±0.33*	1.72±0.64*	1.46±0.73*
<b>Prostate</b>	1.92±0.79	1.63±0.64	1.42±0.64*	1.26±0.48*	1.08±0.84*

Values are Mean ± SEM, n=5. \*P<0.05 compared to control. Extract showed a significant effect on the weights of reproductive organs compared to body weights of animals where no significant effect was recorded.

116  
117  
118  
119  
120  
121  
122  
123  
124  
125  
126  
127  
128  
129  
130  
131  
132  
133  
134  
135  
136

Table 3: Haematological and biochemical parameters of control and SpM extract treated rats.

Values are Mean ± SEM, n=5. P<0.05

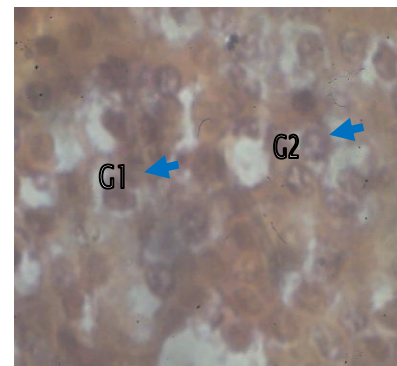
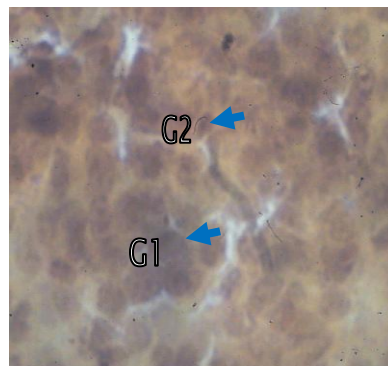
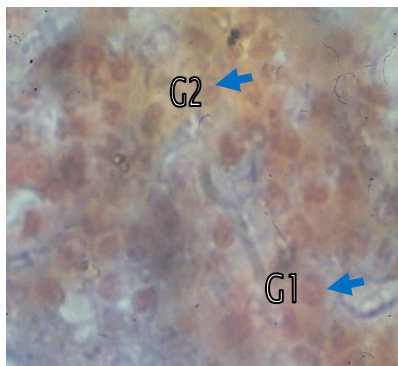
RBC: Red blood cell WBC: White blood cell HB: Hemoglobin PCV: Packed cell volume

ALP: Alkaline phosphatase AST: Aspartate aminotransferase ALT: Alanine aminotransferase

TP: Total protein ALB: Albumin CRT: Creatinine

Parameters	Groups				
	1	2	3	4	5
<b>RBC (10<sup>4</sup>/μL)</b>	7.44±0.38	7.93±0.22	8.82±0.12*	8.72±0.10*	8.85±0.23*
<b>WBC (10<sup>3</sup>/μL)</b>	19.58±3.50	18.78±1.40	16.64±2.10	19.32±1.96	18.42±2.46
<b>HB (g/dL)</b>	11.68±0.59	12.20±0.27	15.42±0.21*	13.28±0.26*	18.38±1.05*
<b>PCV (%)</b>	45.78±2.64	49.74±1.78	47.16±0.62	54.30±1.45*	47.58±0.94
<b>ALP (μL)</b>	27.05±1.77	17.70±0.36*	0.66±0.03*	12.96±1.06*	0.19±0.07*
<b>AST (μL)</b>	373.42±47.45	294.88±17.07*	447.01±8.05*	218.41±50.03*	442.67±14.75*
<b>ALT (μL)</b>	170.76±9.66	154.15±6.31	171.56±6.95	151.78±4.17*	171.62±2.14
<b>TP(mg/L)</b>	0.51±0.13	0.40±0.06	0.64±0.08	0.27±0.03	0.59±0.13
<b>ALB (mg/L)</b>	5.31±0.74	3.90±1.58	1.79±0.34*	2.73±0.93*	1.58±0.48*
<b>CRT (μmol/l)</b>	2.06±0.28	2.92±0.59	2.77±0.79*	2.74±0.64	3.95±0.73*
<b>UREA (mg/L)</b>	32.08±0.93	29.72±1.42	16.03±0.71*	34.86±1.87	14.50±3.83*

137  
138  
139  
140  
141  
142  
143  
144  
145  
146  
147  
148



149  
150  
151  
152  
153  
154  
155  
156  
157  
158  
159  
160  
161  
162  
163  
164  
165  
166  
167  
168  
169  
170  
171  
172  
173  
174  
175  
176  
177  
178  
179  
180  
181  
182  
183  
184  
185  
186  
187  
188  
189  
190  
191  
192  
193  
194  
195  
196

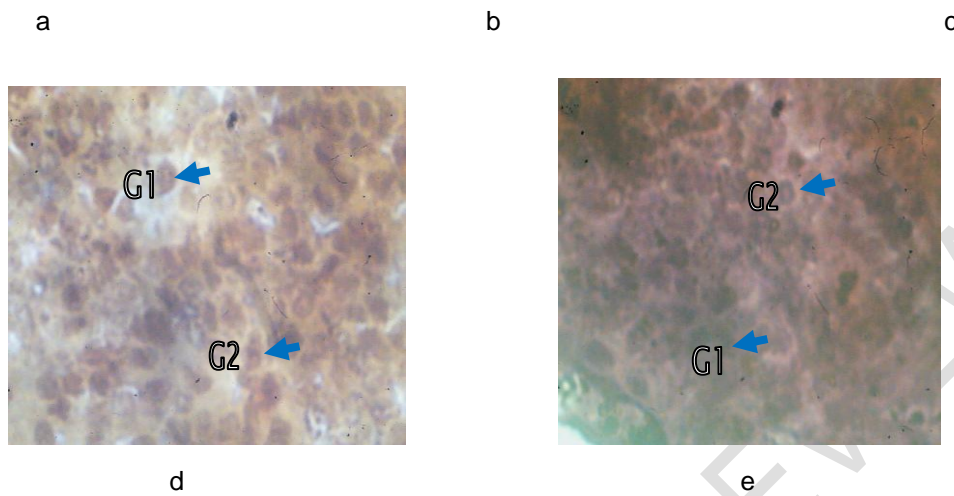
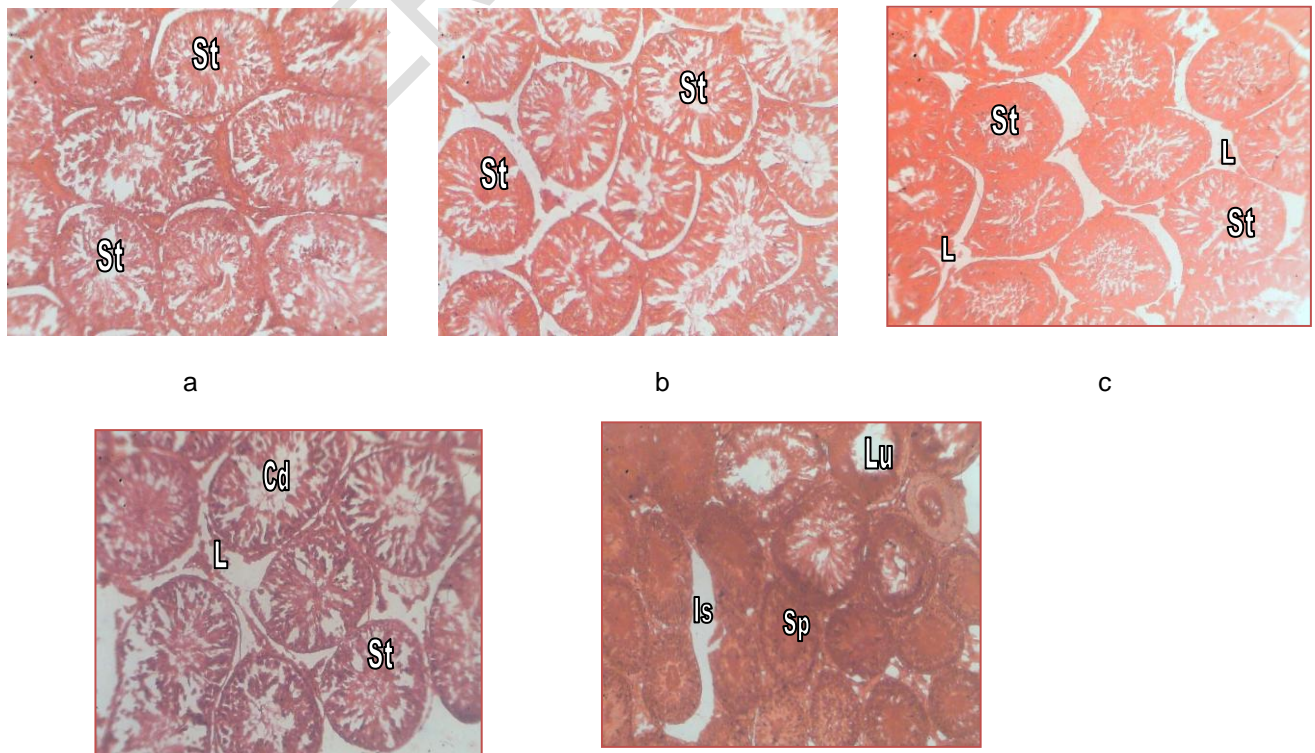


Fig 1: Photomicrographs of anterior pituitary of control and experimental animals treated with 250mgkg<sup>-1</sup> and 500mgkg<sup>-1</sup> ethanolic extract for 4 and 6 weeks (Br. AB/OFG X 400).

- a. Anterior pituitary of control showing normal gonadotrophs FSH (G<sub>1</sub>) and LH (G<sub>2</sub>) respectively.
- b. Anterior pituitary of 250mg/kg ethanol extract treated for 4 weeks showing hypertrophied gonadotrophs FSH (G<sub>1</sub>) and LH (G<sub>2</sub>).
- c. Anterior pituitary of 250mg/kg ethanol extract treated for 6 weeks showing regressed gonadotrophs FSH (G<sub>1</sub>) and LH (G<sub>2</sub>).
- d. Anterior pituitary of 500mg/kg ethanol extract treated for 4 weeks showing hypertrophied gonadotrophs FSH (G<sub>1</sub>) and LH (G<sub>2</sub>).
- e. Anterior pituitary of 500mg/kg ethanol extract treated for 6 weeks showing regressed gonadotrophs FSH (G<sub>1</sub>) and LH (G<sub>2</sub>) with loss of cytoplasmic contents.



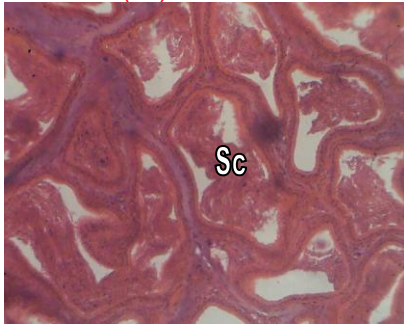
197  
198  
199  
200  
201  
202  
203  
204  
205  
206  
207  
208  
209  
210  
211  
212  
213  
214  
215  
216  
217  
218  
219  
220  
221  
222  
223  
224  
225  
226  
227  
228  
229  
230  
231  
232  
233  
234  
235  
236  
237  
238  
239  
240  
241  
242  
243  
244  
245  
246  
247  
248  
249

d

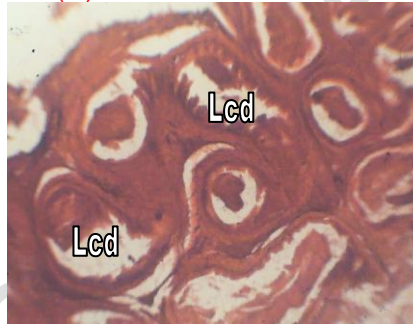
e

Fig 2: Photomicrographs of testis of control and experimental animals treated with 250mgkg<sup>-1</sup> and 500mgkg<sup>-1</sup> ethanolic extract for 4 and 6 weeks (H & E X 400).

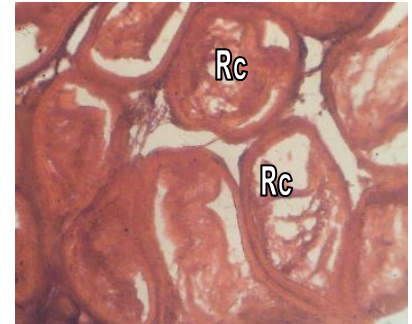
- a. Testis of control animal showing well arranged seminiferous tubules (St) and normal process of spermatogenesis.
- b. Testis of 250mg/kg ethanol extract treated for 4 weeks showing loosely arranged seminiferous tubules (St).
- c. Testis of 250mg/kg ethanol extract treated for 6 weeks showing shrunken seminiferous tubules (St) and loss of Leydig cells (L).
- d. Testis of 500mg/kg ethanol extract treated for 4 weeks showing distorted seminiferous tubules (St), loss of Leydig cells (L) and cell debris (Cd).
- e. Testis of 500mg/kg ethanol extract treated for 6 weeks showing arrest of spermatogenesis (Sp), empty lumen (Lu) and loss of interstitial tissue (Is).



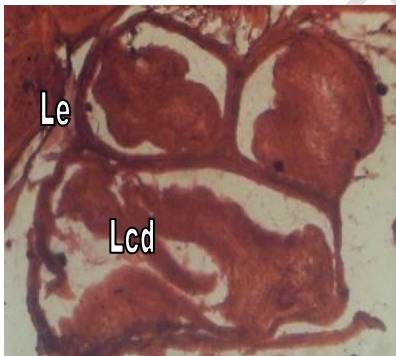
a



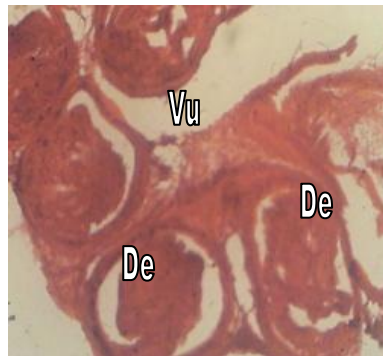
b



c



d



e

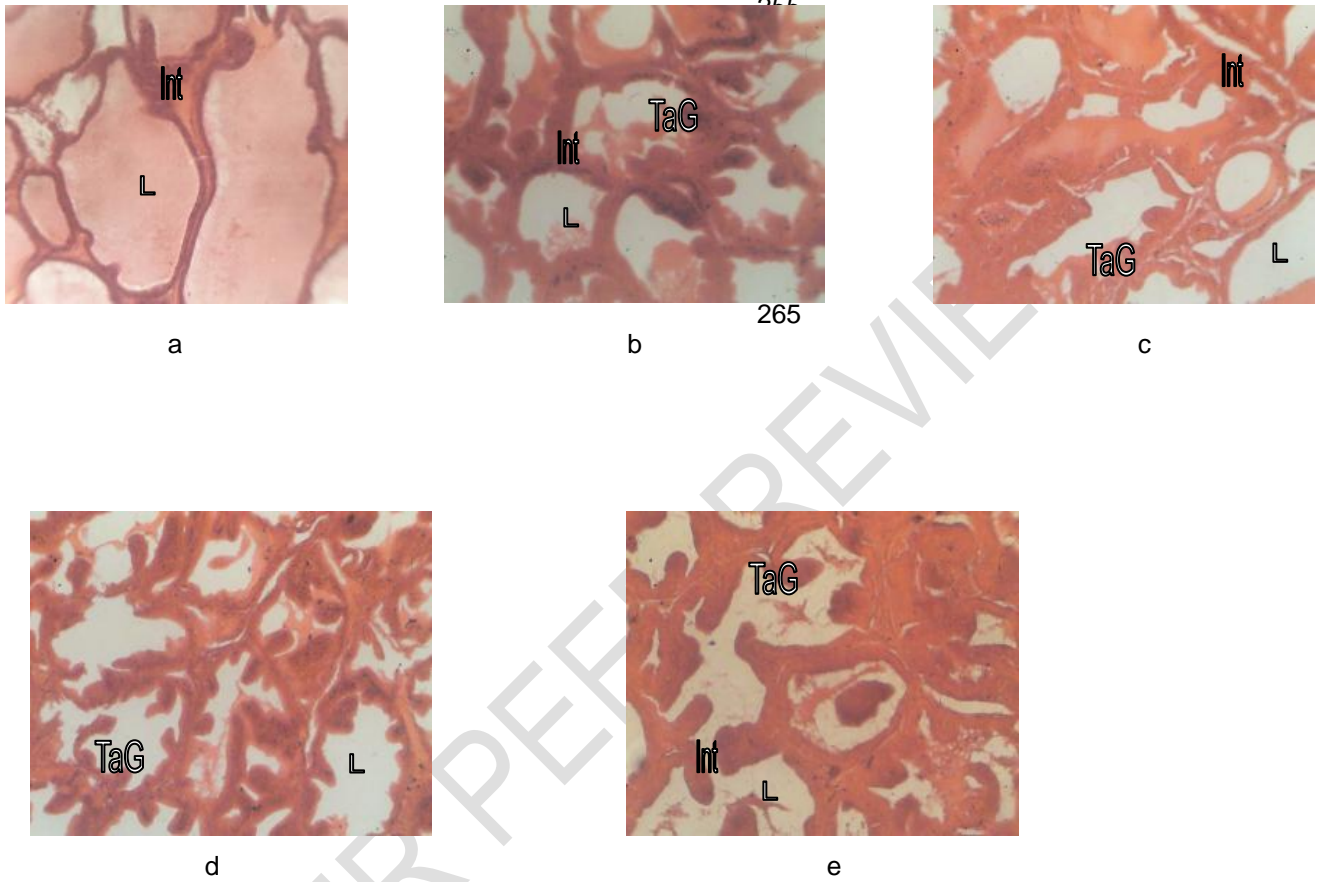
Fig 3: Photomicrographs of epididymis of control and experimental animals treated with 250mgkg<sup>-1</sup> and 500mgkg<sup>-1</sup> ethanolic extract for 4 and 6 weeks (H & E X 400).

- a. Epididymis of control animal showing tubules filled with sperm cells (Sc).
- b. Epididymis of 250mg/kg ethanol extract treated for 4 weeks showing lumen containing cell debris (Lcd).
- c. Epididymis of 250mg/kg ethanol extract treated for 6 weeks showing regressive changes (Rc).
- d. Epididymis of 500mg/kg ethanol extract treated for 4 weeks showing loss epithelium (Le) and cell debris (Lcd) in lumen.



250  
251  
252  
253  
254

- e. Epididymis of 500mg/kg ethanol extract treated for 6 weeks showing distortion of epididymal tissue (De) and presence of vacuoles (Vu).



266  
267  
268  
269  
270  
271  
272  
273  
274  
275  
276  
277  
278  
279  
280  
281  
282  
283  
284  
285  
286  
287  
288  
289  
290  
291  
292  
293  
294  
295  
296  
297  
298

Fig 4: Photomicrographs of prostate gland of control and experimental animals treated with 250mgkg<sup>-1</sup> and 500mgkg<sup>-1</sup> ethanolic extract for 4 and 6 weeks (H & E X 400).  
a. Prostate of control animal showing normal architecture with well defined interstitial tissue (Int) and lumen (L) filled with prostatic secretions.  
b. Prostate of 250mg/kg ethanol extract treated for 4 weeks showing lumen (L) with less secretions, thinned out interstitial tissue (Int) and tubuloalveolar glands (TaG) .  
c. Prostate of 250mg/kg ethanol extract treated for 6 weeks showing regressive changes in cytoarchitecture.  
d. Prostate of 500mg/kg ethanol extract treated for 4 weeks showing changes in the shape of glands (TaG), wider and empty lumen (L).  
e. Prostate of 500mg/kg ethanol extract treated for 6 weeks showing distortions of gland (TaG), lumen (L) and interstitial tissue (Int).

299 **4. CONCLUSION**

300  
301  
302  
303  
304  
305  
306

This study concludes that the effect of extract of SpM is dose and duration dependent with its effect localized to the pituitary and male reproductive system which supports its use locally to stall conception in male. The mechanism through which this is mediated is not known. Further research will be based on the mechanism through which SpM mediate this action.

307 **COMPETING INTERESTS**

308  
309  
310  
311

Authors have declared that no competing interests exist.

312 **ETHICAL APPROVAL**

313  
314

Approval was given by the Faculty of Basic Medical Sciences Committee on animal use and care, University of Calabar to carry out this research work following laid down rules and guidelines of the institution in the use of medicinal plants and animal models.

317 **REFERENCES**

318  
319  
320  
321  
322  
323  
324  
325  
326  
327  
328  
329  
330  
331  
332  
333  
334  
335  
336  
337

1. Veeresham C. Natural products derived from plants as a source of drugs. *J Adv Pharm Technol Res* 2012; **3**(4): 200-207.
2. Newman DJ, Cragg GM, Snader KM. The influence of natural products upon drug discovery. *Nat Prod Reports* 2000; **17**: 215-234.
3. Pimm SL, Russell GJ, Gittleman JL, Brooks TM. The future of biodiversity. *Science* 1995; **5** 347-350.
4. Verpoorte R. Exploration of nature's chemodiversity: the role of secondary metabolites as lead drugs for drug development. *Drug Dev Today* 1998; **3**: 232-238.
5. Kumar S, Kumar R, Khan A. Medicinal plant resources: manifestation and prospects of life-sustaining healthcare system. *Cont J Biol Sci* 2001; **4** (1): 19-29.
6. Sathiyaraj K, Sivaraj A, Thirumalai T, SenthilKumar, B. Ethnobotanical study of antifertility medicinal plants used by the local people in Kathiyavadi village, Vellore District, Tamilnadu, India. *Asian Pac J Trop Biomed* 2012; S1285-S1288.
7. Haq I Safety of medicinal plants. *Pak J Med Res* 2004; **43** (4): 203-210.
8. Nasri H, Shirzad H. Toxicity and safety of medicinal plants. *J Herb Med Pharmacol* 2013; **2**(2): 21-22.
9. Cupp MJ. Toxicology and chemical pharmacology of herbal products. Totowa, NJ: Humaila Press. 2000
10. Boullata JI, Nace AM. Safety issues with herbal medicine. *Pharmacotherapy* 2000; **20** (3): 257-269.
11. Posadzki P, Watson LK, Ernst E. Adverse effect of herbal medicines: an overview of systematic review. *Clin Med* 2013; **13** (1): 7-12.

- 338 12. Hussin AHJ. Adverse effects of herbs and drug-herbal interactions. *Malaysian J Pharm* 2001; **1**(2):  
339 39-44.
- 340 13. Calixto JB. Efficacy, safety, quality control marketing and regulatory guidelines for herbal medicines  
341 (phytotherapeutic agents). *Brazilian J Med Biol Res* 2000; **33**: 179-189.
- 342 14. Cragg GM, Newman DJ. Plants as a source of anti-cancer agents. *J Ethnopharm* 2005; **100**(1-2): 72-  
343 79.
- 344 15. Soladoye MO, Amusa VA, RAji-Esan SO, Chukuma EC, Ayanbamiji AT. Ethnobotanical survey of anti-  
345 cancer plants in Ogun State, Nigeria. *Annals Biol Res* 2010; **1**(4): 261-273.
- 346 16. Mohan S, Bustamam A, Ibrahim S, Al-Zubain AS, Aspollah M. Anti-cancerous effect of *Tryphonium*  
347 *flagelliforme* on human T4-lymphoblastoid cell line CEM-SS. *J Pharm Toxicol* 2008; **3**(6): 449-456.
- 348 17. Adebayo JO, Krettlu AO. Potential anti-malarials from Nigerian plants: A review. *J Ethnopharmacol*  
349 2011; **133**: 289-302.
- 350 18. Okpako LC, Ajsiyabo EO. In vitro and in vivo anti-malarial activities of *Striga hermonthiaca* and  
351 *Tapinanthus sessifolius* extracts. *Afr J Med Sci* 2004; **1**: 73-75.
- 352 19. Ezekwesili CN, Ogbunugafor HA, Ezekwesili-Ofili JO. Anti-diabetic activity of aqueous extracts of *Vites*  
353 *doniana* leaves and *Cinchona calisaya* bark in alloxan induced diabetic rats. *Int J Trop Dis Health*  
354 2012; **2**(4): 290-300.
- 355 20. Chauhan A, Sharma PK, Srivastava P, Kumar N, Dudhe R. Plants having potential anti-diabetic  
356 activity: A review. *Der Pharmacie Lettre* 2010; **2**(3): 369-387.
- 357 21. Patel SS, Verma NK, Ravi V, GAuthaman K, Soni N. Anti-hypertensive effect of an aqueous extract of  
358 *Passiflora nepalensis* wall. *Int J Appl Res Nat Prod* 2010; **3**(2): 22-27.
- 359 22. Iwalokun BA, Hodonu SA, Nwoke S, Ojo O, Agomo PU. Evaluation of the possible mechanisms of  
360 anti-hypertensive activity of *Loranthus micranthus*: African mistletoe. *Biochem Res Int* 2011; **11**: 1-9.
- 361 23. Ekundayo EO, Ekekwe JN. Antibacterial activity of leaf extracts of *Jatropha curcas* and *Euphorbia*  
362 *heterophylla*. *Afr J Microbiol Res* 2013; **7**(44): 5097-5100.
- 363 24. Oliveira AA, Segovia JFO, Sousa VYK, Mata ECG, Gonçalves MCA, Bezerra RM, Jumor POM,  
364 Kanzaki LIB. Anti-microbial activity of Amazonian medicinal plants. *Biomed Life Sci* 2013; **2**: 371-376.
- 365 25. Aladesanmi AJ, Iwalewa EO, Adebajo AC, Akinkunmi EO, TAIwo BJ, Olorunmola FO, Lamikanra A.  
366 Anti-microbial and anti-oxidant activities of some Nigerian medicinal plants. *Afr J Trad Comp Alt Med*  
367 2007; **4**(2): 173-184.
- 368 26. Raj A, Singh A, Sharma A, Singh N, Kumar P, Bhatia V. Antifertility activity of medicinal plants on  
369 reproductive system of female rat. *Int J Bio-Eng Sci Tech* 2011; **2**(3): 44-50.
- 370 27. Joshi SC, Sharma A, Chaturvedi M. Antifertility potential of some medicinal plants in males: An  
371 overview. *Int J Pharm Pharmaceut Sci* 2011; **3**(5): 204-217.
- 372 28. Akah PA. Abortifacient activity of some Nigerian medicinal plants. *Phytother Res* 1994; **8**(2): 106-108.
- 373 29. Sethi N, Nath D, Shukla Sc, Dyal R. Abortifacient activity of a medicinal plant '*Moringa olifera*' in rats.  
374 *Ancient Sci Life* 1988; **7**(3-4): 172-174.

- 375 30. Yakubu MT, Bukoye BB. Abortifacient potentials of the aqueous extract of *Bambusa vulgaris* leaves in  
376 pregnant Dutch rabbits. *Contraception* 2009; **80**(2009): 308-313.
- 377 31. Ayoka AO, Akomolafe RO, Iwalewa EO, Ukponmwan OE. Studies on the anxiolytic effect of *Spondias*  
378 *mombin* L (*Anacardiaceae*) extracts. *Afr J Trad Compl Alt Med* 2005; **2**(2): 153-165.
- 379 32. Ajao AO, Shonukan O, Femi-Onadeko B. Anti-bacterial effect of aqueous and alcohol extracts of  
380 *Spondias mombin* and *Alchonea cordifolia*: two local antimicrobial remedies. *Int J Crude Drug Res*  
381 1985; **23**: 67-72.
- 382 33. Iweala EEJ, Oludare FD. Hypoglycaemic effect, biochemical and histological changes of *Spondias*  
383 *mombin* and *Parinari polyandra* Benth Seeds ethanolic extracts in alloxan induced diabetic rats. *J*  
384 *Pharm Toxicol* 2011; **6** 2): 101-112.
- 385 34. Uchendu CN, ISek T. Antifertility activity of aqueous ethanolic extract of *Spondias mombin*  
386 (*Anacardiaceae*) in rats. *Afr Health Sci* 2008; **8**(3): 163-167.
- 387 35. Abo KA, Ogunleye VO, Asindi JS. Antimicrobial potential of *Spondias mombin*, *Croton zambesicus*  
388 and *Zygotritonia crocea*. *Phytother Res* 1999; **13**: 494-497.
- 389 36. Corthout J, Pieters LA, Claeys M, Vanden-Berghe DA, Viletinck AJ. Antibacterial and molluscicidal  
390 phenolic acid from *Spondias mombin*. *Planta Med* 1994; **60**: 460-463.
- 391 37. Goncalves JL, Lopez RC, Oliviera DB, Costa SS, Miranda MM, Romanos MT, Santos NS, Wigg MD.  
392 In vitro anti- rotavirus activity of some medicinal plants used in Brazil against diarrhea. *J*  
393 *Ethnopharmacol* 2005; **99**(3): 403-407.
- 394 38. Asuquo OR, Udonwa UN, Eluwa MA, Ekanem TB. Effects of *Spondias mombin* leaf extract on the  
395 cytoarchitecture of the cerebral cortex and on learning and memory in Wistar rats. *Int J Sci Res* 2013;  
396 **2**(9): 5-8.
- 397 39. Asuquo OR, Ekanem TB, Udoh PB, Mesembe OE, Ebong PE. Haematinic potential of *Spondias*  
398 *mombin* leaf extract in Wistar rats. *Adv Biores* 2013; **4**(2): 53-56.
- 399 40. Asuquo OR, Fischer CE, Mesembe OE, Igiri AO, Ekom IJ. Comparative study of aqueous and  
400 ethanolic leaf extracts of *Spondias mombin* on neurobehaviour in male rats. *IOSR J Pharm Biol Scis*  
401 2013; **5**(2): 29-35.
- 402 41. Slidders W. The OFG and BrAB-OFG methods for staining the adenohypophysis. *J Path Bacteriol* 1961;  
403 **82**: 532-534.
- 404 42. Bailey SA, Zidell RH, Perry RW. Relationship between organ weight and body/brain weight in the rat:  
405 what is the best analytical endpoint? *Toxicol pathol* 2004; **32**: 448-466.
- 406 43. Asuquo OR, Ekanem TB, Eluwa MA, Oko OO, Ikpi DE. Evaluation of toxicological effects of *Spondias*  
407 *mombin* in adult male Wistar rats. *J Nat Sci Res* 2012; **2**(7): 144-151.
- 408 44. Hurtuk BL, Krefetz RG. Enzymes: In Bishop MC, Duben-Engel Kirk, JL & Fody EP (Eds). Clinical  
409 chemistry, principles, procedures and correlations (2<sup>nd</sup> ed). Philadelphia, JB Lippincott Company, 1992;  
410 PP 215-233.
- 411 45. Akpanabiatu MI, Umoh IB, Eyong EU, Udoh FV. Influence of *Nauclea latifolia* leaf extracts on some  
412 hepatic enzymes of rats fed on coconut oil and non-coconut oil meals. *Pharm Biol* 2005; **43**(2): 153-  
413 157.

- 414  
415  
416
46. Johnson DF, Fody EP. Liver function: In Bishop MC, Duben-Engel Kirk, JL & Fody EP (Eds). Clinical chemistry, principles, procedures and correlations (2<sup>nd</sup> ed). Philadelphia, JB Lippincott Company, 1992; PP 473-478.
- 417  
418
47. Sharma A, Mathur R, Skukla S. Hepatoprotective action of a proprietary herbal preparation against carbon tetrachloride intoxication. *Indian Drugs* 1995; **32**: 120-124.
- 419  
420
48. Ahmed M, Saeed MA, Alam H, Ashgar Z. Biological studies of indigenous medicinal plants II: Effects of *Aplotaxis lappa* Dcne on various parameters of liver metabolism in rabbits. *J. Isl Acad Sci*, **5**, 51-56.
- 421  
422
49. Zilva JF, Panmall PR, Mayne PD. Clinical chemistry in diagnosis and treatment. 5<sup>th</sup> Ed, England; Clays Ltd, St Ives Plc., England.
- 423  
424
50. Asuquo OR, Ekanem TB, Udoh PB, Eluwa MA, Mesembe OE. Antigonadotrophic effect of *Spondias mombin* extract in adult male Wistar rats. *J Biol Agric Healthcare* 2012; **2**(7): 14-17.
- 425  
426
51. Kumara M, Singh P. Study of the reproductive organs and fertility of the male mice following administration of metronidazole. *Int J Fert Sterl* 2013; **7**(3): 225-238.
- 427  
428
52. Desjardins C. Endocrine regulation of reproductive development and function in the male. *J Ani Sci* 1978; **47**: 56-79.
- 429  
430  
431  
432