

Effect of *Annona muricata* Leaves Extract on Colon Antioxidant Status and Ketone Bodies in Blood and Urine of Cycas-Treated Rats

*** C. N. IKENNA-OSSAI¹, E. D. AVAN^{1,2}, C.C. EJIOFOR³, F. O OBI¹, and N.P. OKOLIE¹**

¹*Department of Biochemistry, Faculty of Life Science, University of Benin, Benin city, Edo state*

²*Department of Biomedical Engineering, College of Medicine, University of Lagos, Lagos state*

³*Department of Medical Biochemistry, College of Medicine, University of Nigeria, Enugu Campus.*

**Corresponding Author Email: chinenyeneby@yahoo.com*

Authors' contributions

This work was carried out in collaboration between all authors. Authors CNIO and EDA, designed the study, and performed the laboratory and statistical analysis. Authors CCE and CNIO wrote the first draft of the manuscript. Authors FOB and NPO, supervised the entire work, and interpreted the results. All authors read and approved the final manuscript

ABSTRACT

The effect of *Annona muricata* methanol leaf extract (AMELE) on colon antioxidant status and ketone bodies in blood and urine of cycas treated rats was investigated. Seventy male Wistar albino rats were randomly assigned into seven groups of ten experimental animals in a study that lasted for twenty-eight days. After 28 days, using standard methods, serum and urinary ketone bodies were assayed. Malondialdehyde (MDA), **antioxidants enzymes in the colon and histopathological analysis were assayed.** The results showed ketogenic diet had significant ($p < 0.05$) increase in serum and urinary ketone body levels compared to other groups on normal feed. *Annona muricata* extract enhanced cellular consumption and uptake of ketone bodies whereas cycas reduced cellular consumption of ketone bodies. *Annona muricata* given either with ketogenic diet or cycas or with both ketogenic diet and cycas led to higher tissue levels of antioxidant enzymes. Tissue MDA levels were significantly ($p < 0.05$) increased in all cycas treated groups compared to the control group with the highest levels seen in the two groups placed on normal feed and cycas. Lactate dehydrogenase activities were significantly ($p < 0.05$) increases in all the groups placed on ketogenic diet compared to

the groups placed on normal feed. Histopathological analysis revealed normal rat colon tissues in all the groups except 43% of the group 2 animals. This therefore indicates that cycas- induced oxidative stress and tissue injury may be mitigated by the combined administration of *Annona muricata* extract and ketogenic diet.

KEYWORDS: *Annona muricata*, cycas, colon, ketogenic diets, lipid peroxidation, antioxidant, histopathology.

INTRODUCTION:

Incidence of cancer increase at exponential rates due to its nature and numerous factors associated with its development. Cancer remains one of the most dreaded diseases causing an astonishingly high death rate, second only to cardiac arrest (Shaffi *et al.*, 2009). Although overall cancer incidence rates in the developing world is half those seen in the developed world in both sexes, the overall cancer mortality rates are generally similar (Jemal *et al.*, 2011). Cancer survival tends to be poorer in developing countries like Nigeria, most likely because of a combination of a late stage diagnosis and limited access to timely and standard treatment. The fact that conventional and newly emerging **treatment such** as chemotherapy, catalytic therapy, photodynamic therapy and radiotherapy have not succeeded in reverting the outcome of the disease to any drastic extent, has made researchers to investigate alternative treatment options (Jemal *et al.*, 2011).

Over the last few decades there are accumulating evidence about the metabolic reorganisation during cancer development which has been obtained from studies on various **tumour** (Poff *et al.*, 2014). Cancer cells require unrestricted energy generation to sustain their characteristic uncontrolled proliferation (Warburg, 1956). The growth of a normal mammalian cell depends on

growth factor **signalling** and nutrient availability (Cantor and Sabatini, 2012; Dang, 2012). In certain cell models, resting cells use fatty acid oxidation to generate ATP, maintain membrane potentials, and turn over organelles (Wang *et al.*, 2011). As the cell is induced to grow, glycolysis and glutaminolysis are induced through increased expression of glucose and amino acid transporters (Vander Heiden, 2011; Cantor and Sabatini, 2012; Dang 2012).

Most proliferating cells metabolize glucose by aerobic glycolysis rather than through the more energetically efficient oxidative phosphorylation used by normal resting cells in the presence of oxygen. It has been noted that under high conditions of high glucose uptake, the flux of glycolytic intermediates into branching biosynthetic pathways could be substantially increased. The dependence on glycolysis for energy production provides additional advantages to the **tumour** and this includes adaptation to a low oxygen environment as well as the acidification of the surrounding microenvironment. This promotes **tumour** invasion and suppresses immune surveillance (Luo *et al.*, 2009).

Targeting cancer cell metabolism through glycolytic inhibition has thus emerged as a new and promising strategy to fight cancer (Seyfried, *et al*, 2003). It has been reported that ketone bodies have deleterious effects on some cancer cells (Seyfried, 2012). **As a result, the use of ketogenic diet as an** alternative or complementary approach to the current standard cares for cancer management. Carbohydrate low ketogenic diet has been demonstrated to inhibit disease progression and promote partial remission in patients with advanced metastatic cancer from various tissue origins (Freeman *et al.*, 2007; Maurer *et al.*, 2011; Seyfried *et al* .,2003). On the other hand, natural products have also been targets for cancer therapy for several years. Medicinal plants are considered to be the main sources of biologically active compounds that can be used for the treatment of various ailments including cancer. One of such plants is *Annona*

muricata (commonly known as soursop) which contains a novel set of phytochemicals called “annonaceous acetogenins” which have been demonstrated to exhibit remarkable cytotoxic potential against cancer cell lines (Morre *et al.*,1994; Zeng *et al.*,1996). It has an edible fruit usually called soursop due to its slightly acidic taste when ripe. *Annona muricata* is a small, upright, evergreen tree that can grow to about 4m (13 feet) tall. Its young branches are hairy. The fruits are dark green and prickly, ovoid and can be up to 30cm (12 inches) long, with a moderately firm texture. Their flesh is juicy, acidic, whitish and aromatic. Phytochemical screening of the plants showed the presence of alkaloids, carbohydrates, coumarins, flavonoids, glycosides, phenolic compounds, phytosterols, proteins, quinones, saponins, steroids and terpenoids (Vijayameena *et al.*, 2013). Working on the anti-carcinogenic properties of *Annona muricata*, Maria *et al.*, showed that the extracts induced necrosis of pancreatic cancer cells by inhibiting cellular metabolism (Maria *et al.*,2012). Several pharmacological activities and medicinal applications of *Annona muricata* have been widely reported (Adeyemi *et al.*, 2009; Adeyemi *et al.*, 2010; Padmaa *et al.*,1999; Orlando *et al.*,2010; Maria *et al.*,2012). However, their mechanisms of action has not been fully elucidated beyond the fact that they inhibit the reduced form of NADH oxidase in the plasma membrane of cancer cells as well as complex 1 in the electron transport chain thereby starving the cancer cells of ATP (Nakanishi *et al.*, 2011).

The carcinogen used in this study was the *Cycas circinalis* plant, otherwise called the Queen Sago. This plant contains alkaloids of carcinogens and also amino acids that cause chronic nervous disorders. Regular consumption of the plant leads to severe health problems and death. In 1941, Lorenzo and Stewart first reported the carcinogenic activity of hydrazine, the hydrazine source being cycad flour. When large quantities of cycad flour were fed to rats, colon adenocarcinomas arose in some of the animals. The carcinogen in cycad flour was subsequently

found to be cycasin, a form of methyl azoxymethanol (MAM) (Laqueur, 1964). The carcinogen 1,2-dimethylhydrazine (DMH) which is metabolized to MAM in the liver was found to induce cancer in inbred rats. The location of the tumour was mainly in the distal portion of the colon which mimics the distribution seen in some forms of colorectal cancer (Druckery and Preussmann, 1967). In 1990, the carcinogenic activity of cycad was also reported when experimental animals placed on a diet composed of 5% cycad flour developed colon cancer. Recently Okolie *et al*; 2013 reported the carcinogenic property of cycas after observing the induction of colon carcinogenesis on experimental rats placed on a diet composed of 5% cycas.

Thus, this present study was aimed at examining the mechanism of action of *Annona muricata* in relation to ketogenesis in cycas induced colon carcinogenesis in rats

MATERIALS AND METHODS

Sample Collection and Preparation Large quantities of fresh green leaves of *Annona muricata* were collected from trees in household gardens in Benin City, Edo State, Nigeria. Fresh leaves of *Annona muricata* were rinsed with tap water and dried at room temperature for 4 weeks. The dried leaves were pulverized into fine coarse powder (1.5kg) and soaked in 2.6L of methanol for 72hours with regular stirring. The extract filtered and concentrated under reduced pressure.

Fresh cycas leaflets were collected at the Ugbowo campus of the University of Benin, Benin City, Nigeria. Fresh leaves of *Cycas circinalis* were dried at room temperature and subsequently pulverised as above. The powdered leaf (2 kg) was kept in an air- tight glass jar until used.

Table 1: Composition of the ketogenic diet used in this study

DIETARY COMPONENTS	AMOUNT(g/100g) (Low Carbohydrate /High Fat Diet)
Carbohydrate (Garri)	64.0
Protein (Casein)	16.0
Mineral and vitamin Mix	1.0
Saturated Fat (Palm oil)	20.0
Methionine	0.6

The oil used in this study was obtained from the Nigerian Institute for Oil Palm Research (NIFOR) Benin, BeninCity, Nigeria.

The Garri (yellow in colour) was obtained from an open air market in Benin City, Nigeria.

Experiment Animals:

A total of 70 Wistar male rats weighing 150 to 200g were used for this study. The rats were acclimatized for two weeks before the commencement of treatment. The rats were maintained with tap water and fed (Growers Mash Bendel Feeds and Flour Mills Ltd, Ewu, Edo State). The rats were divided into 7 groups, each group consisting of 10 rats and treated for 28days as indicated below

Group I- Rats served as control.

Group II- Rats + 5% (w/w) Cycas based diet.

Group III- Rats + 5% (w/w) Cycas based diet + ketogenic diet

Group IV- Rats + AMME (100mg/kg body wt)

Group V- Rats + ketogenic diet + AMME (100mg/kg body wt)

Group VI- Rats + 5% (w/w) Cycas + AMME (100mg/kg body wt)

Group VII- Rats + 5% (w/w) Cycas + ketogenic diet + AMME (100mg/kg body wt)

Administration of *Cycas circinalis*

To 100g of the rat feed, 0.5g of the powdered cycas leaf was added and orally administered to the rats for 28 days.

Administration of Extracts

The prescribed doses of plant extracts were orally administered to the rats daily, for 28, each animal was weighed. To each rat, 100mg/kg body weight of this extract solution was administered. The injection dose for each animal according to their weight was determined by the following equation:

$$\text{Calculated injection volume} = \frac{\text{Animals weight in kg} \times \text{dose (mg/kg)}}{\text{Concentration (mg/ml)}}$$

(typically measured in ("ml"))

Collection of Urine

At the end of the feeding experiment, which lasted for 28 days, metabolic cages were used for urine collection.

Collection of Blood

Blood samples were collected from the anesthetized rats by cardiac puncture. The samples were collected in plain bottles.

Preparation of Serum

The blood samples collected from the rats were allowed to coagulate at room temperature and centrifuged at 3500 rpm for 15mins at room temperature for separation of serum. The clear non-hemolysed supernatant was separated using dry pasture pipette and stored at -20⁰C. The serum was used for subsequent biochemical essays such as β-hydroxybutyrate, acetoacetate and lactate dehydrogenase assays.

Biochemical Assays

Beta- hydroxybutyrate was assayed using the method described by Williamson *et al.*, (1962) based on the oxidation of β -hydroxybutyrate to acetoacetate by the enzyme 3-hydroxybutyrate dehydrogenase by monitoring the reduction of NAD^+ to NADH at 450nm. The estimation of acetoacetate (AcAc) was carried out colorimetrically at 550nm as described by Stadtman *et al.*, (1951). LDH was assayed spectrophotometrically using Randox kits, by monitoring NAD^+ reduction at 340nm as described by Klin *et al.*, (1972). Catalase assay was as described by Cohen *et al.*, in which the rate of decomposition of hydrogen peroxide is monitored at 480nm. SOD was assayed by following auto-oxidation of adrenaline at 420nm (Misra and Fridovich, 1972). Glutathione peroxidase activity was determined by measuring the production of purpurogallen from pyrogallol at 420nm (Nyman,1959). MDA levels were measured using colorimetric reaction with thiobarbituric acid as described by Tietz, 1986. Reduced glutathione assay was done using the method as described by Tietz, 1976, in which 5,5dithiobis (2-nitrobenzoic acid) (DTNB) with reduced glutathione (GSH) was decomposed to hydrogen peroxide and was monitored at 480nm.

Preparation of Colon Tissue Homogenates

Tissues of colon were homogenized respectively in ice cold normal saline (1:10 w/v) and centrifuged at 10,000 rpm, for 15 minutes. The supernatant was stored at 4⁰C for analysis of malondialdehyde and reduced glutathione levels, superoxide dismutase, catalase and glutathione peroxidase activities.

Histopathological studies

The colon tissue were fixed with 10% formal saline solution (3 to 5 days) and were later dehydrated by passing through varying (increasing) concentrations of alcohol, cleared in benzene and further embedded in molten paraffin. Five micron (5µm) cryostat sections were stained with haematoxylin and eosin dyes. The sections were examined under light microscope at high power magnifications and photomicrographs taken.

RESULTS AND DISCUSSION

Results from Table 2 shows that there is results show a significant increase ($p<0.05$) in serum Ketone body profiles in the groups placed on Ketogenic diet compared to the groups placed on normal diet (Table 1). β -hydroxybutyrate levels are noticeably higher than acetoacetate levels in the serum as shown below.

Table 2: Serum β -hydroxybutyrate and acetoacetate levels of the rats after 28 days of treatment.

	Serum β -hydroxybutyrate (ng/ μ l)	Serum acetoacetate (ng/ μ l)
Group1	172.66 \pm 0.70 ^a	4.27 \pm 0.60 ^a
Group2	175.93 \pm 1.00 ^{ab}	4.34 \pm 0.50 ^{ab}
Group3	198.98 \pm 1.00 ^c	8.63 \pm 0.60 ^{ch}
Group4	170.87 \pm 0.90 ^{ac}	4.55 \pm 0.60 ^{ad}
Group5	177.27 \pm 1.00 ^{ad}	7.77 \pm 1.00 ^e
Group6	170.58 \pm 1.00 ^{ae}	4.18 \pm 0.70 ^{af}
Group7	203.89 \pm 0.40 ^e	8.30 \pm 0.90 ^{gh}
One way ANOVA (p-value)	0.113	0.000

Values are represented as mean \pm SEM (n=6). Means with different superscripts down the column are significantly different ($p<0.05$) at 95% confidence interval using paired sample students t-test

The results in Table 3 shows a significant increase ($p < 0.05$) in serum Ketone body profiles in the groups placed on Ketogenic diet compared to the groups placed on normal diet. Acetoacetate levels are noticeably higher than β -hydroxybutyrate in the Urine as shown below.

Table 3: Urine β -hydroxybutyrate and acetoacetate levels of the rats after 28 days of treatment.

	Urine β -hydroxybutyrate (ng/ μ l)	Urine acetoacetate (ng/ μ l)
Group1	1.67 \pm 0.00 ^a	23.20 \pm 0.00 ^a
Group2	2.70 \pm 0.00 ^b	30.00 \pm 0.00 ^b
Group3	4.00 \pm 0.00 ^c	70.70 \pm 0.00 ^c
Group4	1.60 \pm 0.00 ^a	33.70 \pm 0.00 ^d
Group5	5.70 \pm 0.00 ^d	83.50 \pm 0.00 ^e
Group6	0.90 \pm 0.00 ^e	26.50 \pm 0.00 ^f
Group7	2.70 \pm 0.00 ^f	84.20 \pm 0.00 ^g
One way ANOVA (p-value)	0.000	0.000

Values are represented as mean \pm SEM (n=6). Means with different superscripts down the column are significantly different ($p < 0.05$) at 95% confidence interval using paired sample students' t-test..

The results as seen in Table 4 below, show a significant increase in colon tissue Superoxide dismutase, Glutathione peroxidase and catalase activities in all the Ketogenic diet/ *Annona muricata* treated groups compared to the Normal diet/ *Annona muricata* treated groups.

Table 4: Colorectal tissue antioxidant enzyme activities and reduced glutathione levels of rats after 28days of treatment.

	Tissue reduced glutathione (mmole/mg)	Tissue Superoxide dismutase (U/mg) 10^{-3}	Tissue Catalase (U/mg)	Tissue glutathione peroxidase (U/mg)
Group1	0.33 \pm 0.01 ^{ac}	0.21 \pm 0.03 ^{ac}	95.29 \pm 2.00 ^{ac}	0.33 \pm 0.01 ^{abg}
Group2	0.49 \pm 0.10 ^{bh}	0.12 \pm 0.03 ^b	91.43 \pm 0.80 ^b	0.3 \pm 0.06 ^b

Group3	0.40±0.07 ^c	0.30±0.07 ^{ch}	105.42±0.40 ^{ch}	0.43±0.07 ^{ch}
Group4	0.37±0.08 ^d	0.09±0.03 ^d	86.14±0.70 ^d	0.27±0.04 ^d
Group5	0.51±0.10 ^e	0.32±0.10 ^e	142.14±0.10 ^e	0.42±0.07 ^{eh}
Group6	0.69±0.10 ^{fhi}	0.12±0.04 ^{fhi}	162.14±0.40 ^f	0.51±0.09 ^f
Group7	0.56±0.10 ^{gi}	0.21±0.06 ^{gi}	84.57±2.00 ^{gh}	0.28±0.05 ^{bg}
One-way ANOVA (p-value)	0.492	0.058	0.089	0.099

Values are represented as mean ± SEM (n=6). Means with different superscripts are significantly different (p<0.05) at 95% confidence interval.

Results seen in Table 5 below show a significant increase in the malondialdehyde content in the cycas-treated groups placed on Ketogenic diet. The values of Lactate dehydrogenase activity was significantly higher in groups placed on Ketogenic diet (treated/untreated) compared to the groups placed on normal diet (treated/untreated).

Table 5: Colorectal tissue level of lipid peroxidation marker (MDA) and serum lactate dehydrogenase activity of rats after 28days of treatment.

	MDA (x 10⁻³ nmoles/ g of fresh wt).	Serum lactate dehydrogenase (IU/ml)
Group1	1.24±0.71 ^a	583.89±0.90 ^a
Group2	2.25±0.20 ^b	478.70±0.40 ^b
Group3	1.36±0.20 ^{ch}	1758.28±2.00 ^{ch}
Group4	1.21±0.20 ^d	518.17±0.20 ^{di}
Group5	1.72±0.05 ^e	1780.24±0.80 ^{eh}
Group6	1.97±0.40 ^f	519.99±0.50 ^{fi}
Group7	1.29±0.10 ^{gh}	741.61±0.80 ^g
One-way ANOVA (p-value)	0.000	0.000

Values are represented as mean±SEM (n=6). Means with different superscripts are significantly different (p<0.05) at 95% confidence interval down the column by paired sample students' t-test.

The histopathological results obtained from this study showed normal mucosal and muscular layers in all the groups placed on ketogenic diet, treated or untreated with cycas and or *Annona muricata* except the group placed on Normal diet treated with cycas only.

This can be seen in the Figures are arranged as below:

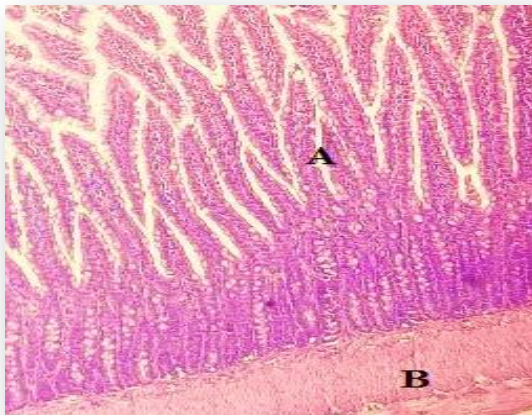


Figure 1: Longitudinal section of rat intestine from control group. Intact mucosal (A) and muscular (B) layers are evident. The mucosa is seen here as finger-like projections of its lamina propria covered by normal columnar epithelial cells and mucus-secreting goblet cells. The muscularis propria is the muscle layer very well delineated at the bottom of the micrograph, propping up the mucosa. (H and E; X 100).

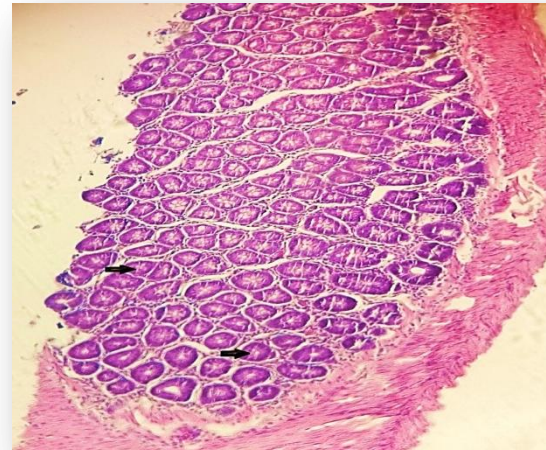


Figure 2: Transverse section of the colon from a control rat. Normal intestinal glands are evident in the mucosa, each being shown here as circular (tubular) structures (arrows) lined by mucus-secreting columnar epithelial cells. The underlying smooth muscle layer (muscularis propria) is also shown (H and E; X 100).

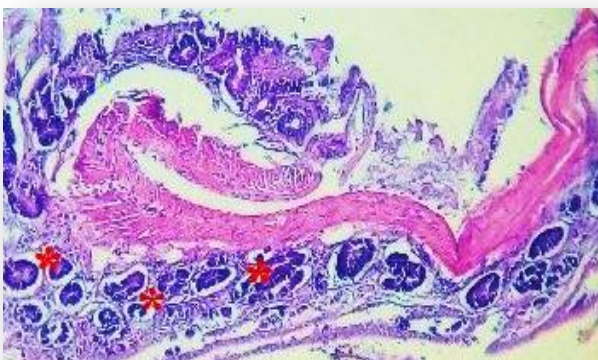

Figure 3: Section of the colon from a rat treated with Cycas only. (H & E; x 100). Intestinal glandular epithelial dysplasia (pre-cancerous change) is evident across the glands of the mucosa (red asterisks), the epithelial lining cells of which obviously exhibit nuclear enlargement, hyperchromasia and loss of mucin secretion. These pre-cancerous changes were seen in only about 43% of the rats and the underlying smooth muscular layer is also shown.

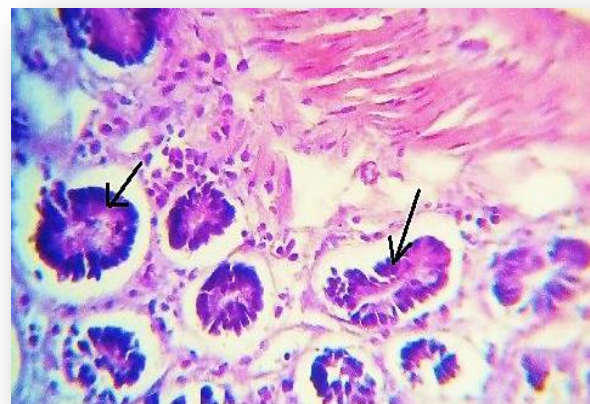

Figure 4: Section of the colonic mucosa from a Cycas-only treated rat (Hand E; x 100). Glands (arrows) lined by dysplastic epithelial cells with nuclear disarray, enlargement and hyperchromasia are evident. There is loss of mucin secretion and absence of goblet cells. These pre-cancerous changes were seen in only about 43% of the rats belonging to this group.

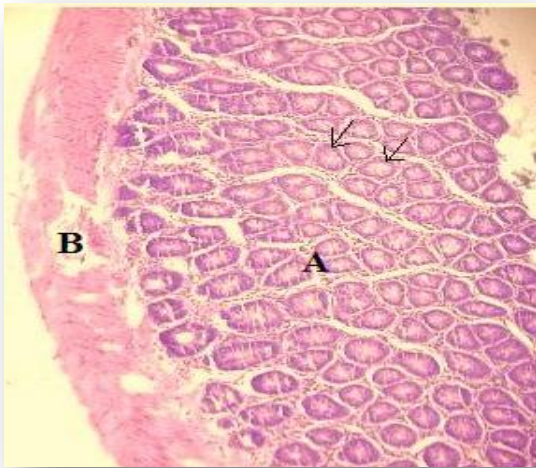


Figure 5: Section of the colon from a cycas-only treated rat (H&E; x100).The mucosa (A) contains numerous normal, transversely sectioned tubular glands (arrows) within its lamina propria. Each gland has a central lumen surrounded by columnar epithelial lining cells. The muscular (B) layer is also well shown.Such normal histology was seen in 57% of this group.

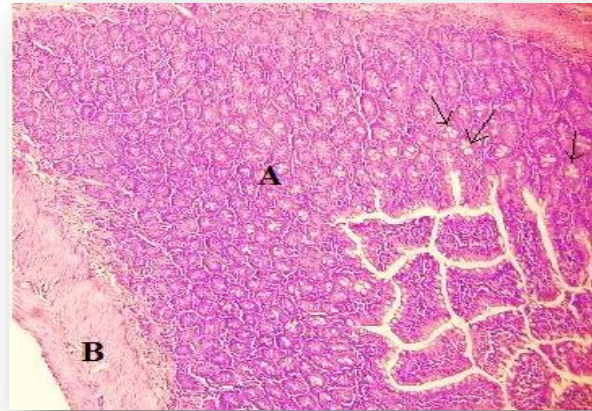


Figure 6: Section of the colon from a cycas and ketogenic diet treated rat (H&E; x100). A normal mucosa (A) with normal glands lined by columnar and goblet cells (arrows), a normal muscularis layer (B) and an inconspicuous layer of submucosa inbetween the mucosa and muscularis, are evident.

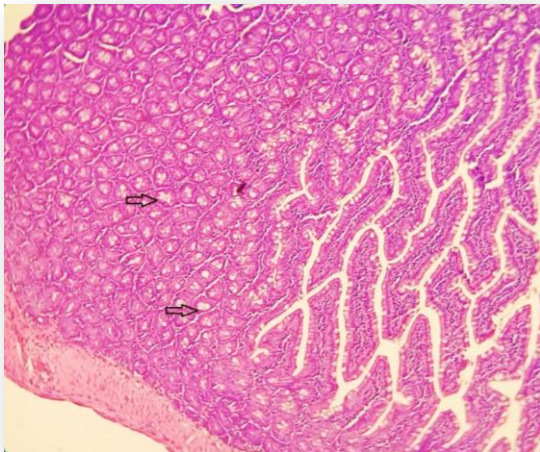


Figure 7: Section taken from an extract only treated rat (H& E; x100).Numerous normal mucous glands (arrows) lined by normal columnar epithelialand goblet cells are evident in this view. The right of the field shows the mucosa disposed as finger-like structures of lamina propria covered by columnar and goblet cells. A section of the muscular layer is seen at the bottom left.

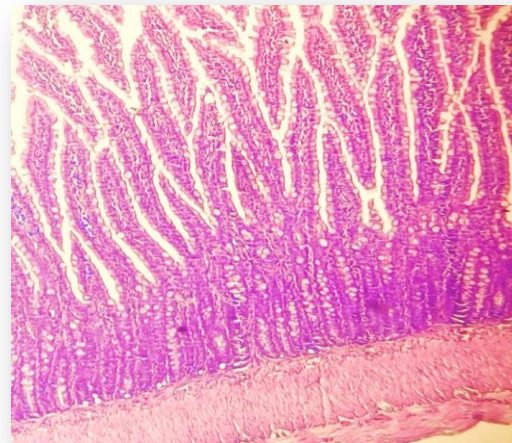


Figure 8: Section taken from a rat placed on ketogenic diet and extract (H&E: x100).Normal histology is evident. The mucosa above is displayed in numerous fingerlike projections of the lamina propria covered by columnar lining cells and mucin-secreting goblet cells. The muscularispropria props up the mucosa as shown at the bottom of the micrograph.

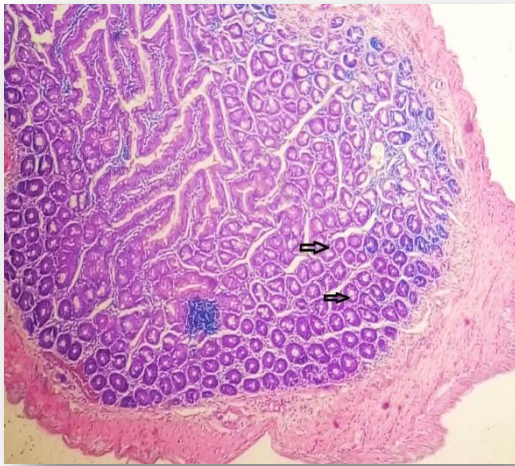


Figure 9: Section of colon from a cycas and extract treated rat (H&E; x100). The normal mucosa with normal glandular architecture (arrows) is shown here surrounded by the normal muscular layer.

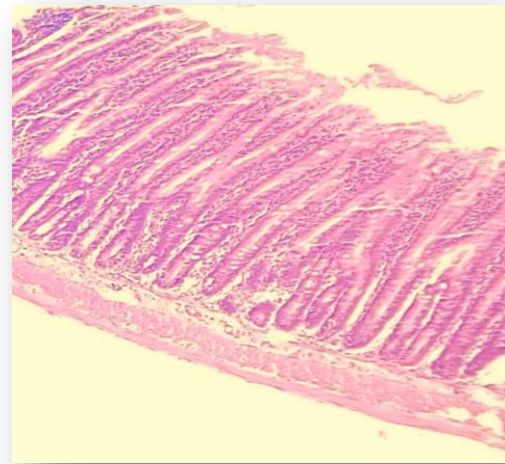


Figure 10: Section of colon from a cycas, extract and ketogenic diet treated rat (H&E; x100). Numerous straight, tubular glands are seen in this normal mucosa, and they are lined by normal columnar and goblet cells. A thin layer of submucosa separates the mucosa above from the muscularis propria beneath.

Cancer chemoprevention using antioxidant approaches has been a good potential in providing important fundamental benefits to public health and is now considered by many clinicians and researchers as a key strategy for inhibiting, delaying or even reversal of process of carcinogenesis (Ahmeida *et al.*, 2005). Moreover, knowledge and application of such potential activities in reducing oxidative stress *in vivo* has prompted the search for potent and cost effective antioxidants from various plant sources. It has been strongly suggested that colorectal carcinogenesis is associated with intense oxidative stress and the progression of the cancer is certain in the face of increased imbalance in the oxidative-antioxidative disorder (Skrzydłowska *et al.*, 2001).

The present study assays the tissue-protective effect of *Annona muricata* extract against histopathological damage in cycas –induced oxidative-stressed rats. Results from Table 1 shows the serum levels of β -hydroxybutyrate and acetoacetate levels of the rats after 28 days of treatment. Results from the show significant increase ($p<0.05$) in serum ketone body (β - hydroxybutyrate levels and acetoacetate) profiles of the groups placed on ketogenic diet (groups, III, V and VII) compared to the groups placed on normal diet (Table 1). Also, it could be noticed that rats fed with ketogenic diets (groups, III, V and VII) showed higher ketone bodies (β - hydroxybutyrate levels and acetoacetate). This is true because Ketogenic diet leads to the production of ketone bodies, such as β -hydroxybutyrate and acetoacetate, which can be used as an alternative energy source. Within the groups cycas treated groups, group VI has the lowest ketone body profile.

Results from Table 2 show a significant increase ($p<0.05$) in urinary ketone body profiles in the groups (III, V and V11) placed on ketogenic diet compared to the groups (I, II, IV and VI) placed on normal diet as shown in Table 2. Within the cycas treated groups (II, VI and VII), the untreated carcinogenic group (I) presented the lowest urinary ketone body. This reduced presence of urinary ketone body as a result of inability of the cancerous cells to efficiently process ketone bodies for energy. Ketones also slow the proliferation of tumor cells. This reduced ketone bodies in the urine is also evident in the reduced serum ketone body profile within the group as shown in Table1. Although ketone bodies are efficient energy substrates for healthy extrahepatic tissues, cancer cells cannot effectively use them for energy (Veech *et al.*, 2001). This increase in the ketone body of the rats treated with ketogenic diet corroborates with the results of a “classical” ketogenic diet described by Russell Wilder at the Mayo clinic (Wilder, 1921). Studies by Poff *et al.*, 2014 show that ketone supplementation elevated blood ketone

which is similar with the present study. Hence, from the present study, we can hypothesize that dietary administration of ketone body precursors would inhibit disease progression *in vivo*.

Among the measures that are utilized by cells to counteract the deleterious effects of lipid peroxidation is alteration of the activity of antioxidant enzymes such as catalase, peroxidases and superoxide dismutase (Bhor *et al.*, 2004). Catalase is an important cellular antioxidant enzyme that defends against oxidative stress found in the peroxisomes of most aerobic cells. It serves to protect the cell from toxic effects of high concentrations of hydrogen peroxide by catalyzing its decomposition into molecular oxygen and water (Shangari 2006). Thus, estimation of catalase activity is a good indicator of oxidative stress in experimental animals. Superoxide dismutase is a metalloenzyme that scavenges superoxide anions and exists as isoforms classified on the basis of their relative requirement for manganese, copper and zinc to maintain structural and functional integrity (Sasaki *et al.*, 2000). The results as seen in Table 3, shows a significant increase in colon tissue superoxide dismutase, glutathione peroxidase and catalase activities in all the ketogenic diet/*Annona muricata* treated groups compared to the normal diet/ *Annona muricata* treated groups.

The Anti-oxidant enzyme system is one of the inherent protective mechanisms in living organisms. *Annona muricata* has been reported to enhance anti-oxidative enzyme system in experimental animals. The observed synergistic relationship between *Annona muricata* and ketogenic diet in this study was also confirmed in the levels of anti-oxidant enzyme activity exhibited between group4 (normal diet/extract treated) and group5 (ketogenic diet/extract treated). In this study, there was a significant ($P < 0.05$) increase in antioxidant enzyme activity in group5 compared to group4. Some studies, however, reported that ketogenic diet, with high

fat, low carbohydrate diets can modulate the response of some antioxidant enzymes (Jodynis-Liebert and Murias, 2002; Dhuley *et al.*, 1999; Ruiz-Gutierrez *et al.*, 1999).

The animals in group 2 (normal diet, cycas treated), however showed lower levels of antioxidant activity compared to control rats but they showed higher levels of reduced glutathione compared to control rats. This is not uncommon as oxidative stress can cause the up-regulation of antioxidant enzymes and increase in reduced glutathione levels that render cells more resistant to subsequent oxidative insult (Halliwell, 2000). Over-expression of glutathione has been reported in both animal and human tumors (Yang *et al.*, 1997; Skrzydlewska *et al.*, 2001; Balasenthil., 2000).

Results of the antioxidants levels of the rats in the present study shows (Table 3) that only the *Annona muricata* extract (group IV) presented the lowest antioxidant levels. This was similar to the levels shown by the normal rats (group I), indicating that *Annona muricata* did not in any way cause oxidative damage. Ketogenic diet has been reported to stimulate the cellular endogenous antioxidant system with the activation of nuclear factor erythroid-derived 2 (NF-E2)-related factor 2 (Nrf2), the major inducer of detoxification genes (Pinto, *et al.*, 2018). This could probably be the same reason why the groups treated with ketogenic diets presented higher antioxidant levels.

Results seen in Table 4 above show a significant increase in the malondialdehyde content in the cycas-treated groups placed on ketogenic diet. The values of lactate dehydrogenase activity was significantly higher in groups placed on ketogenic diet (treated/untreated) compared to the groups placed on normal diet (treated/untreated).

Members of the *Cycas* family have been shown to contain cycasin which has the ability to cause the formation of agents like azoxymethane which have free radical activity (Rosenberg *et al.*,

2009). This may account for the elevated amount of malondialdehyde-an index of lipid peroxidation in the experimental animals exposed to cycas only compared with the controls. Lipid peroxidation is a well-established mechanism of cellular injury and therefore used as an indicator of oxidative stress which is characterised by an increase in malondialdehyde concentration (MDA). In this study, the concentration of MDA was markedly increased in the cycas-treated group which is significantly different ($p<0.05$) from the control group and the other groups. This is similar to the findings of Okolie *et al.*, (2013); Lolodi and Eriyamremu, (2013); Eriyamremu *et al.*, (2007) in which an increase in MDA concentration after cycas administration was reported. The result of the lipid peroxidation assay therefore shows the oxidative stress effect caused by cycas administration. Within the cycas groups (II, III, VI and VIII) treated, group VII presented the lowest MDA level thereby suggesting a possible synergistic effect of both extracts.

Histological results showed that colon sections of cycas only treated rats (Group II) showed evidence of pre-cancerous changes when compared to the untreated controls shown in Figures 3 and 4. Section of the colon from a rat treated with cycas only showed that there was evident intestinal glandular epithelial dysplasia (pre-cancerous change) across the glands of the mucosa. The epithelial lining cells of which obviously exhibit nuclear enlargement, hyperchromasia and loss of mucin secretion. Sections from rats from other groups presented normal morphological appearance. As shown in the Figures, as treatment was introduced; the tissue (Groups VI, and VII) sections were evidently restored to normal. It seems *Annona muricata* has tissue-protective effect which can be observed by its ability to restore and reverse the damaged tissues. Similar effects were reported by earlier studies on *Annona muricata*. Working on the evaluation of anticancer activity of *annona muricata* in 1, 2-dimethyl hydrazine induced colon cancer,

Venkateshwarlu *et al.*, (2014) reported that the ethanol extract of *Annona muricata* it has shows potent anti cancer activity. This was also similar to reports presented by Moghadamtousi *et al* in 2014. Using HCT-116 and HT-29 cells and MTT and LDH assays, it has been shown that cells treated by ethanol extracts of *A. muricata* arrested in G1 cell cycle phase and induced to apoptosis cascade. Ethanol extracts of *A. muricata* treatment caused excessive accumulation of ROS followed by disruption of MMP, cytochrome c leakage and activation of the initiator and executioner c as passes in both colon cancer cells (Moghadamtousi *et al.*, 2014a). It's also reported that ethyl acetate extract of *A. muricata* inhibited the proliferation of A549 cells, leading to cell cycle arrest and programmed cell death through activation of the mitochondrial-mediated signalling pathway with the involvement of the NF- κ B signalling pathway (Moghadamtousi *et al.*, 2014b).

The anti-proliferative activity of *A. muricata* extract had been also reported elsewhere. A comprehensive study showed that potentially strong antiproliferation and apoptosis was achieved through disruption of MMP (Membrane mitochondrial potential), reactive oxygen species (ROS) generation and G0/G1 phase cell mitigate Human promyelocytic leukemia (HL-60 cells) cell culture (Pieme *et al.*, 2014). Reports also showed that treatment with *Annona muricata* improved the histological changes of breast tissue and reduced the proliferative indexes of their cells (Sulistyoningrum *et al.* 2017). This was in line with previous *in vitro* studies; the leaves of soursop had *in vitro* anticancer activity on T47D cell lines (Rachmani *et al.*, 2012), human adenocarcinoma cell MCF-7 (Ko *et al.*, 2011), human carcinoma cell (MDA-MB-435S) or human immortal keratino cytes (HaCaT) (George *et al.*, 2012).

The chemo preventive effects of *Annona muricata* might be attributed to the presence of a class of compound obtained from Annona species, acetogenins. It has been reported that the main anti-

tumorous compound, annonacin was effective against *in vitro* cancer cell lines as well as *in vivo* lung cancer (Venkateshwarlu *et al* 2014).

CONCLUSIONS

This study reveals that *Annona muricata* increased cellular uptake consumption of ketone bodies while *Cycas circinalis* appeared to have the opposite effect. This property exhibited by *Annona muricata* could be exploited as a therapeutic tool in the management and treatment of cancer.

However, further studies are needed to fully understand this anticancer activity of *Annona muricata*. The anti-oxidative properties of *Annona muricata* were evident in this study. Ketogenic diet and *Annona muricata* protected the cells from structural damage and they exerted even more protection on these experimental animals.

Consent : NA

Ethical : As per international standard informed written ethical approval has been collected and preserved by the author(s).

REFERENCES

- Adeyemi, D.O., Komolafe, O.A., Adewole, O.S., Obuotor, E.M. and Ademowo, T.H. (2009). Anti-hyperglycemic activities of *Annona muricata* (Linn). *Afr. J. Trad. CAM.* 6(1): 62-69.
- Adeyemi, D.O., Komolafe, O.A., Adewole, O.S., Obuotor, E.M., Abiodun, A.A. and Adenowo, T.K. (2010). Histomorphological and morphometric studies of the pancreatic islet cells of diabetic rats treated with extracts of *Annona muricata*. *Folia. Morphol. (Warsz).* 69(2): 92-100.

- Almeida, V. L., Leitão, A., Reina, L. C. B., Montanari, C. A., Donnici, C. L., and Lopes, M. T. P. (2005). Cancer and cell cycle-specific and cell cycle nonspecific anticancer DNA-interactive agents: an introduction; *Química Nova*, 28(1), 118-129. <https://dx.doi.org/10.1590/S0100-40422005000100021>
- Balasantil, S., Saroja, M., Ramachandran, C. R. and Nagini, S. (2000). Of Humans and hamsters: Comparative analysis of lipid peroxidation glutathione and glutathione-dependent enzymes during oral carcinogenesis. *Er. J. Oral. Maxillofac.Surg.*38:267-70.
- Bhor, V.M., Raghuram, N and S. Sivakami, S. (2004). Oxidative damage and altered antioxidant enzyme activities in the small intestine of streptozotocin-induced diabetic rats. *Int. J. Biochem. Cell. Biol.*, 36: 89-97.
- Cantor, J.R. and Sabatini, D.M. (2012). Cancer cell metabolism: One hallmark, many faces. *Cancer. Discov.* 2:881-898.
- Dang, C.V. (2012). Links between metabolism and cancer. *Genes. Dev.* 26:877-890.
- Dhuley, J. N. (1999). Anti-oxidant effects of cinnamon *Cinna-momumverum* bark and greater Cardamon *Amomum Subulatum* seeds in rats fed high Fat diet. *Ind. J .Exp. Biol.* 37:238-42.
- Druckrey, H., Preussmann, R. and Matzkies, F. (1976). Selective production of intestinal cancer in rats by 1, 2 – Dimethylhydrazine. *Natur wissens chaften*54:285-286.
- Eriyamremu, G.E., Asagba, S.O. Uanseoje, S.O. Omeregie, S.E. and Omofoma, C.O (2007). Colonic lipid peroxidation, nuclear membrane ATPase and stress enzymes in rats fed a Nigerian-like diet and cycas. *J. Boil. Sci.*, 7: 526-531.

- Freeman, J. M., Kossoff, E. H. and Hartman, A. L. (2007). The ketogenic diet: One decade later. *Pediatrics*, 119(3):535-43.
- George, V.C., Kumar, D.R.N., Rajkumar, V., Suresh, P.K., Kumar, R. A. (2012) Quantitative assessment of the relative antineoplastic potential of the n-butanolic leaf extract of *Annona muricata* Linn. in normal and immortalized human cell lines. *Asian Pacific J Cancer Prev*, ;13 (2): 699-704.
- Halliwell, B. (2000). The antioxidant paradox. *Lancet*.355:1179-80.
- Jermal, A., Bray, F., Center, M.M., Ferlay, J., Ward, E. and Forman, D. (2011). “Global cancer statistics”. *Cancer Journal for Clinicians*.61(2): 134.
- Jodynis-Liebert, J. and Murias, M.() Modulation of antioxidant defence system by dietary fat in rats intoxicated with o-toluidine. *Hum Exp Toxicol*. 21(12):659-65.
- Klin, Z.(1972). Kinetic determination of lactate dehydrogenase as recommended by the German Clinical Chemistry Society (DGKC) Biochemistry. *Chem.Klin.Biochem*.I.8:658.
- Ko, Y.M., Wu, T.Y., Wu, Y.C., Chang, F.R., Guh, J.Y., Chuang, L.Y. (2011). Annonacin induces cell cycle-dependent growth arrest and apoptosis in estrogen receptor- α -related pathways in MCF-7 cells. *J Ethnopharmacol*, ; 137 (3):1283-1290.
- Laqueur, G. (1964). Carcinogenic effect of cycad meal and cycasin, methylazoxymethanol glycoside in rats and effects of cycasin in germ – free rats. *Fed. Proc*.23:1386-1387.
- Lolodi O. and Eriyamremu, G.E. (2013). Effect of methanolic extract of *Vernonia amygdalina* (common bitter leaf) on lipid peroxidation and antioxidant enzymes in Rrats exposed to cycasin. *Pakistan Journal of Biological Sciences*, 16: 642-646.

- Luo, J., Solimini, N. L. and Elledge, S.J. (2009). Principles of cancer therapy: Oncogene and non-oncogene addiction. *Cell*.136:823-837.
- Maria, P.T., Satyanarayana, R., Vinee, P., Poomy, P., Suhasini, J., Erik, D. M., Sonny, J., Pankaj, S., Apar, K.G. and Surinder. K.B. (2012). Graviola-novel promising nderived drug that inhibits tumorigenicity and metastasis of pancreatic cancer cell *in vitro* and *in vivo* through alternating cell metabolism. *Cancer Cell Letters*. 323: 29-40.
- Maurer, G. D. (2011). Differential ktilization of Ketone bodies by neurons and glioma cell lines: A rationale for ketogenic diet as experimental Gglioma therapy. *BMC Cancer*.11:315.
- Misra, H.P. and Fridovich, I.(1972). The role of superoxide ion in the anti-oxidation of epinephrine and a simple assay for superoxide dismutase. *J.Biol.Chem*.247:3170-3175.
- Moghadamtousi, S. Z., Kadir, H. A., Paydar, M., Rouhollahi, E. and Karimian, H., (2014a) *Annona muricata* leaves induced apoptosis in A549 cells through mitochondrial-Mmediated pathway and involvement of NF-XB. *BMC Complementary and Alternative Medicine*.14:299.
- Moghadamtousi, S.Z., Kadir, H.A., Paydar, M., Rouhollahi, E., Karimian, H. (2014b) *Annona muricata*leaves induced apoptosis in A549 cells through mitochondrial-mediated pathway and involvement of NF-κB. *BMC Complement Altern Med*, ; 14 (1): 1-13.
- Morré, D.J., de Cabo, R., Farley, C., Oberlies, N.H., McLaughlin, J.L.(1994) Mode of action of bullatacin, a potent antitumor acetogenin: inhibition of NADH oxidase activity of HeLa and HL-60, but not liver, plasma membranes. *Life Sci*. 1994;56(5):343–348.
- Nishisho, T., Hata, K., Nakanishi, M., Morita, Y., Sun-Wada, G., Wada, Y., Yasui, N., and Yoneda, T. (2011). The *a3* isoform vacuolar type H⁺-ATPase promotes distant

metastasis in the mouse B16 melanoma cells: *Mol Cancer Res* 9)(7) 845-855; DOI: 10.1158/15417786.MCR-10-0449

Nyman, M. (1959). Serum haptoglobin: methodological and clinical studies. *Scand .J .Clin.Lab Invest.* 11:39-39.

Okolie, N.O., Agu, K., Eze, G.I. (2013) .Protective effect of ethanolic leaf extract of *Annona muricata* Linn on some early events in cycas-induced colorectal carcinogenesis in rats. *JSPI.* 2(4)14-21.

Orlando, V., Glauciemar, D.V., Jose de Jesus, R.G.D., Celia, H.Y. and Maria, S.A. (2010). Antinociceptive and anti-inflammatory activities of the ethanol extract of *Annona muricata*. L. leaves in animal models. *Int. J. Mol. Sci.* 11: 2067-2078.

Padmaa, B.P., Chansouria, J.P.N. and Khosaa, R.L. (1999). Hepatoprotective activity of *Annona muricata* Linn and *Polyalthia cerasoide* *Ancient Science of Life.* 19:7-10.

Pieme, C. A., Santosh, G. K., Tekwu, E. M., Askun, T., Aydeniz, H., Ngogang, J. Y., and Saxena, A. K. (2014). Fruits and barks extracts of *Zanthozyllum heitzii* a spice from Cameroon induce mitochondrial dependent apoptosis and Go/G1 phase arrest in human leukemia HL-60 cells. *Biological research*, 47(1), 54. doi:10.1186/0717-6287-47-54

Pinto, A., Bonucci, A., Maggi, E., Corsi, M., and Businaro, R. (2018). Anti-oxidant and anti-inflammatory activity of ketogenic diet: New perspectives for neuroprotection in Alzheimer's disease. *Antioxidants (Basel, Switzerland)*, 7(5), 63. doi:10.3390/antiox7050063

Poff, A. M., Ari, C., Arnold, P., Seyfried, T. N. and D'Agostino, D. P. (2014). Ketone supplementation decreases tumor cell viability and prolongs survival of mice with metastatic cancer. *Int. J. Cancer.* 135:1711-1720.

- Rosenberg, D.W., Giardina, C. and Tanaka T. (2009). Mouse models for study of colon carcinogenesis. *Carcinogenesis*, 30: 183-196.
- Ruiz-Gutiérrez, V., Pérez-Espinosa, A., Vásquez, C. M. and Santamaria, C. (1999). Effects of dietary fat (fish, olive and high-oleic-acid sunflower oils) on lipid composition and antioxidant enzymes in rat liver. *Br. J. Nutr.* 82:233-41.
- Sasaki, H., Akamatsu, H. and . Horio, T. (2000). Protective role of copper, zinc superoxide dismutase against UVB-induced injury of the human keratinocyte cell line HaCaT. *J. Invest. Dermatol.*, 114: 502-507.
- Seyfried, T. N. (2012). Metabolic management of cancer as a metabolic disease; On the origin, management and prevention of cancer. John Wiley and Sons, Hoboken, NJ, pp. 291-354.
- Seyfried, T. N., Sanderson, T. M., El-Abbadi, M. M., McGowan, R. and Mukherjee, P. (2003). Role of glucose and ketone bodies in the metabolic control of experimental brain cancer. *Br. J. cancer.* 89:1375-1382.
- Shafi, G., Anjana, M., Hasan, T., Alshatwi, A., Tyothy, A., and Lei, D.K. (2009). Induction of apoptosis in the Hela cells by chloroform fraction of seed extracts of *Nigella sativa*., *Cancer Cell International*.9:29.
- Shangari, N., O'Brien, P.J. (2006). Catalase activity assays. *Current protocols in toxicology*.
- Skrzydłowska, E., Stankiewicz, A., Sulkowska, M., Sulkowski, S. and Kasacka, I. (2001). Antioxidant status and lipid peroxidation in colorectal cancer. *J. Toxicol .Environ. Health*.64:213-22.

- Sulistyoningrum, E., Rachmani, E.P.N., Baroroh, H.N., Rujito, L. (2017) *Annona muricata* leaves extract reduce proliferative indexes and improve histological changes in rat's breast Cancer. *J App PharmSci*, ; 7 (01): 149-155
- Tietz, N.W. (1976). *Fundamentals of clinical chemistry*, W.B., Saunders Co., Philadelphia,
- Vander Heiden, M.G. (2011). Targeting cancer metabolism. A therapeutic window opens. *National Rev. Drug. Discov.* 10:671-684.
- Veech, R. L., Chance, B., Kashiwaya, Y., Lardy, H.A. and Cahill, G. F. (2001). Ketone bodies, potential therapeutic uses. *IUBMB life*. 51(4): 241-247
- Venkateshwarlu E., Swathi G., Sharvana B. B. S., Shiva K. R., Venkateshwar R. J. and Umasankar K. (2014). Evaluation of anticancer activity of *Annona muricata* in 1, 2-dimethyl hydrazine induced colon cancer. *World Appl. Sci. J.* 32; 444-450
10.5829/idosi.wasj.2014.32.03.85109.
- Vijayameena, C., Subhashini, G., Loganayagi, M. and Ramesh, B. (2013). Phytochemical screening and assessment of antibacterial activity for the bioactive compounds in *Annona muricata*. *Int. J. Curr. Microbial.App.Sci.* 2(1): 1-8.
- Warburg, O. (1956). "On the origin of cancer cells". *Science*. 123 (3191): 309-314.
- Wilder, R. M. (1921). The effect on ketonemia on the course of epilepsy. *Mayo.Clin. Bull.* 2:307
- Williamson, D.H., Mellanby, J. and Krebs, H.A. (1962). Enzymatic determination of D (-) - β -hydroxybutyric acid and acetoacetic acid in blood. *Biochem. J.* 82:90-96.
- Yang, C. R., Ou, Y. C. and Kuo, J. H. (1997). Intracellular glutathione content of urothelial cancer in correlation to chemotherapy response. *Cancer. Lett.* 119:157-162.

Zeng, L., Wu, F. E., Oberlies, N. H., McLaughun, J. L., Sastrodihadjo. S. (1996). Five new monotetrahydrofuran ring acetogenins from the leaves of *Annona muricata*. *J .Nat. Prod.* 59(11): 1035-1042.